



Diagnostic Accuracy of Red Reflex Test (RRT) for Early Detection of Ocular Abnormalities in Newborn

Kshitij Aviraj Singh¹ and Amar Taksande^{1*}

¹Department of Paediatrics, Jawaharlal Nehru Medical College, Datta Meghe Institute of Medical Sciences, Sawangi Meghe, 442004, Wardha, Maharashtra, India.

Authors' contributions

This work was carried out in collaboration among all authors. Author AT designed the study, performed the statistical analysis, wrote the protocol, and wrote the first draft of the manuscript. Author KS managed the analyses of the study and the literature searches. All authors read and approved the final manuscript.

Article Information

DOI: 10.9734/JPRI/2021/v33i32B31761

Editor(s):

(1) Dr. Vasudevan Mani, Qassim University, Saudi Arabia.

Reviewers:

(1) Amar Verma, Rajendra Institute of Medical Sciences, India.

(2) Vidhya Shankari N, P. K. DAS Institute of Medical Sciences, Kerala University of Health Sciences (KUHS), India.

(3) Preeti lata Rai, Shri Ram Murti Smarak Institute Of Medical Sciences, India.

Complete Peer review History: <http://www.sdiarticle4.com/review-history/68581>

Study Protocol

Received 10 March 2021

Accepted 13 May 2021

Published 22 June 2021

ABSTRACT

Background: The Red Reflex is described as the red to orange reflection of light from the fundus of the eye, observed while using a retinoscope or an ophthalmoscope. Red Eye Reflex Test is determined by the optical media transparency which includes vitreous humor, aqueous humor, cornea and tear film and reflection of light from the back of the eye (fundus) through optical media and into the aperture of the ophthalmoscope. Factors that will block or impede the passage of light through this transparent media or affects its reflection back from fundus will produce an abnormal Red Eye Reflex. Red Eye Reflex (RER) testing is important & effective tool for early detection of ocular abnormalities such as retinal abnormalities, cataract, retinoblastoma and glaucoma. Red reflex is cost effective, can be performed very easily, requires minimal setting, can screen important ocular abnormalities and facilitate their early detection with prompt intervention to prevent long term sequelae associated with the disease.

Aim: To find out the diagnostic accuracy of Red Reflex test for diagnosing ocular abnormalities in newborns.

Methodology: Ours will be a prospective cross-sectional study where RER examination will be

performed within one week of birth of a newborn in a darkened and will correlate the examination findings with respect to ocular findings determined by ophthalmologist to determine its efficacy, sensitivity and specificity in detecting neonatal ocular abnormalities.

Expected results: After completion of the study we will be able to determine the accuracy of RRT for ocular abnormality detection in the neonates. We will be able to determine the sensitivity, specificity, PPV & NPV of the red reflex test. If the specificity and the sensitivity is good then we can use RRT as a routine screening method for detection of intraocular abnormalities.

Conclusion: To find the Red reflex Test efficacy in screening of the ocular abnormalities in the new born.

Keywords: Red reflex test; Neonates; congenital ocular abnormalities.

1. INTRODUCTION

World Health Organization's Global Vision 2020 initiative has considered congenital cataract as one of the common infantile cause of visual impairment which is treatable and thus prioritizes its early diagnosis and treatment. Among the developed countries, childhood blindness has its incidence at around 1–6 per 10,000 live births [1]. Common causes of preventable blindness among neonates includes Congenital cataract, High refractive error, Strabismus, Congenital glaucoma, retinal abnormalities like retinoblastomas, Retinopathy of prematurity and amblyopia . For all the ocular abnormalities, Red Eye Reflex test plays key screening tool for their early screening with high sensitivity as mentioned in previous studies conducted in developed countries [2-5]. The Red Reflex is described as the red to orange reflection of light from the fundus of the eye, observed while using a retinoscope or an ophthalmoscope. Red Eye Reflex Test is determined by optical media transparency which includes vitreous humor, aqueous humor, cornea, the tear film and reflection of light from the back of the eye (fundus) through optical media into the aperture of the retinoscope or ophthalmoscope. Factors that will block or impede the passage of light through this transparent media or affects its reflection back from fundus will produce an abnormal Red Eye Reflex. An asymmetry in the reflex from the two eyes may point towards a high refractory error or strabismus. RER test can be performed very easily and is a pivotal tool in screening of ocular abnormalities at an early age [6]. In developed countries RER of newborns is examined at a regular basis. But in developing countries like India, there is a paucity of data on RER screening of the newborns. RER screening in developed countries has shown the effectiveness ranging from 13.9% of total newborn population screened making it very effective & economical screen tool [7]. Single

Indian study evaluating the role of universal neonatal screening has shown the cost-effectiveness & skill man-power saving by this method. They showed that upto 14.93% of total screened neonates could be detected with ocular morbidities with the universal neonatal screening method [8]. Currently, there is neither a national drive nor appropriate guidelines concerning routine screening of newborns for ocular abnormalities in India. Lack of RER screening of the newborns among pediatric clinic is leading to undiagnosed ocular pathologies at early stage and late presentation with irreversible stage of blindness. Also, there is a paucity of data regarding effectiveness of RER to screen the newborns for ocular abnormalities among Indian population. Finally, we would like to develop and implement appropriate communication strategies to promote the idea that ocular disease in infants are a major public health problem and that the childhood blindness can be easily screened and prevented by simple RER test.

1.1 Research Question

What is the diagnostic accuracy of RED REFLEX TEST (RRT) in early detection of ocular abnormalities in newborns?

PICOT:

- **P** : Newborn
- **I** : Red Eye Reflex Test
- **C** : Detailed Ophthalmic Examination by Ophthalmologist
- **O** : Ocular Abnormalities
- **T** : Two Year

1.2 Aims and Objective of the Study

1.2.1 Aim

To find out the diagnostic accuracy of Red Reflex test for diagnosing ocular abnormalities in newborns.

1.2.2 Objectives

- ❖ To find out the sensitivity, specificity, positive or negative predictive value of the RRT for detecting the ocular abnormalities
- ❖ To estimate the prevalence of ocular abnormalities in newborns
- ❖ To determine the risk factors of ocular abnormalities in newborns

2. MATERIALS AND METHODS

- **Study design:** Hospital based Cross-Sectional Study
- **Setting:** The AVBRH, Sawangi is the rural medical college located in Maharashtra. This study will be conducted in NICU, Department of Pediatrics, in Jawaharlal Nehru Medical College & AVBRH Hospital, Sawangi, Wardha, from September 2020 to September 2022.
- **Inclusion criteria:** All newborns admitted in Post Natal Ward and NICU
- **Exclusion criteria:** Babies with a prenatal diagnosis of ocular abnormalities

2.1 Methodology

After obtaining the informed consent from the parents/guardians neonates will be included in the study. RER examination will be performed by the Pediatric Resident within one week of birth on the neonate. The eyes should be opened, voluntarily if needed. A direct ophthalmoscope will be used. Power of the lens will be set at Zero. Ophthalmoscope will be kept close to eye of the examiner. Both the pupils of the neonate will be focused individually. The distance between the ophthalmoscope and the neonate's eye should be 45cm. Each eye will be then visualized simultaneously. The RER of the two eyes should be symmetrically equal to be labeled as normal. A normal RER should be bright, round, red to orange in color and symmetrically equal in both eyes. RER is considered abnormal if presents with dark spots, if the reflex is dull or blunted, if there is lack of reflex and if the RER is white.

All subjects will undergo a repeat ophthalmic examination by an Ophthalmologist following which we will correlate the examination findings with respect to ocular findings determined by ophthalmologist to determine its efficacy, sensitivity and specificity in detecting neonatal ocular abnormalities.

2.2 Study Variables

- Gestational age
- Mode of delivery
- Sex
- APGAR score
- Birth weight
- Neonatal hyperbilirubinemia
- Congenital malformation
- Oxygen therapy
- Phototherapy
- Received blood transfusion.
- Red Eye reflex parameters
- Ophthalmologist opinion about ocular abnormality
- Type of Ocular abnormality

2.3 Size Calculation

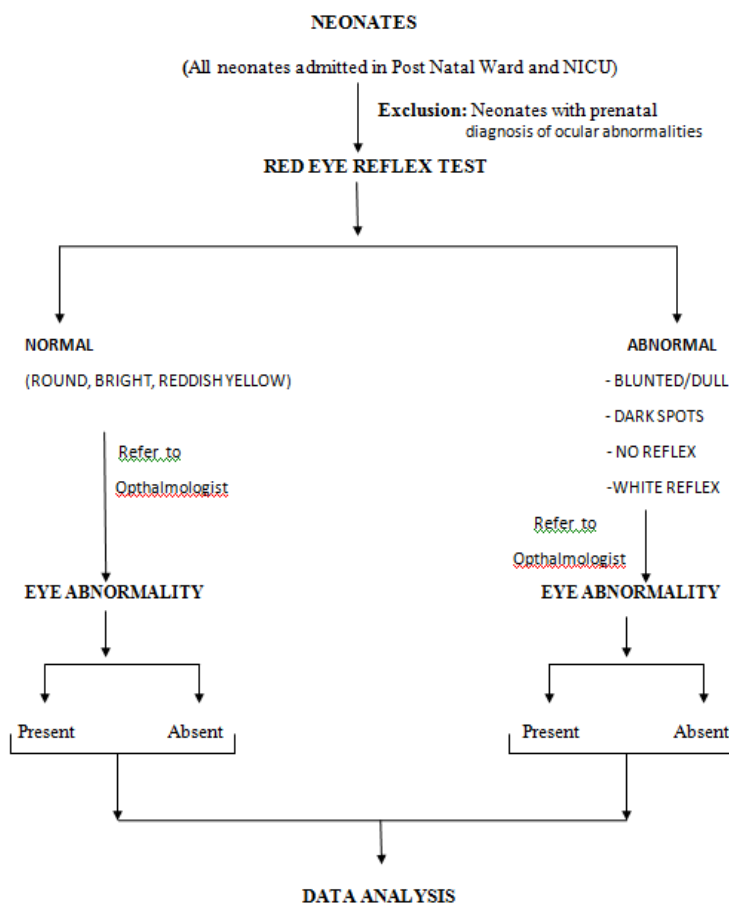
- Sensitivity of the RRT: 75%
- Sensitivity of the Reference test (Ophthalmic examination by ophthalmologist) = 95%
- Desired confidence level (%) = 95%
- Power (%) = 90%
- Alpha error (%) = 5%
- Sided: 2

Sample Size Required: 350

2.4 Statistical Analysis

Statistical analysis will be done by using STATA software version 10. Descriptive analyses of age, sex, gestation, birth weight and outcome of RER test will be performed. Categorical variables will be expressed as relative and absolute frequencies. Continuous variables will be expressed as the mean (SD) and the maximal and minimal values. Missing values will not consider while computing proportions. The findings encounter in the RER test will be associated with neonatal history variables (weight, gestational age, congenital malformation, APGAR score, use of oxygen therapy and phototherapy). The Chi square test will be used to analyze any association between the RER and the above variables. The significance level will be set at 95% for each variable. For statistical purposes, newborns will be divided into 2 groups: RER positive and RER negative. To know the accuracy of the RER for detection of ocular abnormality the Sensitivity, Specificity, positive predictive value, negative predictive value, Positive Likelihood ratio, and Negative Likelihood ratio will be calculated.

Flow chart:



Flow chart depicting the study design

3. EXPECTED RESULT

After completion of the study we will come to know the red reflex test accuracy for ocular abnormality detection in the neonates. We will come to know the sensitivity, specificity, positive predictive value (PPV) & negative predictive value (NPV) of the red reflex test. If the specificity and the sensitivity are good then we can use RRT as a routine screening method for detection of intraocular abnormalities.

4. DISCUSSION

Red eye reflex (RER) test is an effective maneuver for the early screening and diagnosis of neonatal ocular pathologies. Recent recommendations of The American Academy of Pediatrics has suggested that RER assessment should be done in neonatal period so that early diagnosis and treatment of ocular abnormalities are undertaken and lifelong visual impairment is precluded [6]. The Red Reflex is described as the red to orange reflection of light from the

fundus of the eye, observed while using a retinoscope or an ophthalmoscope (Fig. 1). Technically, RER test is simple to operate, non-invasive, very easy to perform & requiring minimal settings and equipment. It can be used for screening of different ocular abnormalities including cataracts, glaucoma and retinal abnormalities. The principle of RER test is based on using an external source of light which is to be focused onto the back of eye through the pupil, & the reflected light from back of the eye is then transmitted through the transparent media of the eye media which is viewed as reddish-orange reflection when viewed through the aperture of an Ophthalmoscope. Light from the illuminating light source is reflected by a Prism or a Mirror (Fig. 2). The light travels through the optical media which includes Tear Film, Cornea, Aqueous Humor and Vitreous Humor. Light is reflected back from fundus and through the optical media it travels into the aperture of the Ophthalmoscope to be visualized by the Examiner. Factors that will block or impede the passage of light through this transparent media

or affects its reflection back from fundus will produce an abnormal Red Eye Reflex.

Early screening and prompt management of ocular abnormalities should be commenced soon after birth because if such eye related pathologies are left undiagnosed and untreated, the pathologies may persist into adulthood potentially leading to irreversible damage to the vision. Present scenario with increased knowledge of childhood ocular diseases and the advantages of the early intervention warrants a much early screening of the children for ocular abnormalities than it was recommended in the past. With advancement in testing procedures, we now have advantage of either adopting a simple and fast screening methods or to go for more accurate but sophisticated techniques. Earlier ophthalmic examination schedule required the screening to be done only at birth and then again at the age of 4 years. But results from recent studies have added a complete ophthalmic screening at 6 months of age to the previous screening schedule.

A study done by Romano P E et al. [2] found Brückner test (a Red Reflex Test where both eyes are visualized simultaneously using a Direct Ophthalmoscope) to be an effective method in infants to screen for visual acuity, binocular acuity and ocular pathology. The study done by Cagini C et al. [3] reported that in Umbria, during the study period, 22,884 live births were reported and of them, 22,272 new born were subjected to RER. In that study, RER Test was done on 22,272 (97.3%) children out of 22884 who were born in Umbria, Italy over a span of 3 years of study (2012-2014), out of which 461 neonates (4.83%) were found to be having an equivocal or positive test results who were then referred to higher centre where three neonates were found to be affected by an important ocular pathology (two diagnosed with retinoblastoma and one diagnosed with congenital cataract). The study concluded that the ease of performing the test as well as its low cost outweighs the associated high number of false positive cases associated with screening of neonates with Red Reflex Test and that the test should be included as a part of routine neonatal assessment [5].

It also concluded the Red Reflex Test to be highly sensitive as there was no reported case of congenital ocular abnormalities on subsequent follow up visits. The Mussavi M et al. [4] in their study found that the incidence of abnormal Red Reflex was higher in neonates born to a prolonged or difficult labor. The Sun M et al. [7]

mentioned that effectiveness of Red Reflex Test to screen ocular abnormalities is greater in anterior segment ocular pathologies as compared to posterior segment ocular pathologies.

Another study done by Nie WY et al. [9] was aimed to screen the neonates for ocular disease and to obtain data regarding incidence of ocular pathology in neonates. Their screening program which included Red Reflex Test, external ocular examination and reaction to stimulation by light was performed on 15,398 neonates, in which 1266 cases involving twelve different eye diseases were detected (case prevalence rate 8.22%). Of the twelve different eye diseases, seven were congenital in their origin involved 809 of the total cases with prevalence of 5.254%. These included two cases of congenital ptosis (.013%), six cases of congenital corneal opacity (.039%), 724 cases of persistent papillary membrane (4.702%), fifteen cases of congenital cataract (0.097%), fifty four cases of persistent hyaloid artery (0.351%), seven cases of obstruction of nasolacrimal duct (0.046%) and one case of lacrimal gland prolapse (0.007%). Rest 457 cases which included five different diseases were acquired in nature with a prevalence of 2.968%. These included 391 cases of neonatal conjunctivitis (2.539%), six cases of vitreous hemorrhage (0.039%), thirty four cases of retinal hemorrhage (0.221%) and twenty three cases of neonatal dacryocystitis (0.149%).

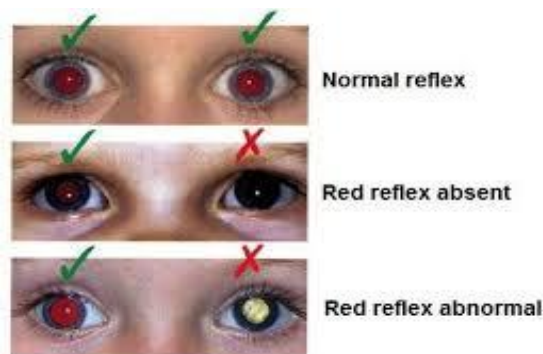


Fig. 1. Normal and abnormal red eye reflex in Neonates

Thus, it is concluded that screening of newborn using Red eye reflex is not only easy to perform and feasible but is also very cost effective and can be done with minimal requirements and favors early detection and appropriate interventions that will prevent long term sequelae associated with ocular diseases of newborns.

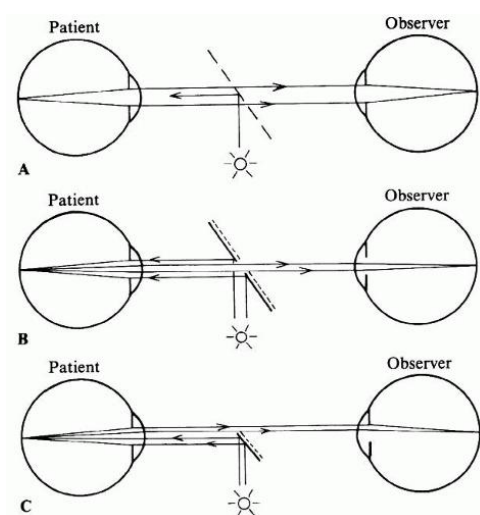


Fig. 2. Illuminating methods in direct Ophthalmoscopy

- A) Illumination with semi reflecting mirror (Helmholtz)
 B) Illumination with perforated mirror (Epkens, Ruete)
 C) Illumination with Prism or Mirror (Modern Ophthalmoscope)

A few of the studies on quality of newborn care were reported [10-13]. Studies on infant's care seeking behavior [14] and young child feeding practices [15-17] were reviewed.

5. CONCLUSION

After completion of the study we will come to know

- Efficacy of RER Test for screening ocular abnormalities in the new born.
- Correlation between different neonatal variables and ocular abnormalities in the new born
- The prevalence of ocular abnormalities in newborns in rural hospital
- The risk factors for the development of ocular abnormalities in newborns

6. SCOPE OF THE STUDY

In developed countries RER of newborns is examined at a regular basis. But in developing countries like India, there is a paucity of data on RER screening of the newborns. Currently, there is neither a national drive nor appropriate guidelines concerning routine screening of newborns for ocular abnormalities in India. We would like to develop and implement appropriate communication strategies to promote the idea that ocular disease in infants are a major public health problem and that the childhood blindness can be easily screened and prevented by simple RER test.

7. LIMITATIONS

RER mainly apply for the detection of anterior chamber abnormality of the eye than the posterior chamber.

CONSENT

It's not applicable.

ETHICAL APPROVAL

Ethical approval obtained from Institutional Ethics Committee (IEC).

COMPETING INTERESTS

Authors have declared that no competing interests exist.

REFERENCES

1. World Health Organization. Cumulative official updates to ICD–Feb 2009. Available: <http://www.Who.int/classification/icd/OfficialupdatesCombined1996-2008VOLUME1.pdf>.
2. Romano PE. Advances in vision and eye screening: screening at six months of age. *Pediatrician*. 1990;17(3):134-41.
3. Cagini C, Tosi G, Stracci F, Rinaldi VE, Verrotti A. Red reflex examination in neonates: evaluation of 3 years of screening. *Int. Ophthalmol*. 2016;114-16.
4. Mussavi M, Asadollahi K, Janbaz F, Mansoori E, Abbasi N. The Evaluation of Red Reflex Sensitivity and Specificity Test among Neonates in Different Conditions. *Iran J Pediatr*. 2014;24(6):697-702.
5. Eventov-Friedman S, Leiba H, Flidel-Rimon O, Juster-Reicher A, Shinwell ES. The red reflex examination in neonates: An efficient tool for early diagnosis of congenital ocular diseases. *Isr Med Assoc J*. 2010;12(5):259-61.
6. American Academy of Pediatrics; Section on Ophthalmology; American Association for Pediatric Ophthalmology and Strabismus, et al. Red reflex examination in neonates, infants, and children. *Pediatrics*. 2008;122:1401–4.
7. Sun M, Ma A, Li F, Cheng K, Zhang M, Yang H, et al. Sensitivity and specificity of Red Reflex Test in newborn eye screening. *J Pediatr*. 2016;179:192-196.
8. Goyal P, Padhi TR, Das T, Pradhan L, Sutar S, Butola S, Behera UC, Jain L, Jalali S. Outcome of universal newborn eye screening with wide-field digital retinal

- image acquisition system: A pilot study. *Eye (Lond)*. 2018;32(1):67-73. DOI: 10.1038/eye.2017.129. Epub 2017 Jul 24. PMID: 28737759; PMCID: PMC5770699.
9. Nie WY, Wu HR, Qi YS, Zhang M, Hou Q, Yang HX, et al. A pilot study of ocular diseases screening for neonates in China. *Zhonghua Yan Ke Za Zhi*. 2008;44(6):497-502..
 10. Patel AB, Simmons EM, Rao SR, Moore J, Nolen TL, Goldenberg RL, Goudar SS, Somannavar MS, Esamai F, Nyongesa P, Garces AL, Chomba E, Mwenechanya M, Saleem S, Naqvi F, Bauserman M, Bucher S, Krebs NF, Derman RJ, Carlo WA, Koso-Thomas, Mc Clure MEM, Hibberd PL. Evaluating the effect of care around labor and delivery practices on early neonatal mortality in the Global Network's Maternal and Newborn Health Registry. *Reprod Health*. 2020;17(2):156. DOI: 10.1186/s12978-020-01010-w. PMID: 33256790; PMCID: PMC7708898.
 11. Lohiya, Sohan, and Rajiv Pardasani. "Ocular Manifestations of Cytomegalovirus (CMV) - A Case Report. *Journal of Evolution of Medical and Dental Sciences-jemds*. 2021;10(5):319–22. Available:https://doi.org/10.14260/jemds/2021/71.
 12. Khanam N, Zahiruddin Quazi Syed RC, Goyal A, Athavale V, Gaidhane AM, Agarwal SS, Gaiki V. Prospective study on quality of newborn care. *Indian Journal of Community Health*. 2013; 25(4):432–37.
 13. Tayde Parimal, Anil Wanjari, Vikram Kokate. Golden Ring in Eyes: All That Glitters Is Not Gold! *American Journal of Medicine*. 2012;125(4):348–49. Available:https://doi.org/10.1016/j.amjmed.2011.10.020.
 14. Vani M, Jagzape T, Sachdeva P. Care seeking behaviour of families for their sick infants and factors impeding to their early care seeking in rural part of Central India. *JCDR*. 2018;12(4): SC8–12. Available:https://doi.org/10.7860/JCDR/2018/28130.11401.
 15. Kogade Priti, Abhay Gaidhane, Sonali Choudhari, Mahalaqua Nazli Khatib, Umesh Kawalkar, Shilpa Gaidhane, Zahiruddin Quazi Syed. Socio-cultural determinants of infant and young child feeding practices in rural India. *Medical Science*. 2019;23(100):1015–22.
 16. Puri S, Fernandez S, Puranik A, Anand D, Gaidhane A, Quazi Syed Z, Patel A, Uddin S, Thow AM. Policy content and stakeholder network analysis for infant and young child feeding in India. *BMC Public Health*. 2017;17(2):461. DOI: 10.1186/s12889-017-4339-z. PMID: 28675136; PMCID: PMC5496016.
 17. Zahiruddin Q, Gaidhane A, Kogade P, Kawalkar U, Khatib N, Gaidhane S. Challenges and patterns of complementary feeding for women in employment: A qualitative study from rural India. *Curr Res Nutr Food Sci*. 2016;4(1):48–53. Available:https://doi.org/10.12944/CRNFSJ.4.1.06.

© 2021 Singh and Taksande; This is an Open Access article distributed under the terms of the Creative Commons Attribution License (<http://creativecommons.org/licenses/by/4.0>), which permits unrestricted use, distribution, and reproduction in any medium, provided the original work is properly cited.

Peer-review history:

The peer review history for this paper can be accessed here:
<http://www.sdiarticle4.com/review-history/68581>