



Hang-Back Technique versus Conventional Lateral Rectus Recession in Exotropia

Amira Abou-Elnaga Elamary ^{a*}, Heba Mohamed Shafik ^a, El-Sayed Samir Arfa ^a
and Ahmed Lotfi Ali ^a

^a *Ophthalmology Department, Faculty of Medicine, Tanta University, Tanta, Egypt.*

Authors' contributions

This work was carried out in collaboration among all authors. All authors read and approved the final manuscript.

Article Information

DOI: 10.9734/JAMMR/2022/v34i2031491

Open Peer Review History:

This journal follows the Advanced Open Peer Review policy. Identity of the Reviewers, Editor(s) and additional Reviewers, peer review comments, different versions of the manuscript, comments of the editors, etc are available here: <https://www.sdiarticle5.com/review-history/89377>

Original Research Article

Received 02 May 2022
Accepted 07 July 2022
Published 22 July 2022

ABSTRACT

Background: Exotropia is a type of eye misalignment. About 90 % of all exodeviations are intermittent exotropia. Management options are non-surgical as correction of refractive error and surgical, here we discussed two surgical techniques: the conventional recession and the Hang-back recession. This study evaluated the result of both techniques in management of exotropia and investigate the longitudinal change in the lateral rectus muscle insertion by AS-OCT imaging of the muscle new insertion site.

Methods: The prospective randomized study included 40 eyes with exotropia. All cases underwent two types of surgery (the conventional recession and the Hang-back recession) and complete ophthalmological and strabismus examination before and after surgical treatment and completed six months follow up at one day, one week, one month, three months, six months.

Results: The success rate for conventional recession technique was 85%. There was no consecutive esotropia as a complication, but a long period of follow up may show delayed consecutive esotropia. There were no significant complications as slipped muscles or infection.

Conclusions: Conventional recession and hang back technique are two surgical options for lateral rectus muscle recession, results of both techniques are compared. The result showed that conventional recession technique success rate is higher than the hang back technique. Our study showed the effectiveness of both techniques as there were no cases that showed limitation of abduction.

*Corresponding author;

Keywords: Hang-Back technique; conventional lateral rectus recession; exotropia.

1. INTRODUCTION

Exotropia is a type of eye misalignment when one eye deviates outward. Exo deviation: exo meaning is (move out of) or divergent squint About 90% of all exo deviations is Intermittent exotropia, which is controlled by fusional mechanisms. Exo deviations occur more commonly in the middle East, sub equatorial Africa and East Asia than in united states. 60 – 70 % of normal new-born infants have a transient exodeviation that resolves by 4-6 months [1, 2].

In cases with exotropia, we have two surgery options, the conventional recession of the lateral rectus and the hang-back technique is the alternative technique of muscle weakening. The conventional recession is a measured retro-placement of the muscle from its original insertion. The muscle is removed from its attachment to the sclera to be inserted closer to the origin creating muscle slack. The muscle slack reduces the muscle strength. The change from original position to a new one further back on the sclera relaxes the pull of the muscle and allow the eye to attain a straighter position. The muscle should be re-inserted along its arc of contact. Hence, there is maximum limit up to which a recession can be done for lateral rectus muscle.

While the hang back technique is performed by taking a central locking knot in the muscle bulk near its insertion and two locking sutures at the two edges then the tendon of insertion is cut from the sclera and is inserted into the tendon stump instead of sclera. Thus, the muscle suspends posterior to the scleral insertion with sutures to weaken the muscle. this hang back minimizes the risk of perforation by avoiding scleral pass and allows more recession to be planned [3]. Imaging the new insertion site of the muscle by anterior segment optical coherence tomography (OCT) for both conventional recession and hang back techniques and the results will be evaluated and compared for the efficacy and accuracy of both techniques [4].

The aim of this work was to evaluate conventional muscle recession technique as regard efficacy, safety and possible complications and comparing it to the Hang back technique in patients suffering from exotropia.

2. PATIENTS AND METHODS

This prospective randomized study was conducted on 40 eyes with exotropia presented to Tanta ophthalmology university hospital from September 2019 to March 2020. The study was done after approval from the Ethical Committee Tanta University Hospitals. An informed written consent was obtained from the patients or relatives of the patients.

The inclusion criteria were patients with significant exotropia with maximum expectation angle, all types of exotropia less than 80 Δ , unocular or binocular exotropia and both genders were included. The Exclusion criteria were patients with exodeviation angle more than 80 Δ , patients with any associated ocular disease, patients who had any previous ocular surgery and non-compliant patients.

All Patients was subjected to the following:

Full detailed history which included the following: Present history: Given by the patient or by the mother: Age of onset, sudden or gradual, frequency of ocular misalignment, the direction of deviation, constant or intermittent and unilateral or Alternating Squint. Birth and developmental history, prenatal history of diseases or during pregnancy, natal history as complication during labour, postnatal history as child weight at birth and maturity of the baby and incubation, Family history (Strabismus, consanguinity, amblyopia), past history of ocular injuries, surgery, amblyopic therapy or eyeglasses. Examination data taken every visit; assessment of fixation and visual acuity in each eye in preverbal children by fixation test (CSM) method. In older children by Landolt chart where the child is asked to point where the direction of the C letter. Assessment of Cycloplegic refraction: Retinoscopic refraction or auto refract meter was done after using cycloplegic drops. Atropine 1% or cyclopentolate 1% eye drops 3 times daily for 3 days then retinoscopic refraction was done.

Measurement of angle of deviation: Corneal light reflex: Hirschberg test: Using reflection produced by pen light on the back of the cornea. It is based on 1mm deviation of corneal light reflex corresponds to 7 degree of ocular deviation or 15 PD away from the visual axis.

Krimsky's method: It is a combination of corneal light reflex and using a prism in the center of the

cornea in both eyes. Corneal reflection is produced in the two eyes by a pen light. The light is fixated by the patient's better eye. prisms are placed in front of the fixating eye to center the corneal reflection in the deviated eye. The amount of prism power needed to achieve this is the measure of the amount of deviation. This method is used to estimate the size of the squint angle in patients who are blind or deeply amblyopic.

Cover test: Cover -un cover test: To differentiate between phoria (latent) and tropia (manifest) strabismus. The alternate cover test: Done for both distance and near while fixating with and without glasses to differentiate between latent and intermittent strabismus. The prism and cover test: Using the prism to measure the angle of deviation after eyes are dissociated by alternate cover test.

Examination of ocular motility and alignment: Ductions and versions evaluated in the 6 cardinal directions of gaze and detection of any A or V patterns. Full ophthalmological examination: (As epicanthus- Anterior segment examination under a slit lamp.

Fundus examination: Done to every case to exclude retinoblastoma, congenital cataract, and any other causes of sensory strabismus.

Operative procedure: Surgery goals are ocular alignment orthotropia to over correction within 10 PD and restoring binocular vision. Indications for surgery is determined by: the state of fusional control, the angle size of deviation, the age of the patient, Surgery for intermittent exotropia was recommended for those patients who : distant angle of deviation exceeded 15Δ , gradual loss of fusional control as evidenced by increasing frequency of the manifest phase of the strabismus, exotropia occurs during more than 50% of walking hours or causes asthenopic problems, progressive increase in angle size of the basic deviation, development of suppression by worth 4 dot test, Progressive decrease or absence of stereo acuity or Surgery for children under 4 years was only done if progressive deterioration of control of binocular vision is observed.

Evaluation of outcome: Both motor and sensory evaluations successful motor alignment is defined as orthotropia to over correction $\leq 10\Delta$ at 6-meter distance.

Lateral rectus conventional recession steps in each eye: Limbal conjunctival incisions with two radial incisions were done at the limbal fusion of conjunctiva and anterior tenon capsule. the conjunctiva and the tenon capsule were dissected anterior to the muscle insertion into the sclera to facilitate later placement of sutures. The inter muscular septum and the check ligaments were dissected on each side of the muscle. The muscles were hooked by a strabismus hook. The muscle was secured with 6.0 non-absorbable Vicryl double armed suture. The muscle was sutured by full thickness locking suture at each edge of the muscle 1mm from its insertion from the sclera. Double armed 6.0 Vicryl sutures were used. The muscle was cut between the insertion and the suture. The amount of recession was measured by a calliper and marked on the sclera behind the original insertion site. The muscle was re-sutured to the sclera at the marked site posterior to the original insertion site. The muscle was tied in its place with 3 knots then cut. Closure of the limbal conjunctival incision very carefully to avoid any functional or cosmetic problems. An 8.0 Vicryl suture was used. Installation of combined anti-biotic steroid ointment at the end of the surgery and each eye was covered by an eye pad.

Surgical technique of Hang-back: Limbal conjunctival incisions with two radial incisions were done at the limbal fusion of conjunctiva and anterior tenon capsule. The conjunctiva and the tenon capsule were dissected anterior to the muscle insertion into the sclera to facilitate later placement of sutures. The inter muscular septum and the check ligaments were dissected on each side of the muscle. The muscles were hooked by a strabismus hook. A central locking knot was taken in the muscle bulk near the insertion and two locking sutures at the two edges. The tendon of insertion is cut from the scleral insertion. Calliper is used to measure the amount of hang back along the length of the suture. The needle is inserted into the tendon stump instead of the scleral attachment. The sutures are then tied over the needle holder. The needle holder is removed, allowing the muscle to hang back by the predominant amount. Hang back recession suspends the muscle back posterior to the scleral insertion with a suture to weaken the muscle. Hang back recession avoids scleral pass removing the potential for the suture knot to slip if superficial and minimizing the risk of perforation if deep. Hang back recession allows more recession to be planned and seems to be safer.

The two techniques were compared according to: Assessment of ocular alignment in both eyes in primary position by ocular light reflex and detection of ocular motility in both eyes by ductions and versions tests. Assessment of OCT imaging result of the new insertion site of the muscle measured in mm after 1.5 month postoperative and compared to the predetermined insertion site on calliper intra-operative for both operative techniques.

Imaging method: Anterior segment OCT was done for all patients. Imaging obtained by single ophthalmologist using the same device: Topcon DRI triton swept source OCT Japan.

2.1 Statistical Analysis

Statistical analysis was done by SPSS v27 (IBM®, Chicago, IL, USA). Shapiro-Wilks test and histograms were used to evaluate the normality of the distribution of data. Quantitative parametric data were presented as mean and standard deviation (SD) and were analysed by unpaired student t-test. Quantitative non-parametric data were presented as the median and interquartile range (IQR) and were analysed by Mann Whitney-test. Qualitative variables were presented as frequency and percentage (%) and analysed using the Chi-square test or Fisher's

exact test when appropriate. A two-tailed P value < 0.05 was considered statistically significant.

3. RESULTS

Table 1 shows the basic characteristics of the study patients, distant angle and SE of the study patients.

Table 2 shows the intra-operative amount of recession in mm measured from limbus by surgical caliber and Postoperative amount of recession in mm measured from spur LR insertion site by ASOCT.

Table 3 shows the residual angle at 1, 3, 6 months for group I and group II.

Table 4 shows the success of surgery among study groups at the end of follow-up.

Fig. 1 shows the distribution of successful patients throughout follow-up.

Age was significantly higher in group II compared to group I (P <0.001) and spherical equivalent was significantly higher in group I compared to group II (P <0.001). Gender and distant angle were in significantly different between both groups Table 5.

Table 1. The basic characteristics of the study patients, Distant angle and SE of the study patients

			N=40
Age		15.00 ± 11.03	
Gender	Males		18 (45%)
	Females		22 (55%)
Distant Angle (PD)		38.57 ± 9.98	
	30	16 (40%)	
	35	6 (15%)	
	40	10 (25%)	
	50	4 (10%)	
	60	4 (10%)	
Spherical Equivalent		0.564 ± 1.316	

Data was presented as Mean ±SD or frequency (%). PD: Prism dioptres

Table 2. Intra-operative amount of recession in mm measured from limbus by surgical caliber and Postoperative amount of recession in mm measured from spur LR insertion site by ASOCT

Characteristics	Group I (n=20)	Group II (n=20)
On caliber	14.6 ± 0.7	15.2 ± 1.2
ASOCT	12.65 ± 0.62	13.28 ± 1.14

Data was presented as Mean ±SD. ASOCT: Anterior optical coherence tomography

Table 3. Residual angle at 1, 3, 6 months for group I and group II

	n=20	1 month	3 months	6 months
Group I				
Residual angle in PD	0	16 (80.0%)	16 (80.0%)	16 (80.0%)
	1-5	1 (5.0 %)	0 (0.0%)	0 (0.0%)
	5-10	2 (10.0%)	2 (10.0%)	1 (5.0%)
	>10	1 (5.0%)	2 (10.0%)	3 (15.0%)
Group II				
Residual angle in PD	0	10 (50.0%)	12 (60.0%)	12 (60.0%)
	1-5	2 (10.0%)	0 (0.0%)	0 (0.0%)
	5-10	4 (20.0%)	2 (10.0%)	2 (10.0%)
	>10	4 (20.0%)	6 (30.0%)	6 (30.0%)

Data was presented as frequency (%). PD: Prism dioptres

Table 4. Success of surgery among study groups at the end of follow- up

Characteristics	Group I (n=20)	Group II (n=20)
Successful	17 (85%)	14 (70%)
Not Successful	3 (15%)	6 (30%)

Data was presented as frequency (%).

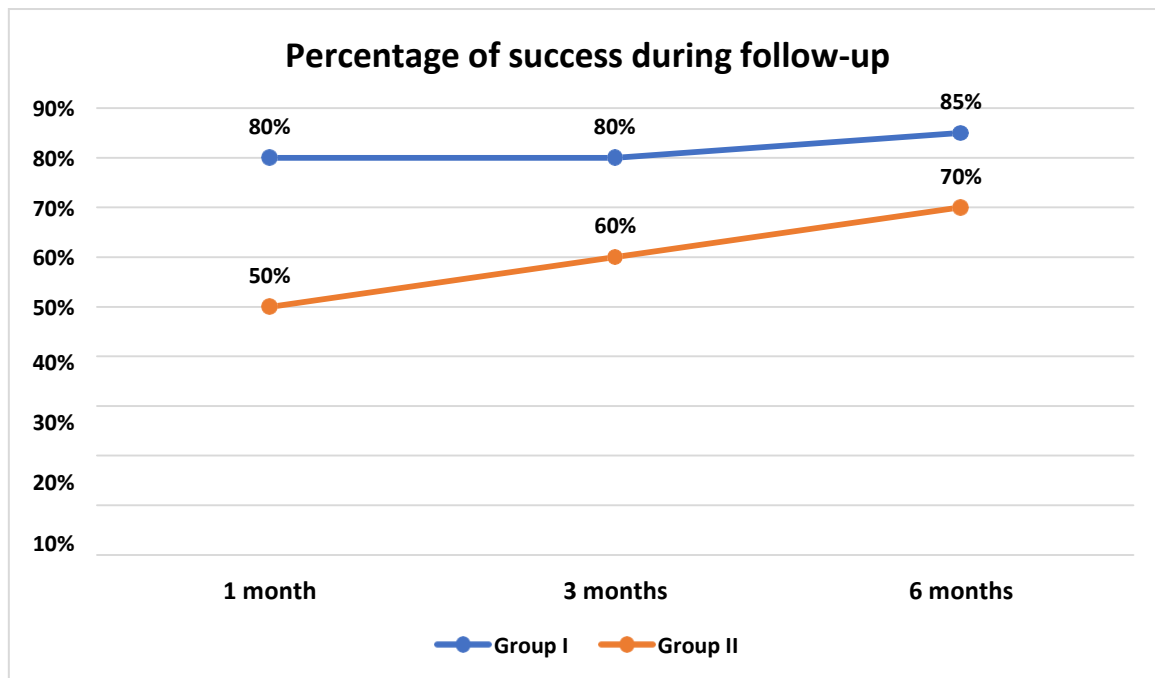


Fig. 1. Distribution of successful patients throughout follow-up

Table 5. Comparison of basic characteristics among study groups

Characteristics	Group I (n=20)	Group II (n=20)	P
Age	7 ± 1	23 ± 11	<0.001*
Gender	Males	10 (50%)	12 (60%)
	Females	10 (50%)	8 (40%)
Distant Angle	35.5 ± 6.7	42.0 ± 11.7	0.091
Spherical Equivalent	1.287 ± 0.932	-0.160 ± 1.258	<0.001*

Data was presented as Mean ±SD or frequency (%). *: Statistically significant as P value ≤ 0.05.

Table 6. Comparison of amount of recession in mm measured from limbus by surgical caliber intra-operatively and from limbus by ASOCT post-operatively in the study groups

Characteristics	On caliber	ASOCT	P
Group I (n=20)	14.6 ± 0.7	12.65 ± 0.62	<0.001*
Group II (n=20)	15.2 ± 1.2	13.28 ± 1.14	<0.001*

Data was presented as Mean ±SD. *: Statistically significant as P value ≤ 0.05. ASOCT: Anterior optical coherence tomography

The amount of recession in mm measured from limbus by surgical caliber intra-operatively was significantly higher compared to the amount of recession by ASOCT post-operatively in the study groups (P <0.001) Table 6.

4. DISCUSSION

Exotropia is a common type of strabismus accounting for 25% of all ocular misalignment in early childhood. Intermittent exotropia forms about 90% of all exodeviations and is controlled by fusional mechanisms. About 60-70% of normal new-born infant have a transient exo deviation that resolves by 4-6 months [1].

Many factors may affect the surgical outcome of exotropia as, the first presentation, age at surgical intervention, angle of deviation, an error of refraction, presence of amblyopia, binocular vision, the state of fusion and type of surgical procedure [2, 3]. The goal of surgery is getting single binocular vision of near and far gazes, the best corrected visual acuity in both eyes and good cosmetic appearance [5].

The early treatment is essential because binocular vision can be deteriorated rapidly in children causing suppression and abnormal retinal correspondence. The optimal timing of surgery remains controversial. If surgery is delayed until 4 years of age there will be increase in the incidence of amblyopia and loss of stereopsis with initial consecutive esotropia, while early surgery before 4 years of age suggests that it yields better results especially concerning preservation of sensory fusion and stereoacuity compared with later surgery; however, others believe reoperation rates, risk of developing amblyopia and loss of fusion are greater in younger age group [6-8].

A study conducted by Edelman PM, Murphree AL, et al [9] it was found that patients up until the age of six years are at risk for amblyopia and for totally losing their stereoacuity. The authors recommend frequent postoperative examinations in those patients six years of age and under who

present with consecutive esodeviation to determine the presence or absence of amblyopia, especially when subjective visual acuity is unattainable.

Moreover, a study conducted by Richard JM, Parks MM, [6] found that the surgical results of 111 consecutive patients with intermittent exotropia treated via bilateral rectus muscle recession and having at least 2 years of follow-up are reviewed. These data are analysed from a standpoint of three age groups at the time of surgery: younger than 3 years (41 patients), 3 years to younger than 6 years (42 patients), and 6 years to younger than 17 years (28 patients). The initial surgical results for all ages were as follows: 56% satisfactory, 38% under corrected, and 6% overcorrected. After appropriate management (which was almost always surgical) in those patients initially either under corrected or overcorrected, a satisfactory result was obtained in 95% of all patients comprising this series.

In our study the mean age for group I (7±1) while the mean age for group II (23 ± 11), surgical outcomes were not significantly influenced by age. Also hang back technique seems to be an effective, safe alternative to lateral rectus recession in exotropia. This is consistent with study conducted by Karim A. Gaballah [10] to assess the results of both conventional rectus recession versus hang back recession technique in strabismus surgery.

In our study we defined surgical success as orthotropia or residual esotropia or exotropia within 10 PD during follow up visits. Capo H, Repk MX, Guyton DL. [11] designed a study to assess the results obtained after conventional recession in comparison to hang back recession technique in patients with intermittent or constant exotropia and found that the hang-back recession is a simple, safe alternative to conventional recession.

Also, Orlin A, Mills M, Ying Gs, [12] designed a study that compared strabismus in a nonrandomized series of 55 children with

exotropia treated with conventional (suspension) recession group were on average 2.5 years younger and had 8(Delta) more preoperative exotropia at distance. Surgical outcomes were not significantly different in the two treatment groups. Multivariate logistic regression suggests that outcomes are at least equivalent to conventional surgery after adjusting for age, severity, and other preoperative factors likely associated with outcome. They concluded that hang-back surgical technique was as effective as conventional lateral rectus recession surgery for children with exotropia.

This also agreed with Rajavi Z, Ghadim HM, et al [13] who Conducted a study that comprised 30 patients with esotropia and 24 with exotropia. In patients with esotropia, deviation improved from 31+/-9 prism diopters (PD) preoperatively to 7+/-6 PD postoperatively for hang- back recession (n=15) and from 41+/-14 PD to 6+/-6 PD for conventional recession (n=15). Postoperative horizontal deviation was >10 PD in 40% of patients who underwent hang-back recession and 20% of patients who underwent conventional recession. In patients with exotropia, deviation improved from 28.9+/-9 PD preoperatively to 0.5+/-11 PD postoperatively for hang-back recession (n=12) and from 29+/-8 PD to 6+/-6 PD for conventional recession (n=12). Postoperative horizontal deviation was >10 PD in 24% of patients who underwent hang-back recession and 17% of patients who underwent conventional recession. Mean follow-up was 7 months.

A study conducted by Oriel Spierer, [14], to compare surgical outcome of hang back technique and conventional bimedial rectus muscle recession in infantile esotropia. thirty patients were operated hang back technique (group1) and 37 by conventional bimedial rectus recession in which the tendon was sutured directly to the globe (group 2). In each group, the angle of esotropia (PD) before and 6 months after surgery and the success rate (deviation angle of ≤ 10 PD) were documented. Esotropia improved an average of 39.7 (SD14.9) PD post operatively in group 1 from preoperative 42.7 (SD 11.6) PD TO 3.0 (SD 8.5) PD postoperatively and 45.5 (SD19.3) PD in group 2 (from preoperative 54.3 (SD16.8) PD to 8.7 (SD 12.1) PD postoperatively). Success rate defined as deviations ≤ 10 PD at 6 months postoperative examination was 83.3% in group 1 and 70.1% in group 2 surgical outcomes are not significantly influenced by age. No complications were

occurred in both groups, which proved that Hang back technique is as effective as conventional bimedial rectus muscle recession in correcting infantile esotropia.

On the other hand a study conducted by Repka MX, Fishman PJ, et al [15], that was carried out on the hang back recession technique of lateral recti for correction of exotropia to evaluate this procedure in a wider field of lateral recti rather than to evaluate in the narrow field of recessing medial recti in esotropia where in the dissection of medial recti from the inter muscular septum carries the risk of loss of the muscle in case of slipping. To overcome this risk of muscle loss, a small modification is performed in this study, a central locking knot is taken in the central part of the muscle bulk, then one locking note at each edge of the muscle, so that the muscle is totally secured when clearly dissecting the inter muscular septum, The use of hang back suspensions has been shown to be an effective means of weakening rectus muscles. The exact position where the muscle reattaches to the globe has been questioned, the study performed 8 large Hang-back recessions on the rectus muscles of Cynomolgus monkeys. Eight weeks post operatively the attachment sites were determined by re exploration. Six of the recessions were within 0.5 mm of the intended site, the muscles were found an average of 0.4 mm anterior to the intended site. The results confirmed that the muscle reattaches close to the intended location. Eight exaggerated recessions were similarly performed, there were more variable in the site of reattachment. Only three muscles were reattached within 0.5 mm of the intended site. There was a mean forward reattachment of 1.1 mm. Four of the 16 muscles were found reattached by pseudo tendon rather than directly to the sclera. There have been many trials investigating changes in the muscle insertion site after strabismus surgery [16, 17].

The newly developed anterior segment optical coherence tomography (AS-OCT; Visante by Carl Zeiss Meditec, Dublin, CA), wavelength in 1310 nm, generates a two-dimensional high-resolution image from a reflected light beam. It has faster scanning (minimizes motion artifact), low scattering, and high penetration into turbid tissue such as sclera, iris, angle, and opaque corneas. Nowadays it is employed more and more often in imaging the anterior segment structures of the eye, specifically in anterior chamber biometry, corneal pachymetric mapping, and angle evaluation. Moreover, AS-OCT

evaluation is a noncontact examination, which is particularly suitable for children and postoperative examination.

AS-OCT, which appears to be superior to other devices for studying EOM, was designed based on the principle of low-coherence interferometry using a super luminescent diode with a 1310-nm wavelength. It has the advantages of being a noncontact imaging modality for the anterior compartments of the eye at a specific meridian in the sitting position. Following a study by Liu et al [18] that showed horizontal rectus muscle measurement with AS-OCT. The study determined the ability of the anterior segment optical coherence tomography (AS-OCT) in measuring the distance from the corneoscleral limbus to the insertion site of the horizontal extraocular muscles in adult patients with strabismus. A total of 16 strabismus patients were recruited for this study. The limbus-insertion distances of the horizontal rectus muscles were measured with AS-OCT preoperatively and calipers intraoperatively. The study Measurements of the limbus-insertion distances were taken on 37 muscles of the 16 patients: 18 medial rectus (MR) and 19 lateral recti (LR).

Moreover a study conducted by Ngo CS et al [19] to study the accuracy of anterior segment optical coherence tomography (AS-OCT) function of Cirrus HD-OCT 500 (Carl Zeiss Meditec, Dublin, CA) in calculating the insertion of rectus muscles from the limbus in patients undergoing primary squint surgery. Insertion distance from limbus was measured using AS-OCT function of Cirrus HD-OCT 500 preoperatively. Intraoperative measurements were taken using Castroviejo caliper. A total of 128 muscles were successfully imaged and evaluated, including 13 superior recti (10.15%), 23 inferior recti (17.96%), 35 medial recti (27.34%) and 57 lateral recti (44.53%). 124 muscles (96.9%) were within 1mm difference, which was considered clinically acceptable. They concluded that anterior segment scan function of Cirrus HD-OCT 500 is an accurate method to detect the insertion of extraocular recti muscles in patients of primary strabismus surgery.

According to a study conducted by J-Y Lee [20] the mean distance of spur LR insertion measured preoperatively with AS-OCT was (5.5 ± 0.7 mm). The amount of recession measured on caliber intra operative in mm from spur – LR insertion site ranged from (14-16mm) in group1 with mean amount of correction (14.6 ± 0.7), while in group

II ranged from (14-17 mm) with mean amount of correction (15.2 ± 1.2) so, the amount of recession measured in mm by caliber ranged from (7-10 mm) according to the angle of deviation in PD. There were 20 patient who underwent conventional lateral rectus recession group I (n= 20) with deviation angle ranged from (30-40 PD), there amount of recession ranged from (7-9 mm) measured by caliber intraoperative, while group II (n=20) who underwent hang back recession technique of the lateral rectus muscle with deviation angle ranged from (30-60 PD), there amount of recession ranged from (7-10 mm) measured by surgical caliber intraoperative.

5. CONCLUSIONS

Conventional recession and hang back technique are two surgical options for lateral rectus muscle recession, results of both techniques are compared. The result showed that conventional recession technique success rate is higher than the hang back technique. Our study showed the effectiveness of both techniques as there were no cases that showed limitation of abduction.

CONSENT

It is not applicable.

ETHICAL APPROVAL

It is not applicable.

COMPETING INTERESTS

Authors have declared that no competing interests exist.

REFERENCES

1. Archer SM, Sondhi N, Helveston EM. Strabismus in infancy. *Ophthalmology*. 1989;96:133-7.
2. Nixon RB, Helveston EM, Miller K, Archer SM, Ellis FD. Incidence of strabismus in neonates. *Am J Ophthalmol*. 1985;100:798-801.
3. David K. Coats SEO. Surgically Important Anatomy. *Strabismus Surgery and its Complications*. Berlin, Heidelberg: Springer Berlin Heidelberg; 2007. p. 3-20.
4. De-Pablo-Gómez-de-Liaño L, Fernández-Vigo JI, Ventura-Abreu N, Morales-Fernández L, Fernández-Pérez C, García-Feijóo J, et al. Spectral domain optical

- coherence tomography to assess the insertion of extraocular rectus muscles. J AAPOS. 2016;20:201-5.
5. Sharma P, Gaur N, Phuljhele S, Saxena R. What's new for us in strabismus? Indian J Ophthalmol. 2017;65:184-90.
 6. Richard JM, Parks MM. Intermittent exotropia. Surgical results in different age groups. Ophthalmology. 1983;90:1172-7.
 7. Raab EL, Parks MM. Recession of the lateral recti. Early and late postoperative alignments. Arch Ophthalmol. 1969;82:203-8.
 8. Scott WE, Keech R, Mash AJ. The postoperative results and stability of exodeviations. Arch Ophthalmol. 1981;99:1814-8.
 9. Edelman PM, Brown MH, Murphree AL, Wright KW. Consecutive esodeviation... then what? Am Orthopt J. 1988;38:111-6.
 10. Gaballah KA. Hang-back technique versus conventional rectus recession in strabismus surgery. J Egypt Ophthalmol Soc. 2018;111:123-8.
 11. Capó H, Repka MX, Guyton DL. Hang-back lateral rectus recessions for exotropia. J Pediatr Ophthalmol Strabismus. 1989;26:31-4.
 12. Orlin A, Mills M, Ying GS, Liu C. A comparison of hang-back with conventional recession surgery for exotropia. J AAPOS. 2007;11:597-600.
 13. Rajavi Z, Ghadim HM, Nikkhoo M, Dehsarvi B. Comparison of hang-back and conventional recession surgery for horizontal strabismus. J Pediatr Ophthalmol Strabismus. 2001;38:273-7.
 14. Spierer O, Spierer A. Comparison of hang-back and conventional bimedial rectus recession in infantile esotropia. Graefes Arch Clin Exp Ophthalmol. 2010;248:901-5.
 15. Repka MX, Fishman PJ, Guyton DL. The site of reattachment of the extraocular muscle following hang-back recession. J Pediatr Ophthalmol Strabismus. 1990;27:286-90.
 16. Tamburrelli C, Salgarello T, Vaiano AS, Scullica L, Palombi M, Bagolini B. Ultrasound of the horizontal rectus muscle insertion sites: implications in preoperative assessment of strabismus. Invest Ophthalmol Vis Sci. 2003;44:618-22.
 17. Ozgen A, Ariyurek M. Normative measurements of orbital structures using CT. AJR Am J Roentgenol. 1998;170:1093-6.
 18. Liu X, Wang F, Xiao Y, Ye X, Hou L. Measurement of the limbus-insertion distance in adult strabismus patients with anterior segment optical coherence tomography. Invest Ophthalmol Vis Sci. 2011;52:8370-3.
 19. Ngo CS, Smith D, Kraft SP. The accuracy of anterior segment optical coherence tomography (AS-OCT) in localizing extraocular rectus muscles insertions. J AAPOS. 2015;19:233-6.
 20. Lee JY, Park KA, Lyu IJ, Oh SY. Postoperative change in lateral rectus muscle insertion measured by anterior segment optical coherence tomography. Eye (Lond). 2017;31:1556-61.

© 2022 Elamary et al.; This is an Open Access article distributed under the terms of the Creative Commons Attribution License (<http://creativecommons.org/licenses/by/4.0>), which permits unrestricted use, distribution, and reproduction in any medium, provided the original work is properly cited.

Peer-review history:

The peer review history for this paper can be accessed here:
<https://www.sdiarticle5.com/review-history/89377>