



Relationship of the Excessive placental Calcification and Amniotic Fluid Turbidity with Fetal Outcome in Normotensive and Preclampsic Pregnancies

Basma T. Mahmoud^{a*}, Hosam A. Zyton^b, Ahmed M. Osman^a and Hesham M. Eltokhy^a

^a *Department of Obstetrics and Gynecology, Faculty of Medicine, Tanta University, Egypt.*

^b *Department of Radiology, Faculty of Medicine, Tanta University, Egypt.*

Authors' contributions

This work was carried out in collaboration among all authors. All authors read and approved the final manuscript.

Article Information

DOI: 10.9734/JAMMR/2022/v34i1931443

Open Peer Review History:

This journal follows the Advanced Open Peer Review policy. Identity of the Reviewers, Editor(s) and additional Reviewers, peer review comments, different versions of the manuscript, comments of the editors, etc are available here: <https://www.sdiarticle5.com/review-history/88210>

Original Research Article

Received 05 April 2022

Accepted 13 June 2022

Published 14 June 2022

ABSTRACT

Background: However, the trigger for abnormal placental development and the subsequent cascade of events remains unknown.)Placental calcification often noted on ultrasound examination during pregnancy, is characterized by widespread deposition of calcium on the placenta, resulting in echogenic foci the aim of this study is to assess the relation between excessive Placental calcification and amniotic fluid turbidity with fetal outcome in normotensive and preeclampsia woman.

Methods: Fifty pregnant women aged from 20 to 30 years old, classified into two groups (normotensive group & preeclampsic group) each group involved 25 cases.

Results: there was 40% of preeclampsia had turbid amniotic fluid and only 8% of normotensive group had turbid amniotic fluid with no statistical difference in between (P= 0.188).

Conclusions: This study concluded that stair step regimen improves the ovulation rate and pregnancy rate without any detrimental side effects compared to traditional regimen. It helps to know the sensitivity and resistance of an individual to CC much earlier and helps to plan ahead with alternative treatment for desired outcome.

*Corresponding author;

Keywords: *Abnormal placental development; excessive placental calcification; amniotic fluid turbidity; preeclampsia.*

1. INTRODUCTION

Preeclampsia is a syndrome characterized by the onset of hypertension and proteinuria or hypertension and end-organ dysfunction with or without proteinuria after 20 weeks of gestation [1].

Additional signs and symptoms that can occur include visual disturbances, headache, epigastric pain, thrombocytopenia, and abnormal liver function. These clinical manifestations result from mild to severe microangiopathy of target organs, including the brain, liver, kidney, and placenta [2].

The pathophysiology of preeclampsia likely involves both maternal and fetal/placental factors [3].

Abnormalities in the development of placental vasculature early in pregnancy may result in relative placental underperfusion/ hypoxia/ ischemia, which then leads to release of antiangiogenic factors into the maternal circulation that alter maternal systemic endothelial function and cause hypertension and other manifestations of the disease (hematologic, neurologic, cardiac, pulmonary, renal, and hepatic dysfunction) [4].

However, the trigger for abnormal placental development and the subsequent cascade of events remains unknown [5].

Placental calcification often noted on ultrasound examination during pregnancy, is characterized by widespread deposition of calcium on the placenta, resulting in echogenic foci [6].

When the process has advanced to the deposition of calcium on the basal plate and septa, calcification may appear to be linear or even circular [7]. Under the Grannum classification for ultrasound grading, placental calcification of this degree is designated Grade III, with significant formation of indentations or ring-like structures within the placenta [8].

Placental calcification commonly increases with gestational age, and becomes apparent after 36 weeks' gestation. Placental problems may cause low amniotic fluid. If the placenta is not providing enough blood and nutrients to the baby, then the baby may stop recycling fluid [9,10].

Amniotic fluid is a mixture of urine, Fluid from the fetal lung, Saliva, Cellular debris from the skin, transitional epithelium from the fetal genitourinary and Meconium from the fetal colon may be present in late gestation tract [11].

Cellular debris (vernix caseosa) - the amount of cellular debris may be considerable and may render the amniotic fluid opaque to the ultrasound beam. There is a vague relationship between the amount of cellular debris and fetal maturity [12].

The aim of this study is to assess the relation between excessive Placental calcification and amniotic fluid turbidity with fetal outcome in normotensive and preeclampsia woman.

2. PATIENTS AND METHODS

This study was conducted at department of obstetrics and gynecology at tanta university hospitals

1. Maternal age between 20 to 30 years.
2. Gestational age between 32 to 34 weeks.
3. Singleton pregnancy.
4. Free from any medical disorders with pregnancy, uterine anomalies, fetal congenital anomalies and premature rupture membranes.
5. Primigravida.
6. Ultrasound was done.

All patients in this study were subjected to the following:

2.1 History Taking

A-Personal history

- Name – age – parity – occupation – special habits of medical importance).

B-Menstrual history

1. Last menstrual period
2. Regularity of the cycle and amount of flow of the Last menstrual period will be normal in amount of flow and duration
3. Had not used oral contraceptive pills in the three months preceded the pregnancy or depot injectable contraception for 6-8 months before last menstrual period.

C-Present history

- Presence of uterine contraction.
- Associated symptoms: (bleeding, abdominal pain)
- Routine treatment first trimester like folic acid supplement

D-Obstetric history: For each previous delivery:

- Number.
- Antepartum period (previous preterm labor or abortion).
- Postpartum and purperium period.
- Previous history of miscarriage

F- Past history: Of post-partum hemorrhage, sepsis or chronic disease

G- Contraceptive history

H- Family History

2.2 Clinical Examination

General Examination and obstetric examination

2.3 Investigation

- (cbc-rh-pt-inr-liver function-renal function - coagulation profile)
- CTG study.

2.4 Ultrasound Study

- Measurement of fetal biometry.
- Detection of congenital malformations.
- Evaluation of placental grading.
- Amniotic fluid turbidity.

➤ Trans Abdominal Ultrasound

2d ultrasound system equipped with a4-8MHz trans abdominal transducer. which examined placental grading and amniotic fluid turbidity.

Procedure and intervention

- The results of the ultrasound examination were notified to the attending obstetrician and appropriate percutaneous during cesarean section.
- During caesarean sections amniotic fluid was examined if clear or not.
- Fetal apgar score was done.

2.5 Statistical Analysis

The sample size was calculated using Epi-Info software statistical package created by World Health organization and center for Disease Control and Prevention, Atlanta, Georgia, USA version 2002. The criteria used for sample size calculation ($n > 33$) were 95% confidence limit, 80% power of the study, expected outcome in in treatment group 90% compared to 60% for control groups.

Analysis of data were performed by SPSS v25 (SPSS Inc., Chicago, IL, USA). Quantitative parametric variables (e.g. age) were presented as mean and standard deviation (SD). They were compared between the two groups by unpaired student's t- test and within the same group by paired T test. Quantitative non-parametric variables (e.g. VAS) were presented as median and range and compared between the two groups by Mann Whitney (U) test and within the same group by Wilcoxon test. P value < 0.05 was considered significant.

3. RESULTS

This prospective cohort study included 50 pregnant women who were categorized into two groups, the first group included 25 women with normal blood pressure though out pregnancy and women in the second group (25women) suffering from preeclampsia.

The mean age of the studied cases was 25 ± 3.5 years and the mean gestational age was 33.16 ± 0.90 weeks as showed in Table 1.

- Table 1 shows that in Preeclampsia group the mean maternal age was 25.44 years, the mean gestational age was 33.16 weeks, the mean weight was 79.64 Kg, the mean systolic blood pressure was 112.20 , the mean diastolic pressure was 96.40 and the mean fetal weight was 2.81Kg.
- There was significant difference between normotensive group and preeclamptic group as regard blood pressure .
- There was no significant difference between normotensive group and preeclamptic group as regard maternal age , Gestational age , Weight ,and Fetal wt in kg .

Table 1. Demographic data of the two groups

		Range		Mean	±	S. D	t. test	p. value
Maternal age	Normotensive	20	– 30	25.16	±	3.54	0.296	0.768
	Preeclampsia	21	– 30	25.44	±	3.12		
Gestational age	Normotensive	32	– 35	32.96	±	0.98	0.753	0.455
	Preeclampsia	32	– 35	33.16	±	0.90		
Weight	Normotensive	69	– 98	81.16	±	8.41	0.682	0.498
	Preeclampsia	67	– 90	79.64	±	7.30		
Systolic	Normotensive	100	– 125	112.20	±	8.91	12.592	0.001*
	Preeclampsia	130	– 180	150.80	±	12.47		
Diastolic	Normotensive	60	– 80	72.80	±	7.37	12.675	0.001*
	Preeclampsia	90	– 110	96.40	±	5.69		
Fetal weight (kg)	Normotensive	2	– 4	2.70	±	0.53	0.664	0.510
	Preeclampsia	1.95	– 4	2.81	±	0.62		

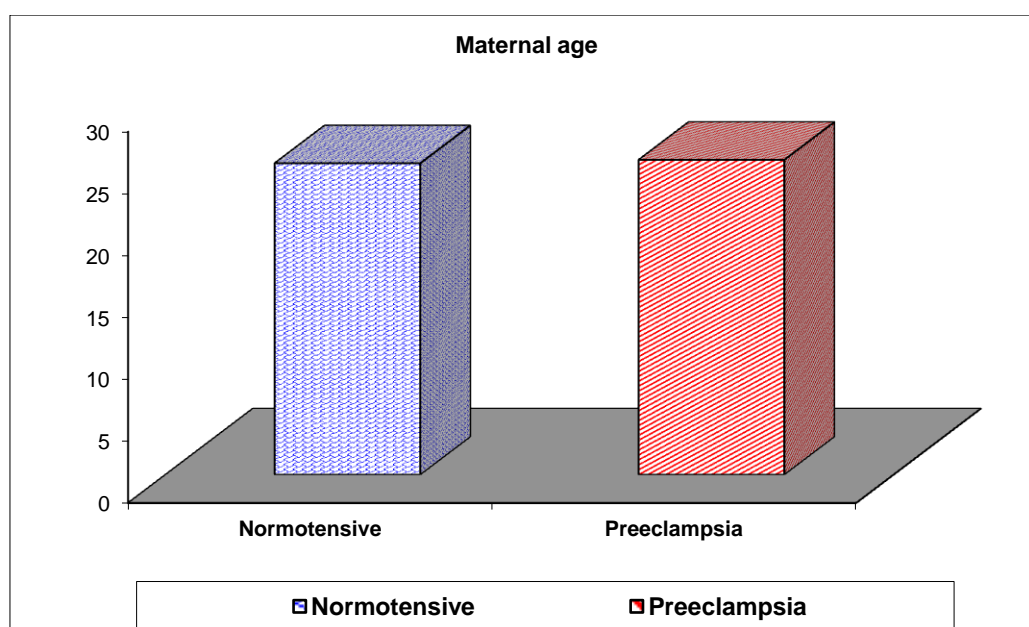


Fig. 1. Maternal age

Table 2. Fetal apgar score for 2 groups

		Range		Mean	±	S. D	t. test	p. value
Fetal APGER score at 1minute	Normotensive	5	– 10	7.48	±	1.00	2.860	0.006*
	Preeclampsia	3	– 9	6.36	±	1.68		
Fetal APGER score at 5 minute	Normotensive	9	– 10	9.92	±	0.28	2.705	0.009*
	Preeclampsia	6	– 10	9.12	±	1.45		

- There was significant difference between normotensive group and preeclamptic group as regard Fetal apger score at both 1 and 5 minute as the mean apger score in preeclampsia group at 1 minute was 6.36 and at 5 minute was 9.12 while in normotensive group it was 7.48 at 1 minute and 9.92 at 5 minute .
- There was no significant difference between normotensive and preeclamptic group as regard Admission to NICU.

- There was 16% of preeclampsia group admitted to NICU and only a case from normotensive group admitted to NICU.
- This table shows that there was 48% of preeclampsia group had grade 2 of placenta and 52% of grade 3 but in normotensive group there was 60% of grade 2 and 40% of grade 3. There was no significant difference between normotensive and preeclamptic group as regard placental grade.

Table 3. admission to NICU for 2 groups

Admission to NICU		Normotensive	Preeclampsia	Total
Yes	N	1	4	5
	%	4.0%	16.0%	10.0%
No	N	24	21	45
	%	96.0%	84.0%	90.0%
Total	N	25	25	50
	%	100.0%	100.0%	100.0%
Chi-square	χ^2	2.001		
	P-value	0.157		

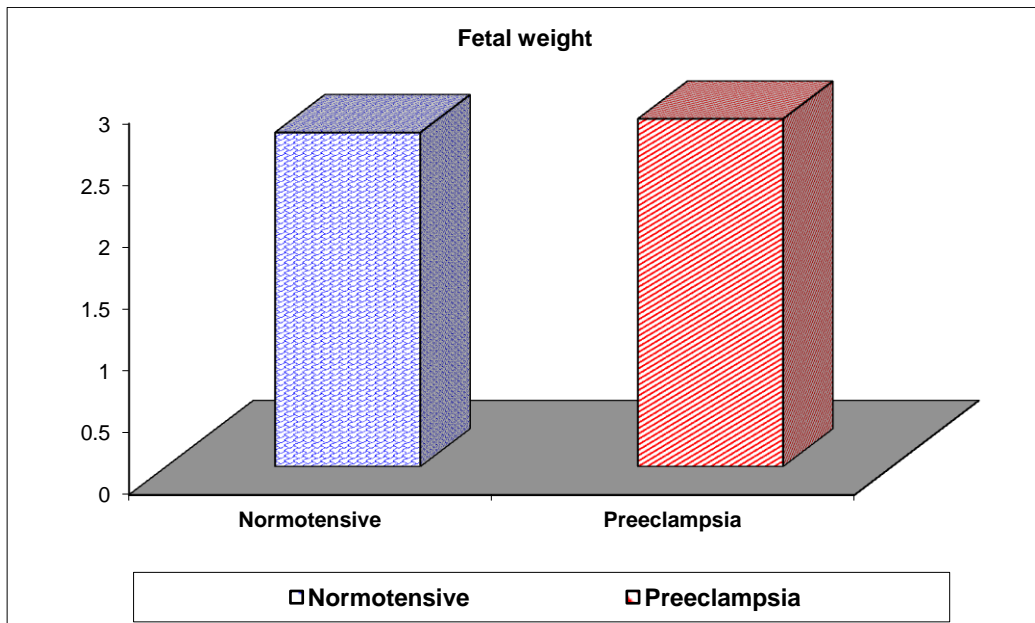


Fig. 2. Fetal height

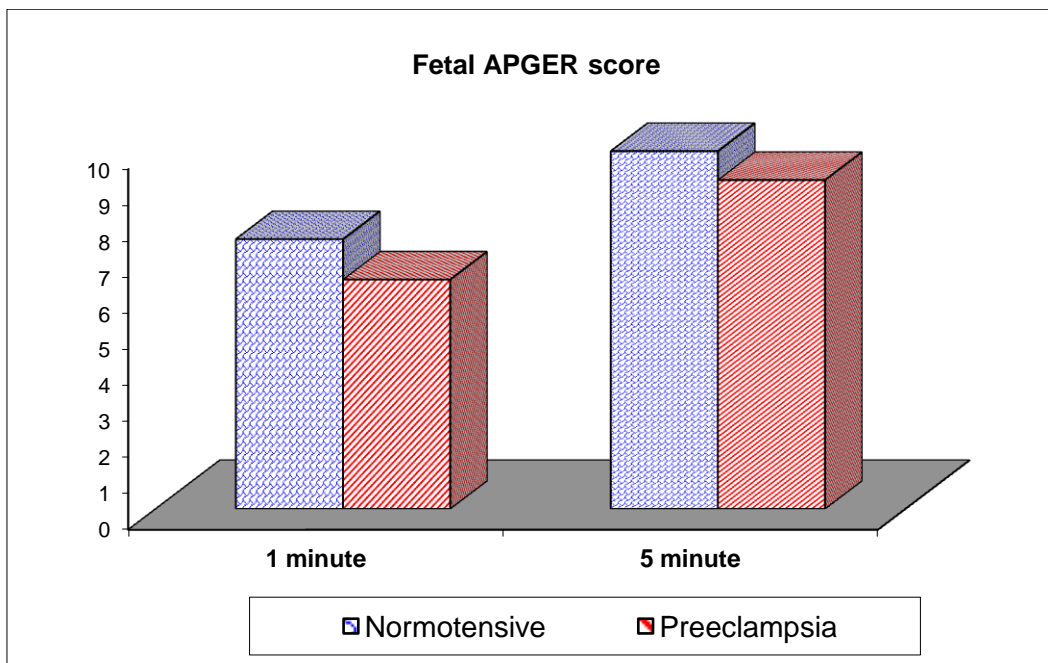


Fig. 3. Fetal APGER score

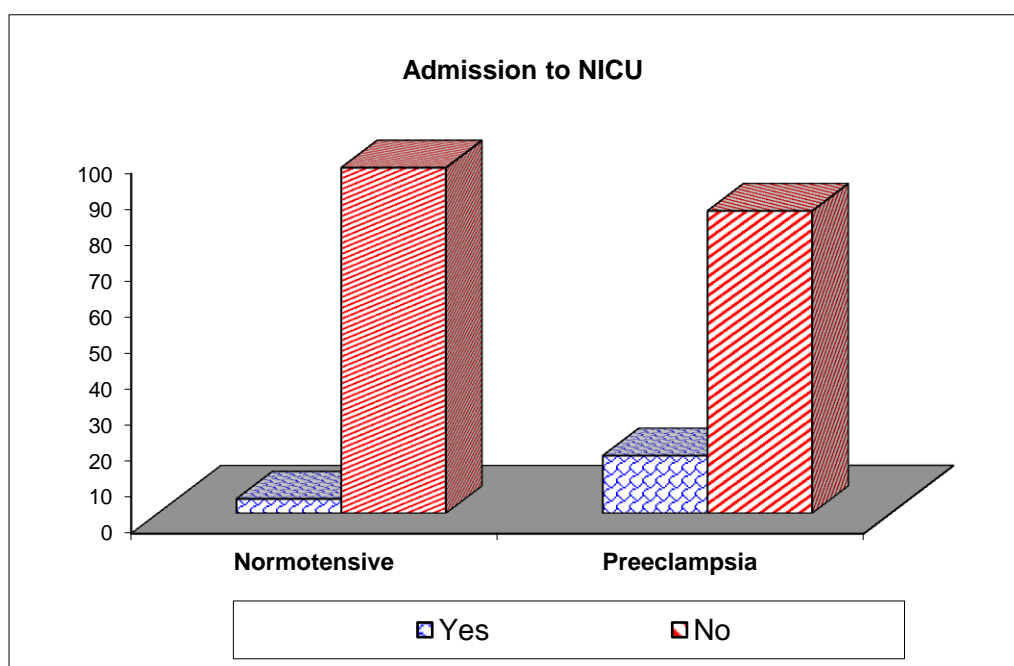


Fig. 4. Admission to NICU

Table 4. Placental grading for 2 groups

Placental grading		Normotensive	Preeclampsia	Total
2	N	15	12	27
	%	60.0%	48.0%	54.0%
3	N	10	13	23
	%	40.0%	52.0%	46.0%
Total	N	25	25	50
	%	100.0%	100.0%	100.0%
Chi-square	X ²	0.725		
	P-value	0.395		

Table 5. The cause of amniotic fluid echogenicity on prenatal sonography for 2 groups

Amniotic fluid turbidity		Normotensive	Preeclampsia	Total
Vernix	N	2	7	9
	%	100.0%	70.0%	75.0%
Meconium	N	0	3	3
	%	.0%	30.0%	25.0%
Total	N	2	10	12
	%	100.0%	100.0%	100.0%
Chi-square	X ²	0.800		
	P-value	0.371		

- There was no significant difference between normotensive and preeclamptic group as regard Amniotic fluid turbidity as in preeclampsia group there was 30% had Meconium in their amniotic fluid.
- This table shows that there was 40% of preeclampsia had turbid amniotic fluid and only 8% of normotensive group had turbid amniotic fluid with no statistical difference in between (P= 0.188)
- Table 7 shows that there was a positive statistical significant correlation in between fetal weight and placental grading while no difference in between fetal weight and each of the following (amniotic fluid turbidity, maternal age and maternal blood pressure)

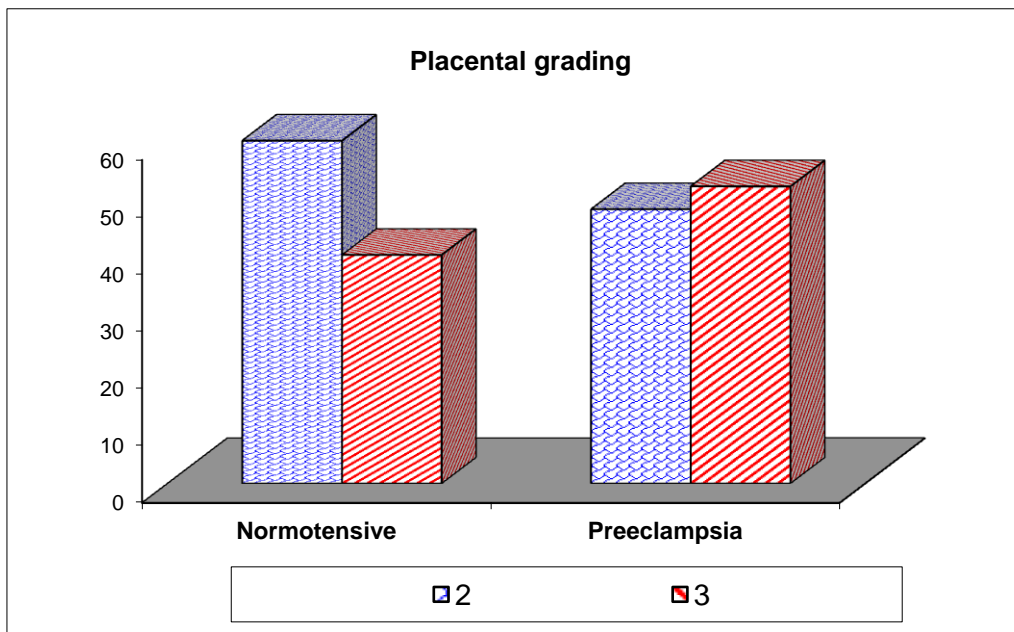


Fig. 5. Placental grading

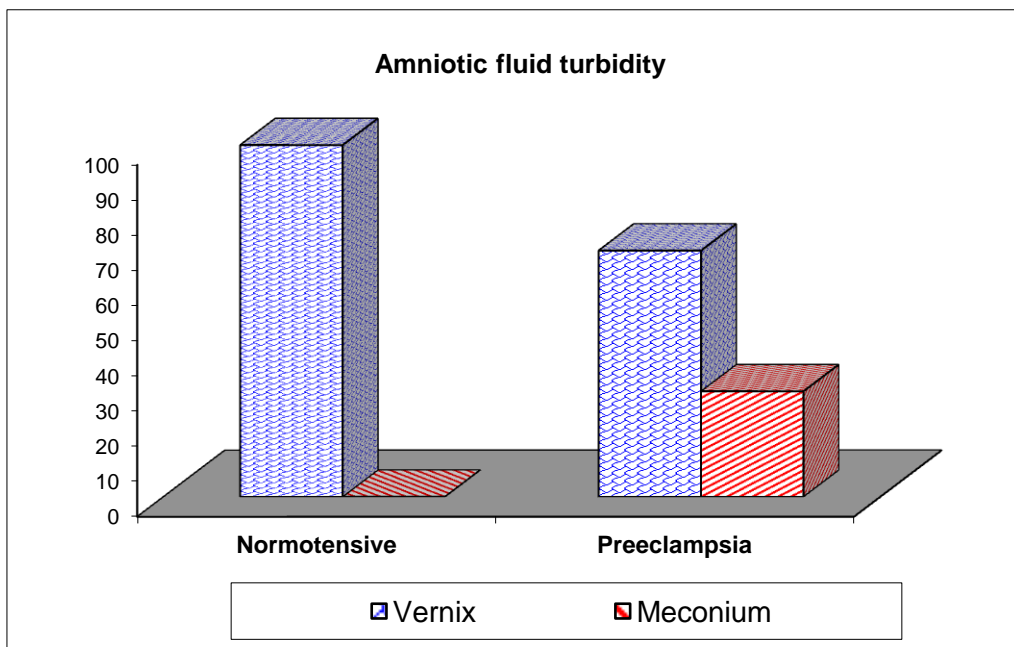


Fig. 6. Amniotic fluid turbidity

Table 6. Amniotic fluid echogenicity on prenatal sonography for 2 groups

Amniotic fluid turbidity		Normotensive	Preeclampsia	Total
turbid	N	2	10	12
	%	8.0%	40.0%	24.0%
clear	N	23	15	38
	%	92.0%	60.0%	76.0%
Total	N	25	25	50
	%	100.0%	100.0%	100.0%
Chi-square	X ²	4.793		
	P-value	0.188		

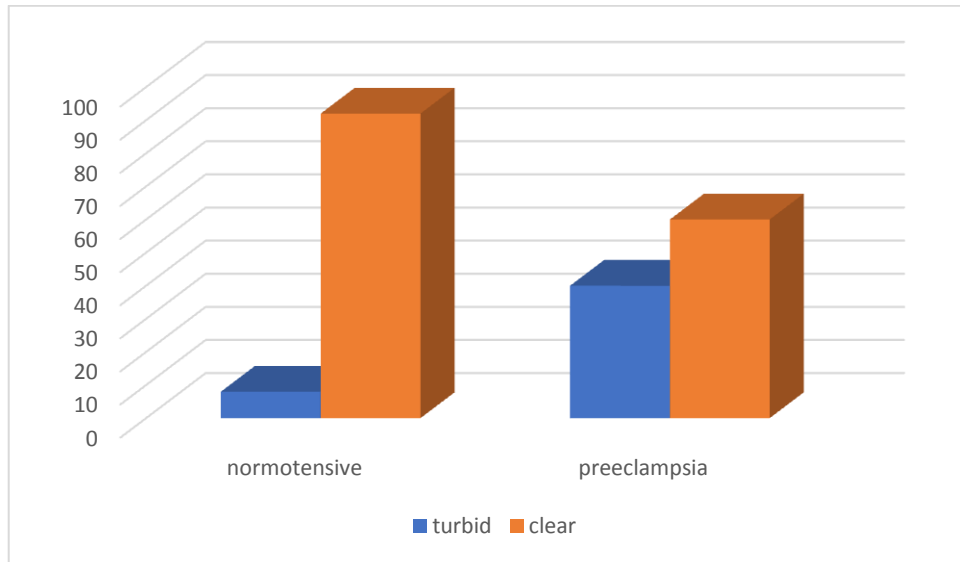


Fig. 7. Fetal weight and maternal data

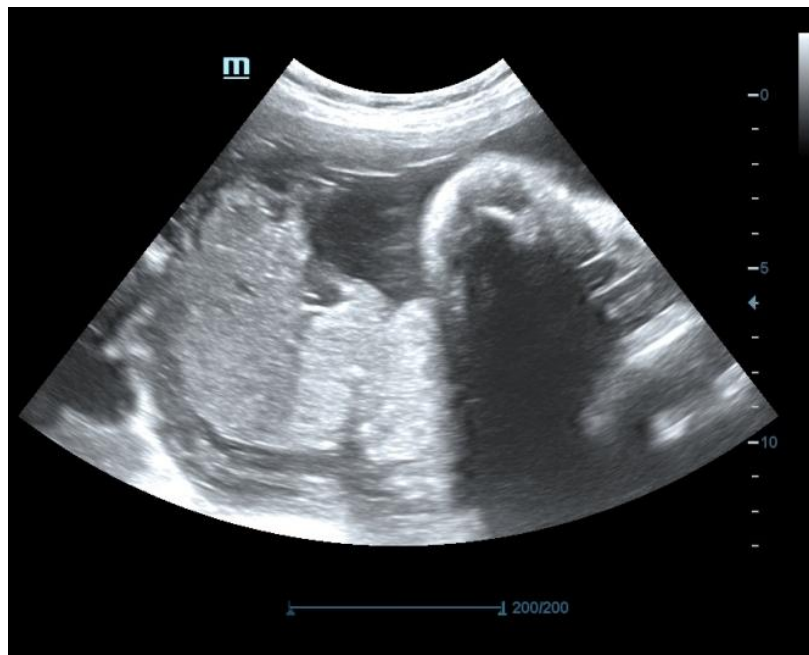Table 7. Correlation between fetal weight and maternal data in Preeclampsia group

	Fetal weight	
	r_s	p
Placental grading	0.472	0.036
Amniotic fluid turbidity	0.317	0.173
Maternal age	-0.333	0.151
Maternal blood pressure	0.051	0.830

r_s : Spearman coefficient

*: Statistically significant at $p \leq 0.05$

4. CASES PRESENTATIONS



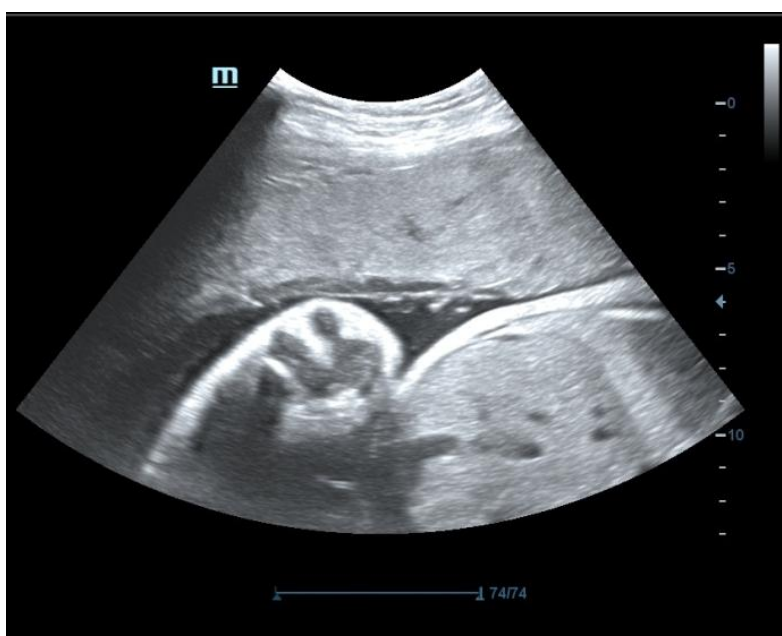

Fig. 8. USG images

5. DISCUSSION

Preeclampsia (PE) is a pregnancy-specific disease characterized by new-onset hypertension and proteinuria after 20 weeks of gestation accompanied with placental hypoperfusion. It is considered a major cause for fetal growth restriction, and in severe cases, it can progress into maternal multiorgan dysfunction or fetal and maternal death [13].

Pathogenesis of PE is not well understood, while abnormal inflammation and immuneresponses and impaired coagulation-fibrinolysis systems are frequently mentioned [14].

Excessive placental calcification may be associated with Pregnancy induced hypertension (PIH), Placental abruption, intra uterine growth restriction (IUGR), cigarette smoking [12].

The aim of work of the present study was to assess the relation between excessive Placental calcification and amniotic fluid turbidity with fetal outcome in normotensive and preeclampsia woman.

To elucidate this aim 50 women were involved in the study as following: 25 women for Normotensive group, 25 for Preeclamptic group.

The mean maternal age in the Normotensive group was 25.16 years while in the Preeclamptic

group was 25.44years which near to the results by Chauhan et al. [13] as the mean age in control group was 25 ± 3.3 years and in the Preeclamptic group was 24 ± 3.4 years.

Pradeep et al. [15] stated that the most common age of Preeclampsia was 19-24 years and 21-25 years in Manjusha et al. [16] study.

In the present study, there was no significant difference in between Normotensive and Preeclampsia groups as regard to maternal age which agrees with the study done by Raji and Suba [17] who had the same results between the two groups included their study.

In the current study there was no significant difference in between Normotensive and Preeclampsia groups as regard to Gestational age which in line with Raji and Suba [17]

In this study , there was no significant difference in between the studied groups regarding to weight which disagrees with the study done by Goswami et al. [18] where there was a high significant difference in between Normotensive and Preeclampsia groups as regard to weight.

In the present study, the mean Systolic in Normotensive group was 112.20 while in Preeclampsia groups it was 150.80 and the mean diastolic in normotensive group was 72.80 and in Preeclampsia group was 96.40 which near

to the results by Chauhan et al. [19] as the mean Systolic in Normotensive group was 120 while in Preeclampsia groups it was 179 and the mean diastolic in normotensive group was 77.6 and in Preeclampsia group was 116.

In the study conducted by Pradeep et al, [15] majority of preeclampsia group had diastolic BP more than 110 mmHg and in the study of Sunita et al, [20] 68% of eclampsia patients had BP > 160/110 mmHg

As regard to fetal weight, the mean fetal weight in normotensive group was 2.70 Kg while in Preeclampsia group was 2.81 Kg with no significant difference in between them which coincide with the study done by Ezeigwe et al. [21] who found that mean fetal weight in control 2.66 vs in preeclampsia group 2.79 kg; with no significant difference in between $p=0.81$

While in the study done by Goswami et al. [18] the fetal weight in control group was 2.790 Kg (ranges from 1.8 to 3.6 Kg) as compare to mean fetal weight of Preeclampsia group 2.195 Kg (ranges from 1.4 to 3.0 Kg). The difference in mean fetal weight was statistically significant.

This finding corroborates with the studies by Madhu et al. and Udaina and Jain with average neonatal weight of 2.1 and 2.2 kg respectively in preeclampsia groups [22, 23].

The study conducted by Rahman et al. [19] shows, that pregnancy induced hypertension was found to be an independent risk factor for low birth weight.

Hossain et al, [24] stated that the fetal mortality and morbidity associated with abruption of placentae is found to be responsible for 30% of stillbirths and hypertensive diseases which is responsible for 28% of stillbirths.

Regarding to Fetal APGER score, there was a significant difference in between the normotensive group and the Preeclampsia group regard to APGER score at minute and 5 minute which agrees with the study done by Goswami et al., Chen et al. [8,18].

Chen et al. [8] stated that Early preterm placental calcification is associated with a higher incidence of poor pregnancy outcome, both in mother (postpartum hemorrhage, maternal transfer to the intensive care unit) and fetus (including preterm birth low birth weight, low Apgar score and neonatal death).

In the present study, there was no significant difference in between normotensive and preeclampsia groups regarding to Admission to NICU with $P=0.157$ which agrees with the study done by Zakaria et al. [25] who found no difference with $P=0.073$. But there was high significant difference in between normotensive and preeclampsia groups regarding to Admission to NICU in the study done by Chen et al. [8].

Vintzileos and Tsapanos [26] proposed adding placental grading as a component of the biophysical profile for the evaluation of fetal wellbeing. In their scoring system, a finding of Grade III placenta would have the lowest score (0). This is equivocal since many researchers regard placental calcification as an aging process rather than a pathological change.

Calcification is regarded as evidence of placental senescence or degeneration. As regard to placental grading of calcifications, there was no significant difference in between the normotensive group and the Preeclampsia group which in agreement with the study done by Ezeigwe et al. [21]. This is somewhat in agreement with the work of Narasimha and Vasudeva 2011 in Karnataka, India [27].

But Goswami et al. [18] stated that there was a high significant difference in between the normotensive group and the Preeclampsia group regarding to placental grades $p= <0.001$.

Sharief et al. [28] stated that Placental calcification is seen more frequently in primigravidas. In the study conducted by Majumandar et al. [29] from India observed the calcium deposits are mostly observed in the villi and basement membrane of the villi which is strongly suggestive of uteroplacental insufficiency because of narrow lumen.

Although some researchers have proposed that occult nanobacterial infection of the placenta might be responsible for preterm placental calcification, the true mechanism remains unclear. The serial changes are supposed to be gradual occlusion of vessels by deposition of calcium and fibrin (notable on ultrasound), which impairs placental function and eventually results in poorer pregnancy outcomes [30].

The action appears to be time-dependent because late preterm placental calcification is not related to adverse pregnancy outcome. Hence, placental calcification is not only an aging process, but is also a reflection of underlying placental dysfunction when it is noted in earlier

stages of pregnancy. More attention should be paid to women with early preterm placental calcification even if the pregnancy is regarded as normal, in the absence of risk factors such as smoking, alcohol consumption, hypertension or diabetes [31].

In these women with early preterm placental calcification, closer antepartum surveillance may be considered for the evaluation of fetal wellbeing. In addition, these women should be closely monitored and well prepared during delivery because of their increased risk for maternal complications [8].

The normal sonographic appearance of AF is an anechogenic image surrounding the fetus and the umbilical cord. In the present study, there was no significant difference in between normotensive and preeclampsia groups as regard to Amniotic fluid turbidity with $P=0.371$ as in preeclampsia group there was 30% cases meconium and the remaining 70% were vernix that agrees with Kehl et al. [32] who found that, there was no significant difference for the presence of meconium between preeclampsia group and control group.

Also, our results agreed with the results reported by Shah and Sharma [33] in another study where there was no difference in presence of meconium and amniotic fluid turbidity between the two groups.

A retrospective study by Brown *et al.* [34] described that very echogenic AF during the third trimester as an unreliable indicator of meconium or blood in AF. Nineteen such cases were investigated with amniocentesis. One case of meconium (5%) was detected and the remaining 95% had vernix.

Similarly, Petrikovsky *et al.* [35] prospectively studied 19 cases of twin pregnancies, each with one amniotic sac containing echogenic AF and the other containing anechoic AF. Only one case (5%) of meconium detected in the echogenic group compared to 4 (21%) in the anechoic group.

A lot of studies and case reports reveal that ultrasonic finding of a echogenic AF at term in a normal pregnancy has no significant association with meconium and adverse pregnancy outcomes [35,36].

Posh et al., [37] also stated that the most common cause of echogenic liquor was vernix

caseosa, followed by meconium. This is in accordance with the study conducted by Shrestha et al. [38] who reported vernix (81.4%) and meconium (18.6%) as the most common causes of echogenic liquor.

Zakaria et al. [25] found that 28% of the cases had meconium stained labour in preeclampsia group and 10% of the cases had meconium stained labour in control group with statistically significant difference between the two groups ($p=0.027$).

6. CONCLUSIONS

The data in this study seem to confirm that placental calcification is physiological process of no clinical significance.

Echogenic amniotic fluid on prenatal ultrasonography is not predictive of meconium and has no effect on fetal outcome.

CONSENT AND ETHICAL APPROVAL

- Agreement for this study was obtained from the hospital's ethical committee in addition informed consent was obtained from pregnant women after adequate provision of information regarding the study requirements, Purpose and risks.
- The study was approved by ethics committee of faculty of medicine tantu university.
- There was adequate provisions to maintain privacy of participants and confidentiality of the data.

COMPETING INTERESTS

Authors have declared that they have no known competing financial interests or non-financial interests or personal relationships that could have appeared to influence the work reported in this paper

REFERENCES

1. Al-Jameil N, Khan FA, Khan MF, Tabassum HJJocmr . A brief overview of preeclampsia. 2014; 6:1.
2. Henderson JT, O'Connor E, Whitlock EPJAoim. Low-dose aspirin for prevention of morbidity and mortality from preeclampsia. 2014;161: 613-4.
3. Arulkumaran N, Lightstone LJBP, Obstetrics RC, Gynaecology. Severe pre-

- eclampsia and Hypertensive Crises. 2013; 27:877-84.
4. Brichant JF, Bonhomme VJAAB. Preeclampsia: an update. 2014;65:137-49.
 5. Bibbins-Domingo K, Grossman DC, Curry SJ, Barry MJ, Davidson KW, Doubeni CA, et al. Screening for preeclampsia: US preventive services task force recommendation Statement. 2017;317: 1661-7.
 6. Hansmann M, Hackelöer B-J, Staudach A. Ultrasound diagnosis in obstetrics and gynecology: Springer Science & Business Media; 2012.
 7. Sersam LWJIPMJ. Ultrasonographically observed grade iii placenta at 36 weeks' gestation: maternal and fetal outcomes. 2011;10.
 8. Chen K, Chen L, Lee YJUio, gynecology Exploring the relationship between preterm placental calcification and adverse maternal and Fetal Outcome. 2011;37: 328-34.
 9. Chen K-H, Seow K-M, Chen L-RJP. The role of preterm placental calcification on assessing risks of stillbirth. 2015;36:1039-44.
 10. Cooley SM, Donnelly JC, Walsh T, McMahon C, Gillan J, Geary MPJTJoM-F, et al. The impact of ultrasonographic placental architecture on antenatal course, labor and delivery in a low-risk primigravid population. 2011;24:493-7.
 11. Underwood MA, Gilbert WM, Sherman MPJJop. Amniotic fluid: not just fetal urine anymore. 2005;25:341-8.
 12. Sepulveda WH, Quiroz VHJJPM. Sonographic detection of echogenic amniotic fluid and its clinical significance. 1998;17:333-5.
 13. Gathiram P, Moodley JJCjo A. Pre-eclampsia: Its pathogenesis and Pathophysiology. 2011;27: 71.
 14. Dusse LM, Rios DR, Pinheiro MB, Cooper AJ, Lwaleed BAJCCA. Pre-eclampsia: relationship between coagulation, fibrinolysis and inflammation. 2011;412:17-21.
 15. Pradeep M, Shivanna LJJoRTiS, Technology. Retrospective study of eclampsia in a teaching Hospital. 2013;8: 171-73.
 16. Manjusha S, Vandana N, Goutham R, Sneha M, Atmaram PJIJoP. Eclampsia: A retrospective study in a Tertiary Care Centre. 2013;6.
 17. Raji C, Suba SJIJoR, Contraception, Obstetrics, Gynecology Comparative study: normotensive and preeclampsia mother presenting with imminent symptoms of eclampsia in third trimester of pregnancy. 2013;9:1655.
 18. Goswami P, Lata H, Memon S, Khaskhelli LBJJ. Excessive placental calcification observed in PIH patients and its relation to fetal outcome. 2012;11:143.
 19. Chauhan P, Rawat U, Bisht V, Purohit RJJoEoM, Sciences D. Comparison of cogulation profile in pre eclamptic and eclamptic patients with normotensive pregnant patients. 2014;3:3208-16.
 20. Sunita T, Desai RM. Eclampsia in a Teaching Hospital: Incidence, clinical profile and response to Magnesium Sulphate by Zuspan's regimen; 2013.
 21. Ezeigwe CO, Okafor CI, Eleje GU, Udigwe GO, Anyiam DCJO, international g Placental peripartum pathologies in women with preeclampsia and eclampsia; 2018.
 22. Sankar KD, Bhanu PS, Ramalingam K, Kiran S, Ramakrishna BJA, biology c Histomorphological and morphometrical changes of placental terminal villi of normotensive and preeclamptic mothers. 2013;46:285.
 23. Udainia A, Jain MJJASI. Morphological study of placenta in pregnancy induced hypertension with its clinical relevance. 2001;50:24-7.
 24. Hossain N, Khan N, Khan NHJJ. Obstetric causes of stillbirth at low socioeconomic settings. 2009;59:744-7.
 25. Zakaria A-EM, Mohamed AH, Badr KA-EKJTEJoHM. The Relationship between Amniotic Fluid Index (AFI) & Single Largest Vertical Pocket and Perinatal Outcome in Late Severe Preeclampsia. 2019;75:2646-52.
 26. Vintzileos A, Tsapanos VJUio, Obstetrics GTOJotlSoUi, Gynecology. Biophysical assessment of the fetus. 1992;2:133-43.
 27. Narasimha A, Vasudeva DJIJoP. Microbiology. Spectrum of changes in placenta in toxemia of Pregnancy. 2011;54:15.
 28. Sharief M, Manther AJE-EMHJ. Abruptio placentae: Perinatal out come in normotensive and hypertensive patients in Basra, Iraq. 1998;4:319-323.
 29. Majumdar S, Dasgupta H, Bhattacharya K, Bhattacharya AJJASI. A study of placenta in normal and hypertensive pregnancies. 2005;54:1-9.

30. Agababov R, Abashina T, Suzina N, Vainshtein M, Schwartsburd P. Link between the early calcium deposition in placenta and nanobacterial-like infection. 2007;32:1163-8.
31. Emmrich PJ. Pathology of the placenta. X. Syncytial proliferation, calcification, cysts, pigments and metabolic disorders. 1992;138:77-84.
32. Kehl S, Schelkle A, Thomas A, Puhl A, Meqdad K, Tuschy B, et al. Single deepest vertical pocket or amniotic fluid index as evaluation test for predicting adverse pregnancy outcome (SAFE trial): A multicenter, open-label, randomized controlled trial. 2016;47:674-9.
33. Shah R, Sharma P. Comparison of Amniotic Fluid Index and Single Deepest Vertical Pool method for predicting fetal outcome. 2017;13:401-5.
34. Brown DL, Polger M, Clark PK, Bromley BS, Doubilet PM. Very echogenic amniotic fluid: ultrasonography-amniocentesis correlation. 1994;13: 95-7.
35. Petrikovsky B, Schneider EP, Gross BJ. Clinical significance of echogenic Amniotic Fluid. 1998;26:191-3.
36. Tam G, Al-Dughhaishi T. Case report and literature review of very echogenic amniotic fluid at term and its clinical significance. 2013;28:e060.
37. Posh S, Rafiq S, Dar MA, Aslam R, Bhat SA. Role of amniotic fluid echogenicities in the prediction of fetal outcome. 2020;47:33.
38. Shrestha S, Bhandary S, Dwa Y, Jaiswal P, Parmar B, Karki DB. Echogenic liquor at term pregnancy on ultrasonography is not always meconium. 2017;4:7-11.

© 2022 Mahmoued et al.; This is an Open Access article distributed under the terms of the Creative Commons Attribution License (<http://creativecommons.org/licenses/by/4.0>), which permits unrestricted use, distribution, and reproduction in any medium, provided the original work is properly cited.

Peer-review history:

*The peer review history for this paper can be accessed here:
<https://www.sdiarticle5.com/review-history/88210>*