



A Rare Primary Thyroid Tumor with a Poor Prognosis Is Angiosarcoma

Songül Şahin

Department of Pathology, Çankırı Karatekin University, Çankırı, Turkey

Email: songulsahin@karatekin.edu.tr

How to cite this paper: Şahin, S. (2024) A Rare Primary Thyroid Tumor with a Poor Prognosis Is Angiosarcoma. *Open Access Library Journal*, 11: e11733.
<https://doi.org/10.4236/oalib.1111733>

Received: May 23, 2024

Accepted: June 27, 2024

Published: June 30, 2024

Copyright © 2024 by author(s) and Open Access Library Inc.

This work is licensed under the Creative Commons Attribution International License (CC BY 4.0).

<http://creativecommons.org/licenses/by/4.0/>



Open Access

Abstract

Primary angiosarcoma of the thyroid gland is a rare histological subtype of thyroid malignancy. This tumor is destructive and locally aggressive with a high risk of recurrence. Metastatic disease is associated with a poor prognosis. To our knowledge, this case is the 8th reported and officially documented in Turkey. A 66-year-old female patient with a 30-year history of thyroid goiter presented at the clinic with swelling in the throat and shortness of breath for two months. Neck ultrasonography revealed a hypoechoic nodular lesion measuring 8 × 6 cm with macro- and microcalcifications, which occupied the right lobe. Macroscopic examination revealed a nodular lesion measuring 9 × 9 × 7 cm in the right thyroid lobe with a smooth outer surface and a hard consistency. Gray-purple nodules with significant hemorrhagic and necrotic areas, some of which exhibited calcification, were observed in the sections of this nodule. On histopathological examination, the neoplastic cells had slightly hyperchromatic, atypical, and equally sized nuclei. The atypical neoplastic cells also had partial trabecular structures and vascular spaces. Atrophy was observed in the surrounding thyroid tissue. During the immunohistochemical staining examination, CD31 was strongly positive in tumor cells while CD34, calcitonin, and thyroglobulin were negative in these cells. Thyroglobulin was positive in the atrophic thyroid tissue. Metastases of angiosarcoma were detected in cervical lymph nodes at all dissected levels. The significance of presenting this case lies in its ability to raise awareness among pathologists and clinicians who are knowledgeable about a rare thyroid tumor. This will aid early diagnosis and prompt treatment, increasing the chances of accurate diagnosis and ultimately improving survival outcomes.

Subject Areas

Clinical Medicine, Pathology

Keywords

Aggressive, Angiosarcoma, CD31, Thyroid, Vascular Tumor

1. Introduction

Thyroid angiosarcoma is endemic in the European Alpine regions. It has the highest incidence, accounting for around 16% of thyroid cancer cases in the region. However, it is less prevalent in other parts of the world [1].

The tumor can grow to significant dimensions and frequently exhibits extensive areas of necrosis and hemorrhage. It is often misidentified as anaplastic thyroid carcinoma. The clinical characteristics closely mimic those of anaplastic cancer [2]. This tumor exhibits a destructive and locally aggressive nature with a high likelihood of recurrence. Endothelial cells typically form the lining of freely moving channels in histology [3]. The tumor usually contains epithelioid endothelial cells with large, vesicular nuclei and prominent basophilic nucleoli [4].

Oftentimes, the growth pattern is invasive. Tumor cells express vascular markers (factor VIII, CD34, and CD31), which may lead to the spread of the tumor to nearby tissue [5]. There are often times early tumor metastases to local lymph nodes and the lungs [6]. In advanced stages, metastatic spread to the bone marrow or other organs may occur [6]. Metastatic disease is associated with a worse prognosis. The post-diagnosis and post-surgical treatment survival time is typically only a few months [5] [7]. Despite the prevalence of epithelial malignancies and thyroid disorders, primary thyroid sarcomas are uncommon [3].

In this report, we present the case of a 66-year-old female patient who presented with a neck mass resulting from an uncommon malignancy. An informed consent form was obtained from the patient regarding the pre-surgical procedures and the use of disease-related information without disclosing personal details.

2. Case Presentation

The 66-year-old female patient who had a 30-year history of thyroid goiter presented with persistent shortness of breath for two months and a progressively enlarging goiter. The patient was examined in the general surgery clinic. A hard, regular, nodular mass measuring approximately 9 cm was discovered during a physical examination of the right thyroid lobe. A systemic examination revealed enlarged lymph nodes and left vocal cord paralysis. The left lobe of the thyroid measured 2.5 × 20 × 18 mm with irregular borders and micro-macrocalcification. A hypoechoic nodular region measuring 8 × 6 cm with micro-macrocalcifications was seen in the right lobe.

The results of the thyroid function tests are as follows: Free thyroxine (fT4) = 1.27 ng/mL, free triiodothyronine (fT3) = 1.61 pg/mL, and TSH = 0.442 uIU/mL. The C-reactive protein (CRP) levels were abnormally high at 117 mg/L.

The white blood cell (WBC) count increased to 16,000 mL. The abdominal and thorax CT scans revealed the presence of several metastases in the lungs, as well as in the mediastinal, supraclavicular, cervical, and hilar lymph nodes. It was ultimately agreed that the patient would require a total thyroidectomy and 2-3-4 level lymph node dissection a consensus was reached by the general surgery, ear, nose and throat and oncology council. The patient's postoperative condition was regular, but she died of disease progression 6 months later.

Histopathology

The dimensions of the right and left lobes were approximately $5 \times 3.5 \times 1.2$ cm, and encased on three sides during the macroscopic inspection (**Figure 1**). The right thyroid lobe was sent in the same container as a $9 \times 9 \times 7$ cm nodular formation which had a regular surface and was hard in consistency. The sections of this nodule revealed gray-purple nodules with areas of calcification, hemorrhage, and necrosis in some areas. Sections of the surrounding thyroid tissue were seen. The sections of the lymph node neck dissection specimen were necrotic and hemorrhagic. The samples were fixed in 10% neutral formalin and then embedded in paraffin.

The majority of the samples collected from the mass had necrotic areas that were visible under a microscope. **Figure 2** shows a very small portion that contained a vital fragment of atrophic and malignant thyroid tissue (**Figure 2**). The nuclei of neoplastic cells were somewhat hyperchromatic, abnormal, and homogeneous in size. Partial trabecular structure and vascular spaces were present in atypical neoplastic cells (**Figure 3**). The thyroid tissue around the affected area showed signs of atrophy and adenomatous hyperplasia. The tumor cells that were subjected to immunohistochemical and histological labeling had a strong positive response to CD31 (diluted 1:100, Thermo Scientific, Fremont, CA). In contrast, the tumor cells lacked CD34 (diluted 1:400, Thermo Scientific, Fremont, CA), calcitonin (diluted 1:100, Thermo Scientific, Fremont, CA), and thyroglobulin (diluted 1:100, Thermo Scientific, Fremont, CA). Thyroglobulin was found to be present in atrophic thyroid tissues (**Figure 4**).



Figure 1. A 9 cm lesion in the right thyroid lobe with hemorrhagic cross-sections and a smooth exterior.

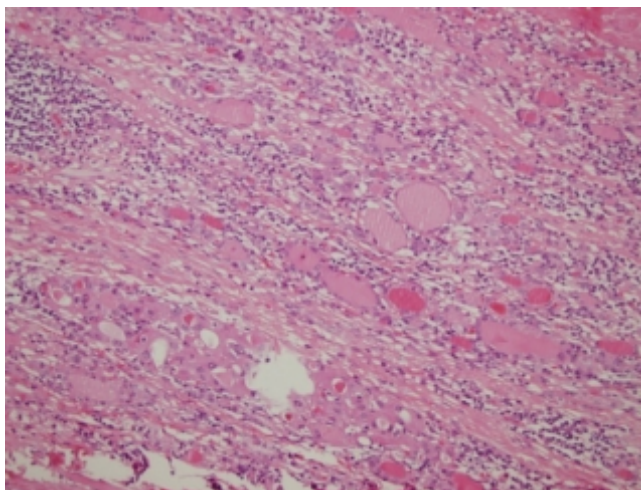


Figure 2. Around the tumor, a small portion of atrophic thyroid tissue is selected (H&E $\times 100$).

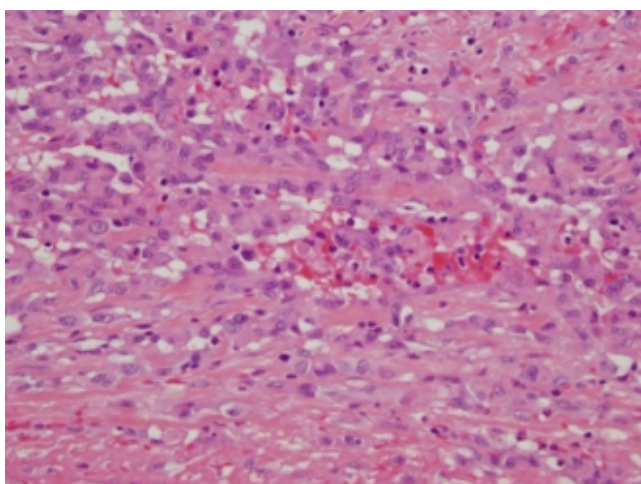


Figure 3. Neoplastic cells have relatively hyperchromatic, aberrant, and uniformly sized nuclei. Atypical neoplastic cells have partial trabecular structure and vascular spaces (H&E $\times 200$).




Figure 4. The atrophic thyroid tissues were discovered to contain thyroglobulin (IHK thyroglobulin $\times 100$).

3. Discussion

Sarcomas are less common than the highly prevalent thyroid epithelial tumors. Primary angiosarcoma of the thyroid gland is a rare histological type of thyroid malignancy that is more prevalent in the Alps and less prevalent in other regions [1]. Although previously considered to be an angiomatoid subtype of anaplastic carcinoma, it has now been recognized as a separate category of soft tissue tumors in the 2013 WHO classification system [1]. Diagnosing the histology of this tumor is often challenging. It can be mistaken for anaplastic tumors and other primary thyroid sarcomas. Due to its high recurrence rate, localized aggression, and destructive behavior, curing it is a significant challenge. [5] [7].

Extracapsular spread and metastases serve as strong indicator of poor prognosis. In this case, metastases to the lymph nodes and lungs were observed [6]. In elderly patients who have multiple metastases, it is important to evaluate the possibility of sarcoma. By the year 2020, the British literature had documented only 59 histologically verified cases of primary angiosarcoma of the thyroid gland, making it a relatively rare type of cancer. To our knowledge, this is the eighth occurrence in Turkey to be reported [6] [8]-[13]. The age range is becoming more common as people become older [4] [14] [15].

Females have a higher likelihood of experiencing the disease compared to males [4] [14] [15]; thus, the patient's age aligns with the research findings. Also, the tumor did not show any clinical signs. However, dyspnea, discomfort, and difficulties swallowing may occur depending on the extent of invasion. On inspection, the patient's vocal cords were paralyzed. Based on the invasion status, the literature has reported several symptoms including dyspnea, hoarseness, and dysphagia [14] [16]. Additionally, there may be an unanticipated increase in the size of the mass, and discomfort caused by bleeding into the tumor.

Hormone levels might fluctuate and the CRP height might take the semblance of the sediment height [6]. Our patient exhibited elevated levels of CRP and WBC, which are commonly associated with tumors, but there was no concurrent evidence of infection. There is a clear correlation between goiter and iodine deficiency [15]. Adenomatous thyroid is typically present in the tumor background [16].

The patient was prescribed proposal and had been monitored for a goiter for 30 years. A peripheral blood sample was taken for biochemical analysis, and the thyroid hormone levels were found to be normal. The tumor measured 9 cm in size on both ultrasound and macroscopic measurements. The literature reported tumor diameters ranging from 3.5 cm to 12 cm [4].

Histological appearance may exhibit the presence of cords, necrosis, anaplastic hyperchromatic cells, and rarely many erythrocytes [4].

A macroscopic inspection of the section surface may reveal areas that are solid and interspersed with cysts. These solid sections often undergo necrosis and hemorrhage.

Microscopically, thyroid angiosarcomas resemble soft tissue angiosarcomas.

Due to necrosis, severe inflammation, hemorrhage, and fibrosis, tumor cells are typically seen exclusively around the lesion's perimeter [15]. Both macroscopy and microscopy revealed significant regions of necrosis in our patient. The tumor remained viable at the small locations close to the periphery. These factors make cytological sampling using fine-needle aspiration biopsy more likely to be inadequate [8]. Thyroid tissue can be restored, nevertheless, by performing thyroidectomy and conducting thorough sampling [17]. The thyroid tissue in the area had undergone changes. There may be the presence of primary thyroid epithelial tumors or adenomatoid hyperplasia. A case of papillary thyroid cancer with head and neck angiosarcoma is described in the literature [18].

Vascular markers are used to distinguish it from other sarcomas and anaplastic thyroid cancer. TTF-1 and Thyroglobulin can also be used to identify surrounding thyroid or determine epithelial origin, whereas CD31, CD34, ERG, and factor VIII are more typically used as vascular markers [16]. The diagnosis of thyroid angiosarcoma is confirmed by the negative results of thyroglobulin, TTF1, and human cytokeratin [16]. The most precise and sensitive marker for the endothelium is CD31 [4] [14] [15] [19].

In our scenario, CD34 was negative and CD31 was positive [15]. Upon first diagnosis in the literature, it is common to observe invasion and metastasis in a significant number of cases [4] [14] [15]. Metastasis foci were present in the lymph nodes and lungs of our patient. Both macroscopic and microscopic examinations revealed an invasion into the adjacent soft tissue [4]. We found evidence of angioinvasion in our case studies in the literature have found that cases with angioinvasion were reported to have a poorer prognosis, and extrathyroidal invasion and metastasis were discovered to be poor prognostic indicators in a larger case series [15] [16]. Primary thyroid angiosarcoma is uncommon, hence there is no conventional therapy for it. One of the alternatives is radical surgery, and another is postoperative radiation [15].

Total thyroidectomy and neck dissection are the most often employed treatment modalities [14]. Invasion into the surrounding tissues might make the procedure more challenging and complicated. Vascular endothelial growth factor receptor (VEGFR) treatments are used, however further research is needed to determine their efficacy [14]. Total thyroidectomy and neck dissection are universally recognized as the most accepted types of treatment [14]. Invasion into the surrounding tissues might make the procedure more challenging and complicated. Anaplastic thyroid tumors are morphologically similar to primary thyroid angiosarcoma. A more frequent kind of anaplastic carcinoma exhibits distinct prognostic factors and requires a different treatment approach. In both types of cancer, TTF1 and thyroglobulin may be negative. We successfully excluded the presence of anaplastic cancer throughout the diagnostic process by utilizing the assistance of CD31 positive markers and morphological analysis [2].

4. Conclusion

It is of utmost importance to inform doctors and pathologists about rare thyroid

cancers. Although most thyroid cancers are primarily of epithelial origin, primary thyroid angiosarcoma is a rare occurrence. Pathological diagnosis can be made using histomorphological changes and immunohistochemistry staining. Increasing awareness of this issue among pathologists and clinicians is crucial for early diagnosis and accurate treatment, hence improving the likelihood of correct diagnosis and improving survival.

Conflicts of Interest

The author declares no conflicts of interest.

References

- [1] Jo, V.Y. and Fletcher, C.D. (2014) WHO Classification of Soft Tissue Tumours: An Update Based on the 2013 (4th) Edition. *Pathology*, **46**, 95-104. <https://doi.org/10.1097/PAT.000000000000050>
- [2] Kuhn, E., Ragazzi, M., Ciarrocchi, A., Torricelli, F., de Biase, D., Zanetti, E., Bisagni, A., Corrado, S., Uccella, S., La Rosa, S., Bongiovanni, M., Losito, S. and Piana, S. (2019) Angiosarcoma and Anaplastic Carcinoma of the Thyroid Are Two Distinct Entities: A Morphologic, Immunohistochemical, and Genetic Study. *Modern Pathology*, **32**, 787-798. <https://doi.org/10.1038/s41379-018-0199-z>
- [3] Wick, MR., Eusebi, V., Lamovec, J. and Ryska, A. (2017) Angiosarcoma. In: Lloyd, R.V., Osamura, R.Y., Klöppel, G. and Rosai, J., Eds., *WHO Classification of Tumors of Endocrine Organs*, IARC, 129-132.
- [4] Surov, A., Gottschling, S., Wienke, A., Meyer, H.J., Spielmann, R.P. and Dralle, H. (2015) Primary Thyroid Sarcoma: A Systematic Review. *Anticancer Research*, **35**, 5185-5191.
- [5] De Felice, F., Moscatelli, E., Orelli, S., Bulzonetti, N., Musio, D. and Tombolini, V. (2018) Primary Thyroid Angiosarcoma: A Systematic Review. *Oral Oncology*, **82**, 48-52. <https://doi.org/10.1016/j.oraloncology.2018.05.004>
- [6] Demirci, U., Demirci, A., Coşkun, U., Tufan, G., Ataoğlu, Ö., Demirci, B., *et al.* (2012) Tiroid Bezinin Metastatik Anjiosarkomu: Olgu Sunumu. *Acta Oncologica Turcica*, **45**, 56-58. <https://doi.org/10.5505/aot.2012.21931>
- [7] Huang, S.H. and Wu, S.C. (2020) Primary Angiosarcoma of the Thyroid in an Asian Woman: A Case Report with Review of the Literature. *Case Reports in Pathology*, **2020**, Article ID: 9068506. <https://doi.org/10.1155/2020/9068506>
- [8] Bayır, Ö., Yilmazer, D., Ersoy, R., Akca, Y., Saylam, G., Han, Ü., Özdek, A., Çakır, B. and Korkmaz, M.H. (2015) An Extremely Rare Case of Thyroid Malignancy from the Non-Alpine Region: Angiosarcoma. *International Journal of Surgery Case Reports*, **19**, 92-96. <https://doi.org/10.1016/j.ijscr.2015.12.028>
- [9] Ergül, G., Arik, D., Canpolat, S. and Albayrak, L. (2003) Primary Epitheloid Angiosarcoma of Thyroid Gland: A Case Report. *Turkish Journal of Pathology*, **19**, 74-75.
- [10] Meteoglu, I., Unal, E., Sen, S., Cetin, E.D. and Dirlik, M. (2010) A Case of Thyroid Angiosarcoma and Multiple Pleuropulmonary Metastasis Diagnosed at Autopsy. *Turkish Thoracic Journal*, **11**, 41-43.
- [11] Yilmazlar, T., Kirdak, T., Adim, S., Ozturk, E. and Yerci, O. (2005) A Case of Hemangiosarcoma in Thyroid with Severe Anemia Due to Bone Marrow Metastasis. *Endocrine Journal*, **52**, 57-59. <https://doi.org/10.1507/endocrj.52.57>

- [12] Altınay, S., Ozen, A., Namal, E. and Ertürküner, P. (2014) Electron Microscopic Analysis of an Angiosarcoma of the Thyroid from a Non-Alpine Endemic Goiter Region: A Case Report and Brief Review of the Literature. *Oncology Letters*, **8**, 2117-2121. <https://doi.org/10.3892/ol.2014.2470>
- [13] Doğan, L., Karaman, N., Irkkan, Ç., Kucuk, A. and Atalay, C. (2014) Angiosarcoma of the Thyroid and Regional Lymph Node Metastasis. *Journal of Clinical and Analytical Medicine*, **5**, 426-428.
- [14] Sapalidis, K., Kefes, N., Romanidis, K., Zarogoulidis, P., Pantea, S., Rogoveanu, O.C., Rogoveanu, I., Vagionas, A., Zarampouka, K., Tsakiridis, K. and Kesiosoglou, I. (2020) Thyroid Angiosarcoma-Rare Case or Hard to Find. *Current Health Sciences Journal*, **46**, 433-437.
- [15] Negură, I., Bădescu, M.C., Rezuş, C., Dănilă, R., Florescu, A.F., Blaj, M., Moroşan, E. and Apostol, D.G.C. (2021) Morphology and One Immunohistochemical Marker Are Enough for Diagnosis of Primary Thyroid Angiosarcoma. *Archive of Clinical Cases*, **8**, 7-13. <https://doi.org/10.22551/2021.30.0801.10178>
- [16] Bravaccini, S., Caprara, L., Cortecchia, S., De Lillo, M., Lega, S., Poli, F., Tasca, I., Vacirca, A., Cimatti, M.C., Tumedei, M.M., Ravaioli, S. and Puccetti, M. (2021) Primary Epithelioid Angiosarcoma of the Thyroid: A Case Report. *Cytopathology*, **32**, 519-522. <https://doi.org/10.1111/cyt.12954>
- [17] Couto, J., Martins, R.G., Santos, A.P., Matos, J. and Torres, I. (2014) Invasive Thyroid Angiosarcoma with a Favorable Outcome. *International Journal of Endocrinology and Metabolism*, **12**, e15806.
- [18] Lum, S.G., Mahmud, N., Isa, N. and Mat Baki, M. (2020) Concurrent Double Primary Tumours: Papillary Thyroid Carcinoma and Cervical Epithelioid Angiosarcoma. *Medeniyet Medical Journal*, **35**, 349-355.
- [19] Wiegand, S., Dietz, A. and Wichmann, G. (2021) Malignant Vascular Tumors of the Head and Neck-Which Type of Therapy Works Best? *Cancers*, **13**, Article 6201.