



# A Case Report on Left Paraduodenal Internal Hernia with Congenital Ladd's Bands

Sidharth Misra <sup>a,b,++\*</sup> and Sangram Karandiker <sup>a#</sup>

<sup>a</sup> Terna Speciality Hospital & Research Centre, India.

<sup>b</sup> Armed Forces Medical College, India.

## Authors' contributions

*This work was carried out in collaboration between both authors. Both authors read and approved the final manuscript.*

## Article Information

### Open Peer Review History:

This journal follows the Advanced Open Peer Review policy. Identity of the Reviewers, Editor(s) and additional Reviewers, peer review comments, different versions of the manuscript, comments of the editors, etc are available here: <https://www.sdiarticle5.com/review-history/117690>

Case Report

Received: 25/03/2024

Accepted: 26/05/2024

Published: 30/05/2024

## ABSTRACT

A 34-year-old male presented to the emergency department with complaints of sudden onset abdominal pain associated with nausea. He had similar complaints 2 months back which resolved spontaneously. Abdominal examination revealed tenderness in the periumbilical and the right lumbar region. These features were suggestive of sub-acute intestinal obstruction. The patient was diagnosed to have left paraduodenal hernia on contrast enhanced computed tomography. Jejunum and ileal loops were noted to be in the hernial sac. Surgical repair involved adhesiolysis of the bowel loops, reduction of the hernial sac contents and closure of the hernial defect. The patient had no post operative complications.

**Keywords:** Internal hernia; paraduodenal hernia; bowel adhesions; intestinal obstruction.

++ MBBS;

# Consultant Laparoscopic & General Surgeon;

\*Corresponding author: E-mail: [misra.sidharth.afmc@gmail.com](mailto:misra.sidharth.afmc@gmail.com);

**Cite as:** Misra, S., & Karandiker, S. (2024). A Case Report on Left Paraduodenal Internal Hernia with Congenital Ladd's Bands. *Asian Journal of Case Reports in Surgery*, 7(1), 286–291. Retrieved from <https://journalajcrs.com/index.php/AJCRS/article/view/538>.

## 1. INTRODUCTION

Internal hernias which account for 1% of all abdominal hernias, arise due to a defect in the mesentery or peritoneum leading to a protrusion of the abdominal viscera. [1,2] Multiple causes like anatomic, physiological and acquired causes have been identified [3-5]. The manifestations that are seen clinically range from mild digestive symptoms on one end of the spectrum to acute abdomen in the form of a closed-loop bowel obstruction on the other end of the spectrum [6,7]. The severity of clinical presentation depends on the duration, reducibility, presence or absence of strangulation, and incarceration [8]. Paraduodenal hernia (PDH) has been found to be the most common out of all, constituting 75% of all internal hernia cases [9,10]. It occurs when a part of the bowel prolapses through the Landzert's fossa which is located behind the fourth part of the duodenum. Furthermore, it is more common on the left than on the right [11,12]. Due to varied clinical presentations, a strong emphasis is placed on cross-sectional imaging like computed tomography (CT) scan for the diagnosis of PDH [13].

We present a case of a 34-year-old male with complaints of recurrent generalized abdominal pain with no surgical history. On imaging, jejunal and ileal loops were found in the hernial sac. Laparoscopic repair was made to reduce the

hernia which was later converted to open laparotomy due to dense adhesions.

## 2. CASE PRESENTATION

A 34-year-old male presented to the emergency department with complaints of sudden onset generalized abdominal pain. The abdominal pain was accompanied with nausea. He had similar complaints two months back that resolved spontaneously. The patient had normal bowel movements with the passage of flatus. He had no abdominal distension and no history of any abdominal surgery. On examination, he was in pain and his vital signs were stable. On abdominal examination, there was tenderness noted in the periumbilical and right lumbar region. There were no signs suggestive of peritonitis. Hyperactive bowel sounds were noted all over the abdomen. No external hernia, organomegaly, or palpable masses were noted.

Routine hematological investigations did not reveal any abnormality. The chest X-ray was normal and did not reveal free gas under the domes of the diaphragm. Contrast enhanced CT (CECT) scan of the abdomen was suggestive of sac-like mass with dilated small bowel loops between the stomach and pancreas in the left hypochondrium (Fig. 1). The sac containing a small bowel was displacing the transverse colon anteriorly and splenic flexure of the colon inferolaterally. These findings were suggestive of a left PDH.

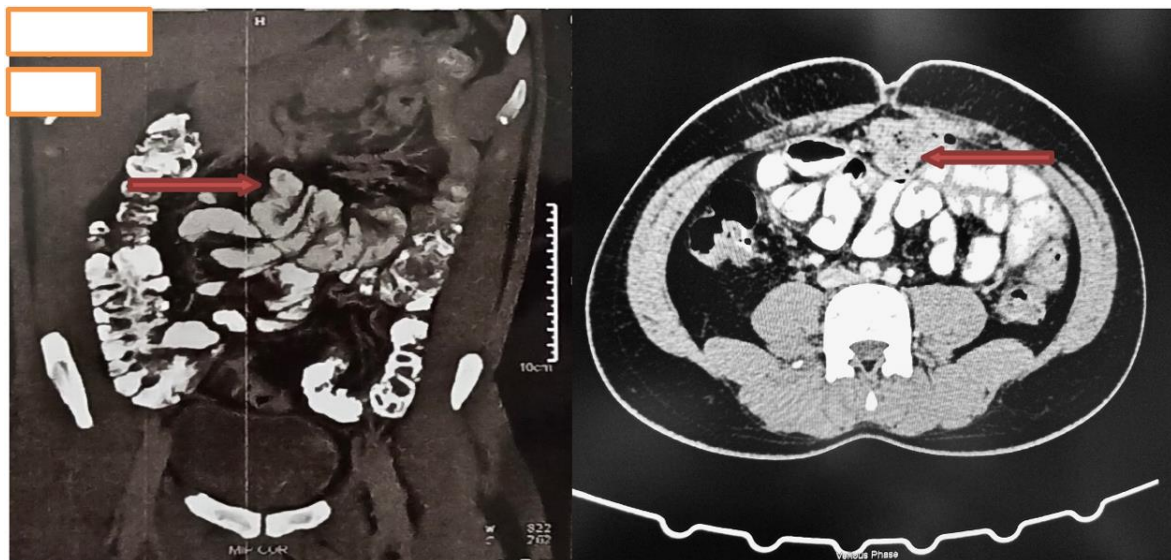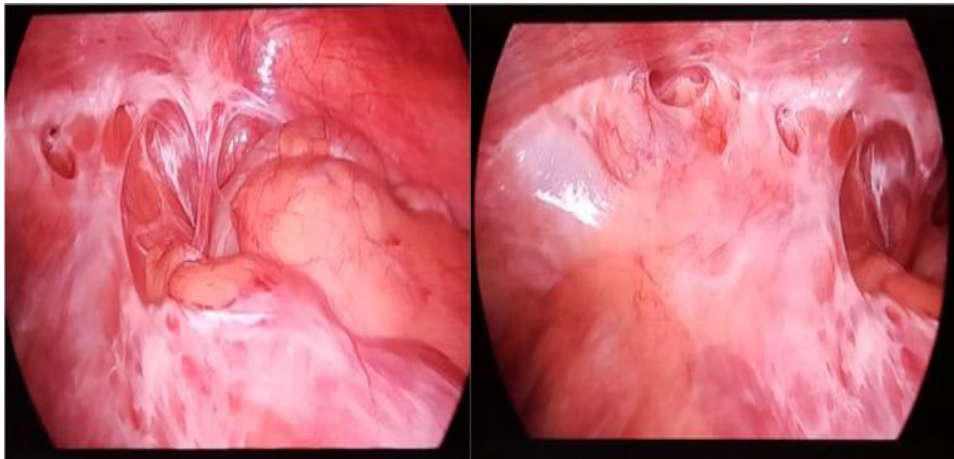


Fig. 1. Dilated small bowel loops (coronal & axial section)

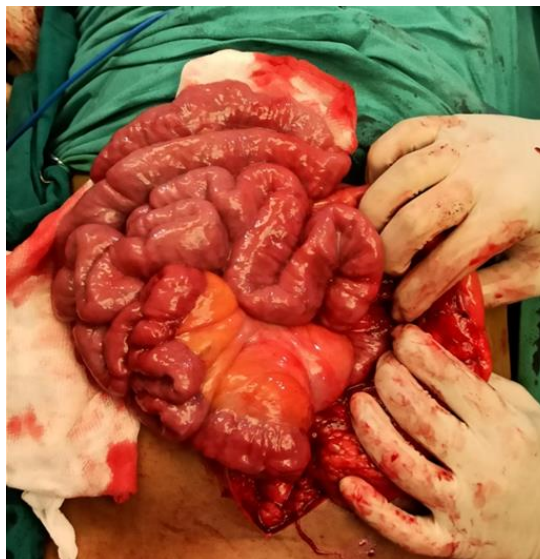The patient was in a supine position under general endotracheal anesthesia. The laparoscopy trolley was placed near the patient's left shoulder with the surgeon standing on the right side of the patient. The pneumoperitoneum was created by open technique with CO<sub>2</sub> of pressure 14 mmHg. Working ports were introduced one each along the midclavicular line in both pararectal regions. The diagnostic laparoscopy revealed cecum in the right iliac fossa with IC junction and terminal ileum, the rest of the small bowel could not be visualized. A thick sac-like structure with tense adhesions attached to the large intestine was seen in the central abdomen (Fig. 2). The anatomy could not be established laparoscopically; therefore, surgery was converted to laparotomy. The dissection was

started from IC junction and adhesiolysis revealed that all of the small intestine was seen entering through a defect on the left side of the duodenojejunal junction.

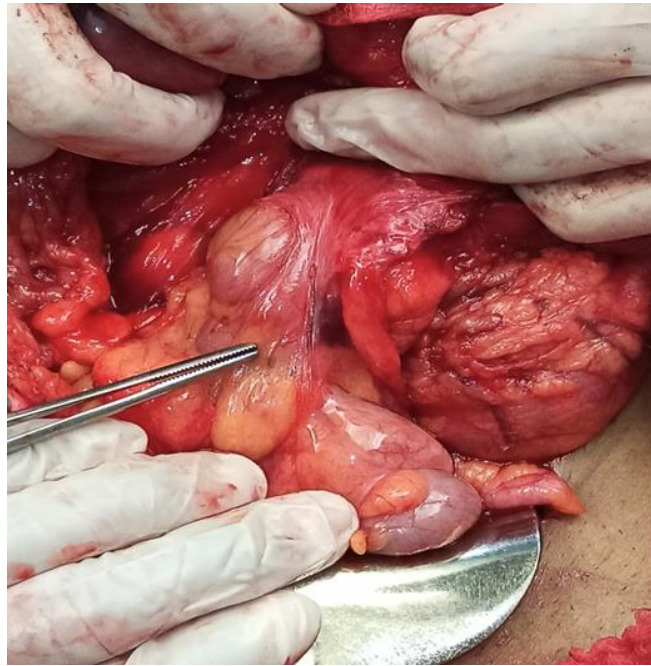The small bowel loops were delivered out of the hernial sac and inter bowel adhesions along the small intestine were divided. (Fig. 3) Upon inspection of the bowel loops, congenital Ladd's bands were noted. (Fig. 4) This established the anatomy of the small and large intestines which were further cleared of any residual bands or adhesions. The defect in the left mesocolon was repaired in two layers using 2-0 Mersilk sutures. (Fig. 5) Multiple bites through the left mesocolon, small bowel mesentery, and duodenum ensured complete closure of the hernial defect. The patient's post operative recovery was uneventful.



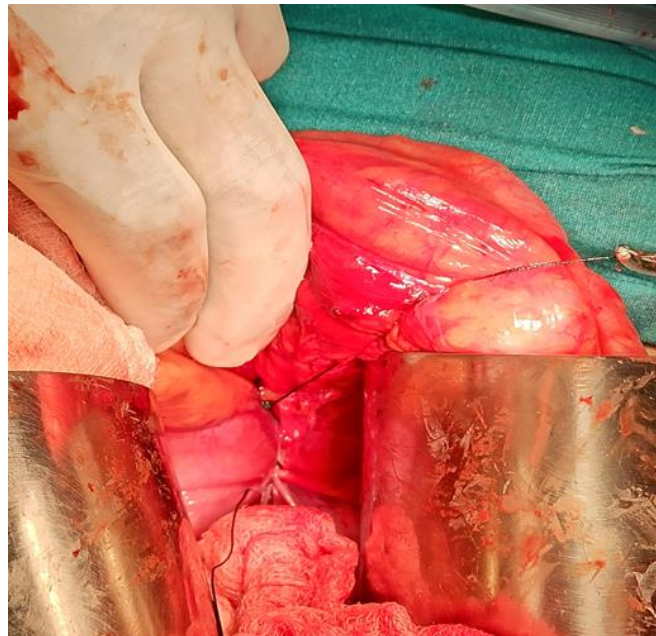
**Fig. 2. Adhesions noted laparoscopically**



**Fig. 3. Small bowel loops taken out of the hernial sac**



**Fig. 4. Congenital bands noted**



**Fig. 5. Hernial defect in the left mesocolon repaired with Mersilk 2-0**

### 3. DISCUSSION

Internal hernia is defined as a defect in the mesentery or peritoneum through which abdominal viscera protrudes [1]. Paraduodenal internal hernias constitute about 53% of all internal hernia cases. It occurs when the bowel loops get stuck in the colon's mesentery, thereby leading to obstruction [2]. They are more

frequently found in males than in females. It is of two types: left-sided which makes up 40% and right-sided which makes up 13%. Left-sided PDH mainly occurs through the Landzert's fossa which is in the left portion of the transverse mesocolon while the right sided PDH occurs when the bowel prolapses through the Waldeyer's fossa, a defect in the first part of the jejunal mesentery. [12].

Multiple theories have been postulated in the formation of PDH with a congenital origin. The most widely accepted theory is a physiological cause which includes defect in the rotation and fixation of the gut during embryological development. Anatomic causes including congenital bands, foramina, and fossa have also been identified as factors responsible for the development of PDH [3,4] Acquired causes include a past surgical history of gastric bypass surgery and liver transplantation [5]. The variability in clinical presentation and the rare number of cases make the diagnosis of PDH a diagnostic challenge. The clinical presentation ranges from mild digestive symptoms to acute intestinal obstruction [6]. The first case of PDH that was correctly diagnosed preoperatively was in 1921 by Kummer with the help of a barium study [14].

With modern imaging techniques, CECT is considered the gold standard method to diagnose PDH. On an abdominal CT, left PDH is seen as dilated bowel loops at the duodenal-jejunal junction between the stomach and pancreas at or above the level of the ligament of Treitz [13] It has been noted that these types of hernias have a 50% chance of progressing to complications like intestinal obstruction and strangulation and that is why early diagnosis and surgical management of the hernia is of utmost importance [14]

The surgical management mainly includes reduction of the hernial sac contents, restoration of the normal lie of small and large intestines, and closure of the hernial orifice to prevent recurrence [15]. Surgical management may be carried out laparoscopically or with an open approach. With recent advances in technology, such hernias can be managed by laparoscopic methods [16]. In our case, due to the dense adhesions and unclear anatomy, the patient was converted to open surgery.

We are presenting this case because it involves the diagnosis of a left PDH in a young patient, achieved through a high level of suspicion [17-19]. A timely investigation of CECT was crucial in accurately diagnosing the left PDH. Due to early detection, the patient underwent corrective surgery before experiencing any complications such as obstruction and strangulation. The surgical intervention was successful, and the patient had an uneventful recovery, highlighting the importance of early diagnosis and prompt treatment intervention.

#### 4. CONCLUSION

It is important to consider the diagnosis of a PDH in a case of recurrent abdominal pain presenting with or without features of acute intestinal obstruction. It is a condition that can be easily missed. CT scan has always been the gold standard modality in diagnosing internal hernias. Adhesiolysis, and establishment of normal anatomy of the bowel with the repair of hernial defect are most important steps to prevent recurrent pain and recurrence of hernia. In addition, the pathophysiological mechanism should be taken into consideration as in our case, congenital bands superimposed with a defect in malrotation led to the development of the paraduodenal hernia.

#### CONSENT

As per international standards or university standards, patient(s) written consent has been collected and preserved by the author(s).

#### ETHICAL APPROVAL

As per international standards or university standards written ethical approval has been collected and preserved by the author(s).

#### COMPETING INTERESTS

Authors have declared that they have no known competing financial interests or non-financial interests or personal relationships that could have appeared to influence the work reported in this paper.

#### REFERENCES

1. Ghahremani GG. Internal abdominal hernias. *Surg Clin North Am.* 1984 Apr;64(2):393-406. DOI: 10.1016/s0039-6109(16)43293-7.
2. Moshref LH, Alqahtani SH, Majeed ZA, Miro J. Left paraduodenal hernia: a rare cause of recurrent abdominal pain: case report. *Pan Afr Med J.* 2021;40:135. DOI: 10.11604/pamj.2021.40.135.32065.
3. Padhy BP. Congenital internal hernia a rare cause of acute intestinal obstruction. *Indian J Surg.* 2013;75(2):156-8. DOI: 10.1007/s12262-012-0506-8.
4. Kumar A, Ramakrishnan TS, Behl A, Sahu S, Singh G. Intestinal obstruction in a child: internal hernia caused by an anomalous

- congenital band. Trop Gastroenterol. 2010; 31(3):219-21.
5. Martin LC, Merkle EM, Thompson WM. Review of internal hernias: radiographic and clinical findings. AJR Am J Roentgenol. 2006 Mar;186(3):703-17. DOI: 10.2214/AJR.05.0644.
  6. Fan HP, Yang AD, Chang YJ, Juan CW, Wu HP. Clinical spectrum of internal hernia: a surgical emergency. Surg Today. 2008;38(10):899-904. DOI: 10.1007/s00595-007-3756-5.
  7. Takeyama N, Gokan T, Ohgiya Y, Satoh S, Hashizume T, Hataya K et al. CT of internal hernias. Radiographics. 2005; 25(4):997-1015. DOI: 10.1148/rg.254045035.
  8. Blachar A, Federle MP. Internal hernia: an increasingly common cause of small bowel obstruction. Semin Ultrasound CT MR. 2002 (2):174-83. DOI: 10.1016/s0887-2171(02)90003-x.
  9. Jain SK, Kaza RC, Garg PK. Incidental congenital transmesenteric hernia in an adult. Eur Rev Med Pharmacol Sci. 2011;15(4):461-2.
  10. Blachar A, Federle MP, Dodson SF. Internal hernia: clinical and imaging findings in 17 patients with emphasis on CT criteria. Radiology. 2001;218(1):68-74. DOI:10.1148/radiology.218.1.r01ja5368
  11. Xu H, Nie N, Kong F, Zhong B. Large left paraduodenal hernia with intestinal ischemia: a case report and literature review. J Int Med Res. 2020;48(9): 300060520955040. DOI: 10.1177/0300060520955040.
  12. Okino Y, Kiyosue H, Mori H, Komatsu E, Matsumoto S, Yamada Y et al. Root of the small-bowel mesentery: correlative anatomy and CT features of pathologic conditions. Radiographics. 2001;21(6): 1475-90. DOI:10.1148/radiographics.21.6.g01nv121475
  13. Lanzetta MM, Masserelli A, Addeo G, Cozzi D, Maggialetti N, Danti G et al. Internal hernias: a difficult diagnostic challenge. Review of CT signs and clinical findings. Acta Biomed. 2019;90(5-S):20-37. DOI: 10.23750/abm.v90i5-S.8344.
  14. Assenza M, Rossi D, Rossi G, Reale C, Simonelli L, Romeo V et al. Laparoscopic management of left paraduodenal hernia. Case report and review of literature. G Chir. 2014;35(7-8):185-9.
  15. Titan AL, Garagliano JM, Spain D. Management of an internal hernia through the foramen of Winslow. Trauma Surg Acute Care Open. 2022;7(1):e000960. DOI: 10.1136/tsaco-2022-000960.
  16. Facchiano E, Soricelli E, Lucchese M. Laparoscopic Management of Internal Hernia After One Anastomosis Gastric Bypass (OAGB). Obes Surg. 2020;30(10): 4169-4170. DOI: 10.1007/s11695-020-04791-y.
  17. Jatal SN, Jatal S, Ingle S. Transmesenteric Internal Hernia Presenting with Strangulation of Bowel in Adult- A Case Report. Asian J. Res. Surg. [Internet]. 2023 Sep. 18 [cited 2024 May 16];6(2):240-4. Available:https://journalajrs.com/index.php/AJRS/article/view/161
  18. Messaoudi IE, Laalou A, Aragon O, Chtaibi K, Njoumi N, Ali AA. Left Paraduodenal hernia: Rare cause of acute intestinal obstruction. Asian J. Case Rep. Surg. [Internet]. 2024 Jan. 17 [cited 2024 May 16];7(1):13-6. Available:https://journalajcrs.com/index.php/AJCRS/article/view/490
  19. Al Laham O, Albrijawy R, Ahmad I, Atia F, Shaheen J, Aldeen BA. A distinctive case of congenital midgut malrotation with volvulus in an adolescent female managed by Ladd's procedure-A case report. International Journal of Surgery Case Reports. 2022 Jan 1;90: 106752.

© Copyright (2024): Author(s). The licensee is the journal publisher. This is an Open Access article distributed under the terms of the Creative Commons Attribution License (<http://creativecommons.org/licenses/by/4.0>), which permits unrestricted use, distribution, and reproduction in any medium, provided the original work is properly cited.

*Peer-review history:*

The peer review history for this paper can be accessed here:

<https://www.sdiarticle5.com/review-history/117690>