



# Percutaneous Intervention for a Stuck Mechanical Prosthetic Valve at Mitral Position as a Bailout Procedure in a High Surgical Risk Candidate

Salman Shaikh <sup>a</sup>, Kalyan S. Munde <sup>a\*</sup> and Anagh T. S. <sup>a</sup>

<sup>a</sup> Grant Govt. Medical College and Sir JJ Group of Hospitals Mumbai, India.

## Authors' contributions

This work was carried out in collaboration among all authors. All authors read and approved the final manuscript.

## Article Information

DOI: 10.9734/CA/2023/v12i4375

## Open Peer Review History:

This journal follows the Advanced Open Peer Review policy. Identity of the Reviewers, Editor(s) and additional Reviewers, peer review comments, different versions of the manuscript, comments of the editors, etc are available here: <https://www.sdiarticle5.com/review-history/108188>

Case Report

Received: 23/08/2023

Accepted: 28/10/2023

Published: 31/10/2023

## ABSTRACT

Mechanical heart valves are the preferred choice for younger individuals when the native valves cannot undergo repair, primarily due to their exceptional durability. It is crucial to meticulously manage the international normalized ratio (INR) within the range of 2.5 to 3.5 to ensure optimal valve function and minimise the risk of thromboembolic complications. Our case report serves to demonstrate the effectiveness of percutaneous balloon dilatation through transcatheter methods as an innovative and promising approach to release a stuck valve, representing a noteworthy addition to the spectrum of treatment options.

**Keywords:** Mechanical heart valves; international normalized ratio; surgical replacement; prosthetic valve thrombosis.

\*Corresponding author: E-mail: kalyanmunde@yahoo.com;

## 1. INTRODUCTION

Despite comprehensive patient education on mechanical valve maintenance and recommended lifestyle changes provided in dedicated valve clinics, many patients still experience leaflet dysfunction, resulting in valve obstruction. In such cases, the sole viable option is to perform surgical replacement of the valve [1].

Prosthetic valve thrombosis (PVT) is a serious complication that may cause significant morbidity and mortality [2]. In certain instances, off-label thrombolysis has shown promise as an alternative treatment approach. This case report focuses on demonstrating the safety and feasibility of a percutaneous, transseptal, transcatheter method for releasing stuck mechanical valves at the mitral position.

## 2. CASE PRESENTATION

47-year-old female, homemaker presented with progressive dyspnoea on exertion, NYHA Class III. She is a known case of Rheumatic heart disease with ostium secundum atrial septal defect (left to right shunt) who had undergone prosthetic mitral valve replacement (St Jude Bileaflet Metallic valve no 23 valve) with ASD patch closure and Left atrial appendage ligation in 2012. She previously had undergone redo cardiac surgery and clot removal for the stuck mitral valve in 2013. She was regularly taking oral anticoagulant (Tab Warfarin 5 mg once a day) with INR values within the therapeutic range i.e. 2.5-3.5.

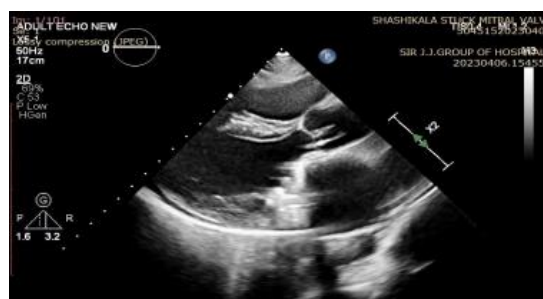On examination Pulse 84 beats/ min, regular, BP - 114/70 mmHg. Cardiovascular system examination is suggestive of normal heart sounds with absent metallic click and normal respiratory examination.

On Investigation ECG had normal sinus rhythm with non-specific ST-T changes. 2D Echo shows a significant gradient across the prosthetic mechanical mitral valve which values Peak/Mean 43/25 mmHg respectively with restricted one leaflet movement and good left ventricular function (Figs. 1, 2, and 3).

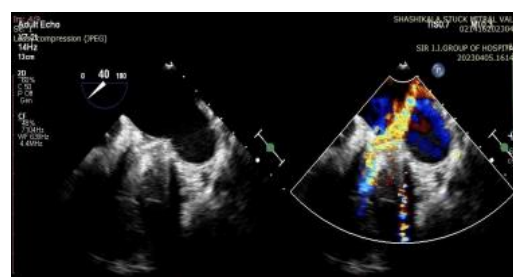
On fluoroscopy, the prosthetic bileaflet valve at the mitral position revealed one leaflet stuck and one mobile. On transesophageal echocardiography, there was no evidence of left atrial clot, and no thrombus on the valve but a

pannus was present. Cardiac CT shows a stuck mitral anterior leaflet in the closed position and circumferential hyper attenuated soft tissue at the mitral annulus along the atrial aspect suggestive of pannus.

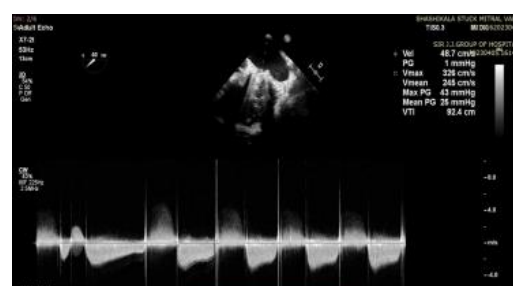
She was advised to undergo redo mitral valve replacement but denied to give consent for surgery.



**Fig. 1. Transthoracic echocardiography of partially stuck mitral valve prosthesis (PLAX view)**



**Fig. 2. Transesophageal echocardiography of partially stuck mitral valve prosthesis**



**Fig. 3. Continuous wave Echocardiography of partially stuck mitral valve prosthesis (Peak/Mean - 43/25 mmHg), V max – 3.26 m/s**

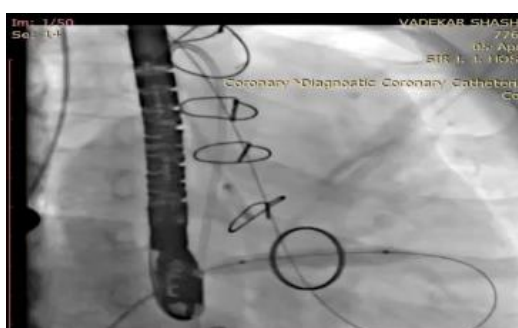## 3. PROCEDURE

Under local anaesthesia with ultrasonographic guidance right femoral artery and vein access obtained. MPA catheter passed in the pulmonary

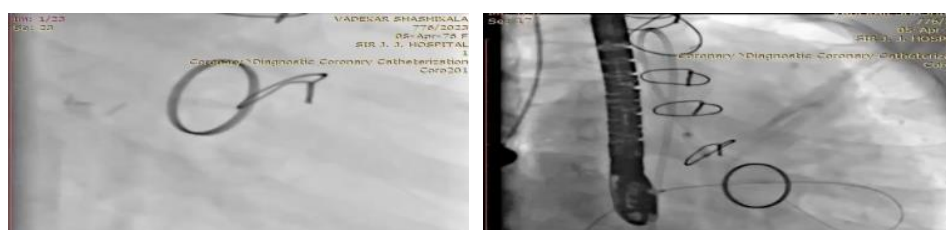artery and PA pressure was taken which was (64/26 mmHg). Over 0.032 wire, Mullin sheath passed in RA. Septal puncture was done with Brockenbrough needle. After the septal puncture, the Zolbi wire passed into LA. Heparin was given and ACT was maintained around 250 sec. Septal dilatation done over zolbi wire. Mullins kept at stuck leaflet orifice. Then 0.014 wire tried to cross through the orifice between the stuck leaflet but failed to cross. After that 0.032 soft wire crossed between the stuck leaflets of the mitral prosthetic valve successfully. The distance between the two hinges was calculated which came to be 4mm. Hence BARD balloon of size 4x40 mm was chosen and two serial balloon dilatations were done (Fig. 4). Release of stuck valve with good occluder movement and fall in transmitral gradient observed (Figs. 5A,5B and 6). The patient was vitally stable, shifted to ICCU. Later on discharged with regular INR monitoring.

**Table 1. Detailed report of patient**

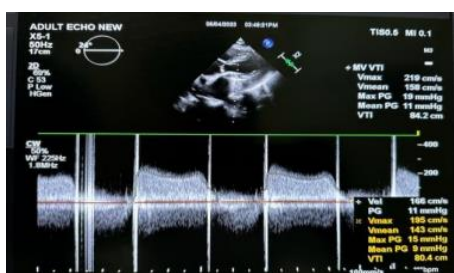
Patient details	
Age (years)	47
Sex	Female
Weight(kg)	55
Height(cm)	150
BSA(m <sup>2</sup> )	1.51m <sup>2</sup>
Valve name and size	St Jude no.23
Radio opacity of ring	Radio opaque
Radio opacity of disc	Radio opaque
Age of the valve	10 years
INR during stuck valve	2.42
Clinical presentation	NYHA III DOE
Thrombolysis before procedure	No
Echocardiogram	
a. Pre-procedure gradient(peak/mean)	43/25 mmHg
a. Post procedure gradient(peak/mean)	15/9 mmHg
a. Pannus	Yes
a. LVEF	60
a. Pre pulmonic artery systolic pressure(mmHg)	64/26
a. Post pulmonary artery systolic pressure(mmHg)	42/14
a. Rhythm at presentation	Sinus rhythm
a. Wire	0.032 wire
a. Balloon	BARD balloon 4x40mm
a. Cerebral protection	No



**Fig. 4. Balloon inflation done across the prosthetic mitral valve to release the stuck leaflet**



**Fig. 5A,5B. Release of stuck mitral valve post balloon inflation**



**Fig. 6. Post procedure ECHO: Peak/Mean Gradient reduced to 15/9 mmHg**

## 4. RESULTS

While the conventional approach to treatment has historically involved surgical methods, recent investigations into the use of thrombolytic agents administered at low doses and slow infusion rates have yielded promising outcomes among patients with similar conditions. It is important to emphasize that surgical intervention remains the preferred choice, particularly for patients presenting with left atrial thrombus, active bleeding or those requiring immediate treatment within the initial four days following valve replacement. However, considering the significantly increased risks associated with redo surgery in this context, an alternative strategy was explored. In this case, an attempt was made to address the issue through transcatheter techniques designed to release the mechanical mitral valve leaflet that had become immobilized [3].

## 5. DISCUSSION

The utilization of high-risk, urgent surgery is regarded as a last-resort solution when dealing with a stuck valve. It's important to acknowledge that the mortality risk associated with surgery significantly escalates when patients find themselves in NYHA class III-IV. Within the realm of interventional procedures, it is a fundamental teaching principle to exercise caution when attempting to navigate across a mechanical valve, as there exists a notable risk of wire or catheter entrapment [4]. In the majority of cases, safe crossing of valves can be achieved with careful and gentle manipulations, except for certain valve types such as the Bjork Shiley valve, which presents unique challenges. Notably, Vuppaladadhiam Hariram has successfully conducted percutaneous interventions in five instances of mitral prosthetic valve thrombosis, yielding favourable outcomes. This procedure involved the conventional approach of transseptal puncture, positioning the Mullen's sheath toward the mitral valve, and using a Terumo wire to navigate across the valve. Subsequently, employing a catheter for Dottering proved sufficient to restore proper valve movement in all five cases, highlighting the effectiveness of this technique [5].

Jabbour et al. [6] reported a case of acute prosthetic aortic valve obstruction who was treated by percutaneous manipulation of the valve with a rigid catheter, following which partial valve mobility was established.

Our case report serves to demonstrate the effectiveness of percutaneous balloon dilatation through transcatheter methods as an innovative and promising approach to release a stuck valve, representing a noteworthy addition to the spectrum of treatment options. In line with this, Chen et al.<sup>3</sup> have previously reported successful percutaneous transcatheter release of a stuck mechanical mitral valve leaflet using a series of balloon dilations, ranging from 1-mm to 5-mm coronary balloons. In our case, we achieved the successful release of the stuck valve through serial balloon dilatation, with the leaflets remaining securely anchored at their hinge points without any avulsion. This notably obviated the need for major surgical intervention. Importantly, we did not employ a cerebral protection device, given that the issue leading to the stuck valve was attributed to pannus, and also due to financial constraints faced by the patient. As of the latest follow-up, our patient remains symptom-free and is regularly monitored while receiving oral anticoagulation therapy, indicative of a favourable clinical outcome.

## 6. CONCLUSION

Individuals with an elevated risk of requiring a repeat surgical procedure may find that the transcatheter balloon dilatation technique offers a novel and promising therapeutic avenue for addressing valve obstructions.

The introduction of innovative medical procedures such as transcatheter balloon dilatation is promising in improving healthcare accessibility, especially in less affluent regions, by diminishing the necessity for high-risk surgeries and potentially cutting down treatment expenses.

However, further comprehensive trials are essential to validate the safety and effectiveness for these procedures. Additionally, such studies can help identify specific patient groups who would be suitable candidates for this innovative treatment.

## 7. LIMITATIONS

We did not employ a cerebral protection device, given that the issue leading to the stuck valve was attributed to pannus, and also due to financial constraints faced by the patient.

The long-term outcome and effectiveness of this transcatheter technique are not known.

## CONSENT

Patient consent for publication has been obtained by the authors.

## ETHICAL APPROVAL

As per international standards or university standards written ethical approval has been collected and preserved by the author(s).

## COMPETING INTERESTS

Authors have declared that no competing interests exist.

## REFERENCES

1. Kalidoss L, Nandhakumar V, Subban V, Ajit MS. Percutaneous intervention for stuck mechanical valve leaflets at mitral position. *Structural Heart*; 2021. DOI: 10.1080/24748706.2021.1927273
2. Cevik C, Izgi C, Dechyapirom W, Nugent K. Treatment of prosthetic valve thrombosis: rationale for a prospective randomized clinical trial. *Journal of Heart Valve Disease*. 2010; PMID: 20369498.
3. Chen Y, Waksman R, Satler L, Barnett C, Chen A, Rogers T. Percutaneous transcatheter release of stuck mechanical mitral valve leaflet. *European Heart Journal*. 2020;41(41):4072. DOI: 10.1093/eurheartj/ehaa228. PMID: 32311024.
4. Nanjappa V, Raveesh H, Sadanand KS, Manjunath CN. Case report: Percutaneous intervention for a mechanical prosthetic valve thrombosis as a bailout procedure. *Indian Heart Journal*; 2023. Available:10.1016/j.ihjccr.2023.05.003
5. Hariram V. Percutaneous management of prosthetic valve thrombosis. *Indian Heart Journal*; 2014. Available:10.1016/j.ihj.2014.05.008. PMID: 25173201. PMCID: PMC4150042.
6. Jabbour S, Salinger M, Alexander JC. Hemodynamic stabilization of acute prosthetic valve thrombosis using percutaneous catheter manipulation. *Case Reports in Catheterization and Cardiovascular Diagnosis*; 1996. Available:10.1002/(SICI)1097-0304(199611)39:3<314::AID-CCD24>3.0.CO;2-D. PMID: 8933982.

© 2023 Shaikh et al.; This is an Open Access article distributed under the terms of the Creative Commons Attribution License (<http://creativecommons.org/licenses/by/4.0>), which permits unrestricted use, distribution, and reproduction in any medium, provided the original work is properly cited.

*Peer-review history:*

*The peer review history for this paper can be accessed here:*  
<https://www.sdiarticle5.com/review-history/108188>