



## **A 7-year Follow up of a Solitary Cyst on the Mandibular First Premolar: A Case Report**

**Hassan Dib <sup>a\*</sup>, Said Halabi <sup>a</sup>, Georges Aad <sup>b</sup> and Antoine Berberi <sup>a</sup>**

<sup>a</sup> *Department of Oral and Maxillofacial Surgery, Faculty of Dental Medicine, Lebanese University, Hadath, Beirut, Lebanon.*

<sup>b</sup> *Department of Oral Medicine and Maxillofacial Radiology, Faculty of Dental Medicine, Lebanese University, Hadath, Beirut, Lebanon.*

### **Authors' contributions**

*This work was carried out in collaboration among all authors. Authors HD and SH helped in Clinical examination. Author HD completed the surgical work. Authors HD, SH and AB wrote, reviewed and edited the manuscript. All authors read and approved the final manuscript.*

### **Article Information**

DOI: 10.9734/JAMMR/2021/v33i2431235

### **Open Peer Review History:**

This journal follows the Advanced Open Peer Review policy. Identity of the Reviewers, Editor(s) and additional Reviewers, peer review comments, different versions of the manuscript, comments of the editors, etc are available here: <https://www.sdiarticle5.com/review-history/80409>

**Case Report**

**Received 21 October 2021**

**Accepted 23 December 2021**

**Published 25 December 2021**

## **ABSTRACT**

**Aims:** The principal goal of the following case report is to shed light on the importance of thorough clinical, radiological and histological examinations in order to exhibit a final diagnosis of solitary bone cyst, as well as the importance of the surgical treatment for a better outcome.

**Presentation of case:** A case of solitary cyst was identified accidentally in the mandibular right premolars' region of an asymptomatic 14-year-old male patient post orthodontic consultation. Panoramic radiograph revealed a well-circumscribed, unilocular, radiolucent area giving a typical scalloped appearance between the roots of the involved teeth, that is, 43–44 (Federation Dentaire Internationale). The lesion was asymptomatic and no cervical lymphadenopathy was detected.

**Discussion:** Solitary bone cysts are infrequent mandibular cavities lacking epithelial coating and that are most commonly found in the posterior region of the lower jaw. They exhibit multiple names such as traumatic bone cyst, hemorrhagic bone cyst, extravasation cyst, progressive bone cavity and single chamber bone cyst. Solitary bone cysts are usually asymptomatic but may cause bone deformities, teeth displacement as well as pathological fractures of the affected region. Solitary bone cyst, also found in other skeletal locations, is often suspected after epidemiologic and radiologic test results and confirmed at surgery.

**Conclusion:** In solitary bone cysts cases, undoubtedly, the determinant factor is surgical exploration of the lesion, although its clinical characteristics and scientific literature descriptions must be borne in mind as well as the fact that histological and radiographic characteristics are important to sustain accurate diagnosis. Since etiology of these cysts is unknown to the present date, it can only be intuited according to personal characteristics of each patient. The most accepted theory suggested a traumatic origin for these lesions. Nevertheless, when trauma is discarded as etiologic factor, the most accepted theory would be related to calcium metabolism alterations associated to the overall condition of our patient.

**Keywords:** *Mandibular cyst; solitary bone cyst; traumatic bone cyst; simple bone cyst; hemorrhagic bone cyst.*

## 1. INTRODUCTION

Solitary bone cysts are rare mandibular cavities lacking epithelial coating [1] and that are more common in the posterior region of the lower jaw [2]. These cysts, that were previously described [3], exhibit various names including traumatic bone cyst, hemorrhagic bone cyst, extravasation cyst, progressive bone cavity and single chamber bone cyst [2].

Solitary bone cysts were found to be more prevalent in young patients aged between 20 and 30 years [4] with males (60%) being most affected [5]. Moreover, these cysts were found to be present in different locations including lower jaw (75% in the body of the mandible), mandibular symphysis, condyles, ramus and upper jaw [6;7].

Clinically, the lesion is asymptomatic without any inflammation [8]. Moreover, it was shown that lesion size can cause displacement of the cortical plates thus leading to bone deformities in the affected region in addition to its ability to cause teeth displacement as well as pathological fractures of the lower jaw [9].

Bone cysts are usually discovered accidentally during routine maxillary-mandibular region radiographic examinations [9]. Generally, radiographic findings show osteolysis areas with irregular unilocular or multilocular appearance with well-defined borders and without sclerotic lining [10]. Moreover, these cysts were found to appear as horizontal or vertical cone when located between teeth whilst in larger lesions, a festoon/scalloping pattern was observed in interdental spaces in conjunction with cortical bone plates expansion [5,11]. On the other hand, tomography and magnetic resonance studies showed that simple bone cysts can be filled with liquid, gas or even be empty [8;12].

The etiology of simple bone cysts is still controversial. However, the theory of the mediated trauma is one of the preponderant theories [8,13]. Actually, different treatment modalities were suggested and prognosis and recurrence of the lesion were found to be different according to the treatment done [14,15].

The following case report presents a 7-year follow up of a simple bone cyst in the body of the mandible at the right site of canine and first premolar, managed by enucleation and surgical curettage in a 14-year-old boy.

## 2. PRESENTATION OF CASE

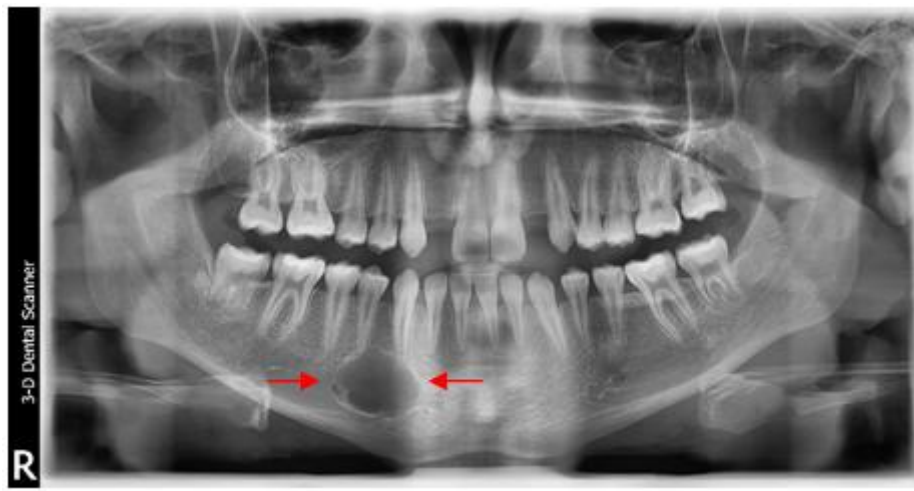
A 14-year-old boy was referred by his orthodontist to our private clinic, located in Beirut-Lebanon, due to the presence of a radiolucent lesion at the right side of the body of the mandible. The latter was discovered during a radiographic examination prior to the orthodontic treatment of the agenesis in the maxillary lateral incisors. At the time of his visit, the patient was asymptomatic, lacking any systemic diseases, and with no facial asymmetry. The patient had only a dental agenesis of the maxillary lateral incisors.

The clinical examination revealed normal oral structures and did not detect any intraoral bony swelling in the vestibule of the right mandibular area. The overlying mucosa did not show any inflammatory signs. On palpation, there was no evidence of cortical bones' expansion. There was no history of trauma of the jaws. The patient was in his early permanent dentition. Resin composite restorations were evident on the occlusal surfaces of the second premolars and first molars in both quadrants of the mandibular jaw.

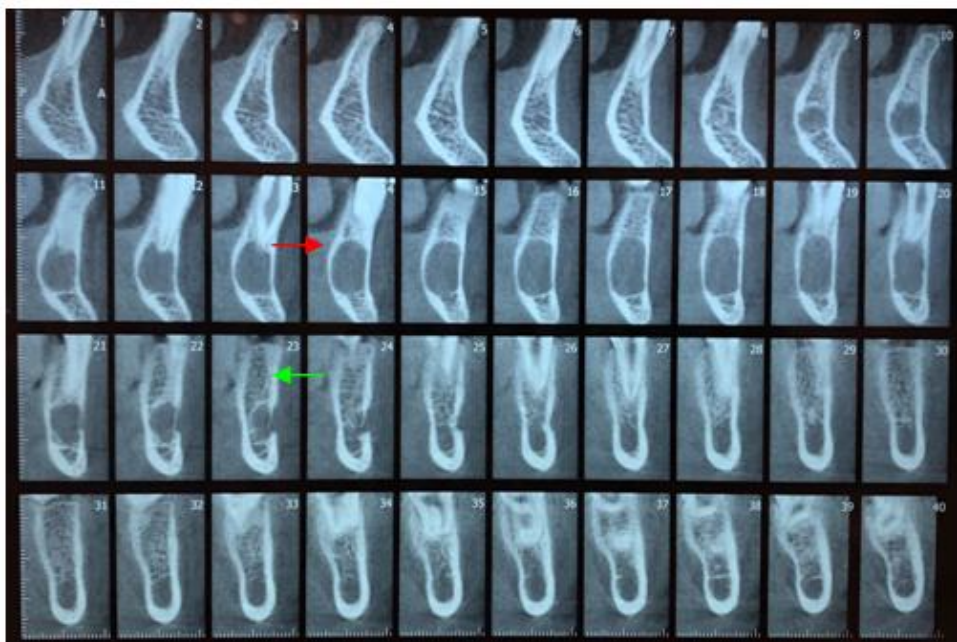
An extensive range of investigations were carried out. An orthopantomography (OPG) was carried out 2 weeks before the surgery to confirm the

extent of the cystic lesion. It revealed a well-circumscribed, unilocular, radiolucent area located in the body of the mandible at the right site of the canine and first premolar with a typical scalloped shape between the roots of the concerned teeth and with a diameter of approximately 2.0x2.0 cm (Fig. 1). The lesion was asymptomatic with no cervical lymphadenopathy being observed. The involved teeth showed no mobility and responded positively to electric and thermal pulp vitality

tests. A cone beam computed tomography (CBCT) confirmed a well-defined hypodense cystic lesion in the alveolar cortex of the mandible in the region of the right canine and first premolar, measuring approximately 2.0x2.0 cm and including the mental nerve (Fig. 2). Differential diagnosis included central giant granuloma of traumatic or endocrinological etiology, aneurysmal bone cyst, and hemangioma.



**Fig. 1. Pre-operative orthopantomography taken in 2014, showing a well-defined unilocular radiolucent lesion (red arrows) approximating the root of the mandibular right canine and first premolar**

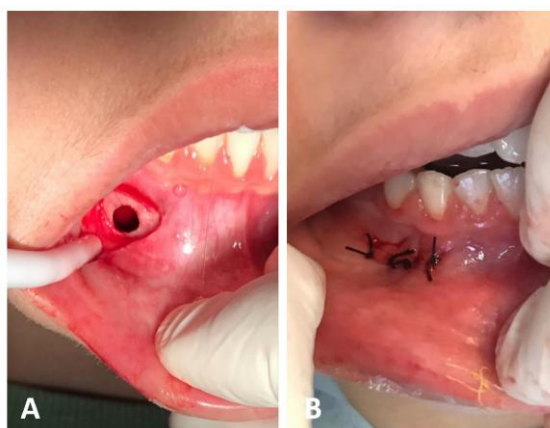


**Fig. 2. Pre-operative CBCT taken in 2014 confirming a well-defined hypodense cystic lesion in the alveolar cortex of the mandible at the site of the right premolar measuring approximately 2.0x2.0 cm (red arrow) and including the mental nerve (green arrow)**

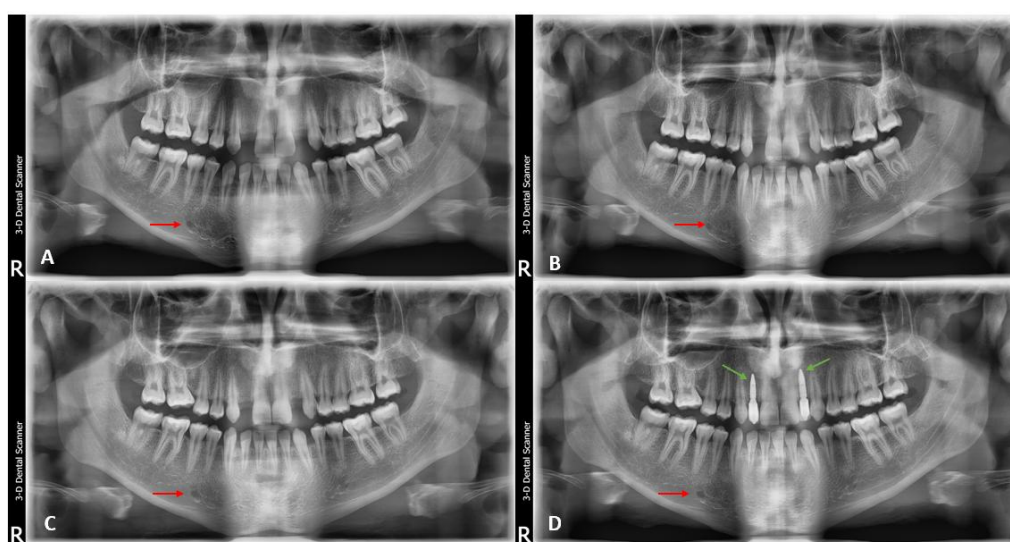
## 2.1 Treatment

With informed consent, and under local buccal and lingual infiltration using articaine with epinephrine 1/100000, an intrasulcular incision was made extending from the mesial side of the first permanent molar to the mesial side of the lateral of the same quadrant. A vertical discharge was done at the level of the lateral tooth with an elevation of the mucoperiosteal flap which allowed the exposure of the mental nerve foramen as well as the buccal bone which appeared fragile and thinned out. No evidence of

bony expansion was noted. A window was made with a surgical piezo (EMS) and a round diamond bur to access the lesion (Fig. 3A). The bony cavity was filled with liquid content of bloody appearance, devoid of epithelial lining. Cavity walls' surgical curettage was performed using Lucas curette #85-85 excluding the roof to preserve the vitality of the involved teeth. Copious irrigation using normal saline was done and the surgical site was closed and sutured using 4.0 simple interrupted silk sutures (Silkam, Broun) (Fig. 3B).



**Fig. 3. (A) Per-operative clinical photograph showing a window (green arrow) done in the buccal cortex to gain access to the lesion. (B) Post-operative clinical photograph taken after suturing the flap with simple interrupted sutures (blue arrow)**



**Fig. 4. (A) 1-year post-operative orthopantomography taken 2015 showing complete bone formation (red arrow) in the area of the excised lesion; (B and C) follow-up orthopantomography taken in 2016 and 2017 respectively showing complete healing (red arrows); (D) Orthopantomography taken in 2019, showing complete healing in the area of excised lesion (red arrow) as well as two implant supported crowns restoring the missing maxillary lateral incisors (green arrows)**

## 2.2 Outcome and Follow-up

Postoperatively, antibiotics (amoxicillin 500 mg, twice daily for 7 days) together with analgesics and anti-inflammatory medications (ibuprofen 300 mg, three times a day for 5 days) were provided. Local cold application and home oral care instructions were advised. The post-operative phase went smoothly. Patient follow up then pursued for seven years. A panoramic radiograph follow-up taken after approximately 1-year showed resolution of the lesion with complete bone formation (Fig. 4 A). Further panoramic radiographs were taken every year and so following the treatment and none revealed any abnormal findings at the site of the lesion (Fig. 4 B, C). Mandibular teeth had remained, each follow-up visit, responsive to pulp vitality tests. Five years after the surgery, two fully milled zirconia crowns supported by bone level tapered implants (Straumann, Germany) of a 3,3mm diameter and 10mm length were placed to restore the missing maxillary lateral incisors (Fig. 4 D).

## 3. DISCUSSION

Solitary bone cysts have a controversial etiopathogenesis. Cystic degeneration of fibro-osseous lesions, intraosseous vascular anomalies, deregulation of bony metabolism and low infection level were the main suggested etiologies [1,16]. The most common justification implies that liquefactive necrosis or blood clot resorption post traumatic intramedullar hemorrhage leads, as a result of enzymatic activity, to the damage of the surrounding bone and thus enlarging the bone cavity [16,17]. However, variations concerning the presence of traumatic history in the majority of reported cases can serve as a limitation to this theory [16].

Our patient had no trauma history thus hindering the establishment of a principal etiological factor. Solitary bone cysts have no epithelium and exhibit radiographically cystic appearance [4]. They are more prevalent in young male patients' lower jaw [4]. Cystic cavity may be empty or filled with gas or blood. The content of the cavity might be related to the duration of existence of the cyst [1,18]. In early stages, the lesion usually contains either blood or serosanguineous fluid diminishing with the lesion's age and eventually becoming empty [2]. Treatment of solitary bone cysts can be mediated by curettage of the cystic wall, exploration of the cystic cavity and addition of filling material to the cavity. The first treatment

modality was the most commonly used [15]. Resolution typically takes up to 6 months or longer, depending on the size of the lesion [19]. Recurrence of the lesion is usually rare and was more observed in cases treated with simple lesion curettage.

Decompression together with the addition of the filling material within the cystic cavity play an important role in decreasing the recurrence rate [9]. For this reason, a minimum of two-year follow-up is recommended to be able to determine cystic lesion remission or recurrence [19]. The differential diagnosis of the jaw solitary bone cysts includes odontogenic cysts, such as periapical cyst, and odontogenic tumors, like keratocystic odontogenic tumor [20].

The case described in this report presented clinical data complying with previous literature. Our patient carrying an asymptomatic lesion discovered incidentally during a radiographic examination prior to an orthodontic treatment. The conducted treatment was surgical enucleation and curettage with copious irrigation and cleaning of the cystic cavity without adding any filling material. One-year radiographic follow-up showed a decrease in the cystic lesion size and a better trabeculated pattern in lower jaw areas which are considered as favorable results. No evidence of recurrence was detected 7 years post treatment.

## 4. CONCLUSION

A solitary bone cyst is an osseous non-neoplastic asymptomatic lesion that is usually incidentally identified during routine radiological examination. It is characterized by the absence of epithelial lining with a scalloped effect around the roots of the concerned teeth. Multiple treatment modalities were advocated where surgical curettage was the most commonly used since it helps in diagnosis confirmation. A three-year span follow up, coupled with radiographic imagining, must be conducted up in order to determine remission or recurrence rate. The remission of solitary bone cyst will be more reliable when suitable trabecular bone is observed and not only when we have decrease in the cystic cavity.

## CONSENT

Written informed consent was obtained from the patient.

## ETHICAL APPROVAL

It is not applicable.

## COMPETING INTERESTS

The authors would like to note that there are no areas of potential conflict of interest, and that patient consent for publication was obtained in a timely manner.

## REFERENCES

1. Panneerselvam E, Panneerselvam K, Chanrashekar SS. Solitary bone cysts-a rare occurrence with bilaterally symmetrical presentation. *J. Oral Maxillofac. Pathol.* 2014;18:481.
2. Surej Kumar LK, Kurien N, Thaha KA. Traumatic bone cyst of mandible. *J. Maxillofac. Oral Surg.* 2015;14:466-469.
3. Joy ET, Raghupathy LP, Sherubin JE, And Kiran MS. A rare presentation of a simple bone cyst. *J. Pharm. Bioallied. Sci.* 2015; 7:s823-s826.
4. Lima, L.B., De Freitas Filho,S.A., Barbosa De Paulo,L.F., Servato,J.P., Rosa,R.R., Faria,P.R., Loyola,A.M., And Cardoso,S.V. Simple bone cyst: description of 60 cases seen at a brazilian school of dentistry and review of international literature. *Med. Oral Patol. Oral Cir. Bucal.* 2020;25:e616-e625.
5. Xanthinaki AA, Choupis KI, Tosios K, Pagkalos VA, Papanikolaou SI. traumatic bone cyst of the mandible of possible iatrogenic origin: a case report and brief review of the literature. *Head Face. Med.* 2006;2:40.
6. Blum T. An additional report on traumatic bone cysts; also a discussion of dr. John G. Whinery's paper, "progressive bone cavities of the mandible". *Oral Surg. Oral Med. Oral Pathol.* 1955;8:917-939.
7. Bindra S, Jadaun G, Jois HS, Sen P. Traumatic bone cyst of mandible: a case report of rare entity and review of literature. *Contemp. Clin. Dent.* 2019;10:3-8.
8. Razmara F, Ghoncheh Z, Shabankare G. Traumatic bone cyst of mandible: a case series. *J. Med. Case. Rep.* 2019;13:300.
9. Saldaña Sánchez A, Gómez Pedroso Balandrano a, Díaz Castillejos R, Castillo Ham G. Quiste óseo solitario maxilar y mandibular. Reporte de un caso y revisión de la literatura / maxillary and mandibular solitary bone cyst. Case report and literature review. *Revista Odontológica Mexicana.* 2018;22(1):40–45.
10. Musu D, Cotti E. Traumatic bone cyst of the jaws: an overview. *J. Biol. Regul. Homeost. Agents* 2019;33:1261-1263.
11. Satish K, Padmashree S, Rema J. Traumatic bone cyst of idiopathic origin? A report of two cases. *Ethiop. J. Health Sci.* 2014;24:183-187.
12. Suei Y, Taguchi A, Tanimoto K. A comparative study of simple bone cysts of the jaw and extracranial bones. *Dentomaxillofac. Radiol.* 2007;36:125-129.
13. Bindra S, Jadaun G, Jois Hs, Sen P. Traumatic bone cyst of mandible: a case report of rare entity and review of literature. *Contemp Clin Dent.* 2019;10 (1):3-8.
14. Suei Y, Taguchi A, Nagasaki T, Tanimoto K. Radiographic findings and prognosis of simple bone cysts of the jaws. *Dentomaxillofac. Radiol.* 2010;39:65-71.
15. Lee SY, Chung CY, Lee KM, Sung KH, Won SH, Choi IH, Cho TJ, Yoo WJ, Yeo JH, Park MS. Determining the best treatment for simple bone cyst: a decision analysis. *Clin. Orthop. Surg.* 2014;6:62-71.
16. Madiraju G, Yallamraju S, Rajendran V, Srinivasarao K. Solitary bone cyst of the mandible: a case report and brief review of literature. *Bmj Case. Rep.* 2014;2014.
17. Baqain ZH, Jayakrishnan A, Farthing PM, Hardee P. Recurrence of a solitary bone cyst of the mandible: case report. *Br. J. Oral Maxillofac. Surg.* 2005;43:333-335.
18. Howe GL. 'Haemorrhagic cysts' of the mandible. ii. *Br. J. Oral Surg.* 1965;3:77-91.
19. Hs CB, Rai BD, Nair MA, Astekar MS. Simple bone cyst of mandible mimicking periapical cyst. *Clin. Pract.* 2012;2:e59.
20. You Ms, Kim DY, Ahn KM. Surgical management of idiopathic bone cavity: case series of consecutive 27 patients. *J. Korean Assoc. Oral Maxillofac. Surg.* 2017; 43:94-99.

© 2021 Dib et al.; This is an Open Access article distributed under the terms of the Creative Commons Attribution License (<http://creativecommons.org/licenses/by/4.0>); which permits unrestricted use; distribution; and reproduction in any medium; provided the original work is properly cited.

Peer-review history:

The peer review history for this paper can be accessed here:  
<https://www.sdiarticle5.com/review-history/80409>