



# Ocular Involvement in Graves' Disease in Children: A Case Report

Rkia Azahrai <sup>a\*</sup>, Manar Achargui <sup>a</sup>, Fatimazahra Mabrouki <sup>a</sup>,  
Siham Chariba <sup>a</sup>, Asmaae Maadane <sup>a</sup>  
and Rachid Sekhsoukh <sup>a</sup>

<sup>a</sup> Ophthalmology Department, University Hospital Center Mohammed VI<sup>th</sup>, Oujda, Morocco.

## **Authors' contributions**

*This work was carried out in collaboration among all authors. All authors read and approved the final manuscript.*

## **Article Information**

### **Open Peer Review History:**

This journal follows the Advanced Open Peer Review policy. Identity of the Reviewers, Editor(s) and additional Reviewers, peer review comments, different versions of the manuscript, comments of the editors, etc are available here: <https://www.sdiarticle5.com/review-history/100865>

**Case Report**

**Received: 25/03/2023**

**Accepted: 30/05/2023**

**Published: 02/06/2023**

## **ABSTRACT**

Graves' disease in children is considered rare, these children can present ocular attacks related to this pathology. We report the case of a girl presenting an exophthalmia complicated by corneal attack in the framework of a graves' disease.

Our 6-year-old patient was admitted to the emergency room with bilateral exophthalmos associated with fluid diarrhea and palpitations.

The ophthalmological examination revealed: bilateral exophthalmos more accentuated on the left side with palpebral retraction and a heart rate of 160 beats per minute.

The diagnosis of Graves' disease was confirmed by thyroid receptor antibodies. The patient was put on: 40 mg of propranolol and 15 mg of carbimazole per day, with good clinical evolution, later the patient reconsulted for painful red eye with visual acuity decrease in left eye. The examination showed the presence of epithelial erosions with a rupture time lower than 5 seconds. The evolution was marked by a clinical improvement under lubricants and vitamin A.

Graves' orbitopathy reacts differently between adults and children on the one hand, and between different ethnic groups on the other hand.

\*Corresponding author: E-mail: [missazahrai@gmail.com](mailto:missazahrai@gmail.com);

It is more benign in children in the form of palpebral damage in most cases, unlike other manifestations such as nerve dysfunction and restrictive strabismus. We insist on the interest of lubricating treatment during palpebral retractions and lagophthalmos A find to avoid exposure keratitis.

*Keywords: Graves' disease; pediatrics; exophthalmos; palpebral retraction; exposure keratitis.*

## 1. INTRODUCTION

Graves' disease is an autoimmune disease characterized by the presence of antibodies (anti-thyroid receptors) that directly stimulate the thyroid gland via the TSH receptor (TSHR) [1].

Graves' disease in children accounts for 2.5% of all cases. Its incidence has been estimated at 0.8 per 100,000 children [2].

Children with Graves' disease often present with signs of Graves' ophthalmopathy, with a reported incidence of between 37% and 67% [2].

The diagnosis of Graves' disease is based on clinical signs of hyperthyroidism, thyroid function, and the presence of thyroid autoantibody stimulation [1].

The main ocular symptoms are eye irritation, foreign body sensation, tearing often aggravated by discomfort or pain, blurred vision and binocular diplopia [3].

Although vision-threatening manifestations appear to be rare in this condition (optic nerve damage, strabismus), special attention should be

paid to the cornea because its damage can lead to vision loss [3].

Graves' orbitopathy has been described as less severe and less common in children than in adults [2,3].

## 2. CLINICAL CASE

A 6-year-old girl, the first of two children, from a consanguineous marriage, Initially admitted to the pediatric emergency room for bilateral exophthalmos of rapidly progressive onset. The patient reported irritability and nervousness associated with liquid diarrhea, night sweats and palpitations.

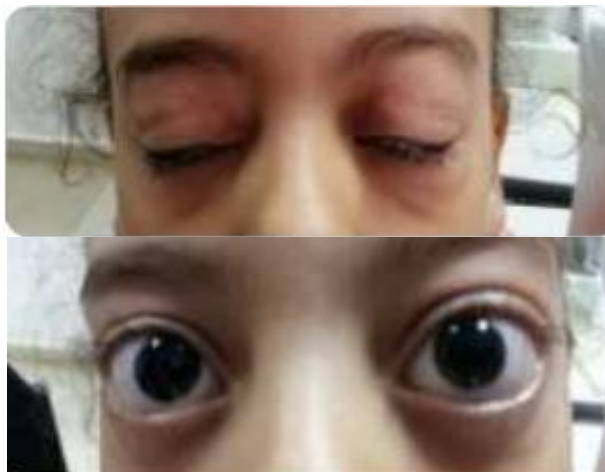The ophthalmological examination showed :

A bilateral exophthalmos more accentuated on the left side with palpebral retraction

A visual acuity of 10/10 bilaterally

The examination of ocular motility of the anterior and posterior segments was without particularities.

General examination found a heart rate of 160 beats per minute.



**Fig. 1. Photos of the patient showing bilateral signs of Graves' disease: Exophthalmos, palpebral retraction, with minimal edema and irritation of the eyelids**

The diagnosis of Graves' disease was confirmed by thyroid receptor antibody assay.

The patient was put on: 40 mg of propranolol and 15 mg of carbimazole per day.

The evolution was marked by a decrease of the heart rate to 120 beats per minute and regression of the general symptomatology.

Two weeks later, the patient returned to the emergency room with a painful red eye and decreased visual acuity in the left eye.

The examination revealed bilateral exophthalmos with retraction of the upper and lower eyelids,

In the left eye: The presence of epithelial erosions with a break-up time of less than 5 seconds.

Motor skills and fundus examination were normal.

The patient was treated with artificial tears, vitamin A ointment, topical antibiotics and occlusion of the left eye.

The evolution was favorable.

### 3. DISCUSSION

Graves' disease is an autoimmune disease that affects the thyroid gland and is characterized by the positivity of TSH receptor antibodies [1].

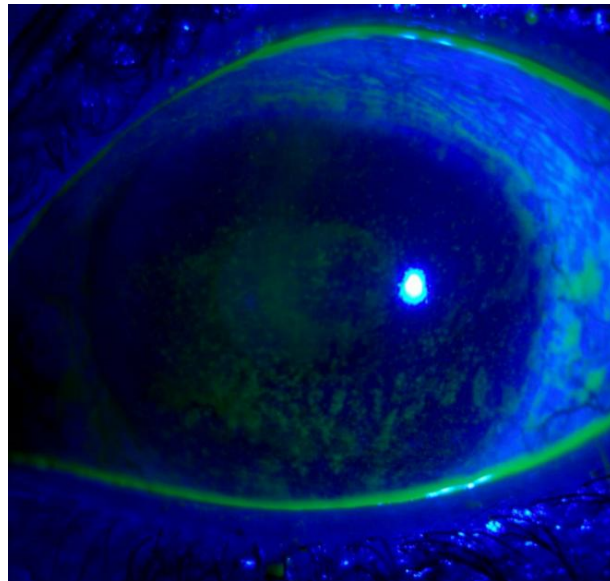


Fig. 2. Fluorescein test of the left eye showing the presence of epithelial erosions

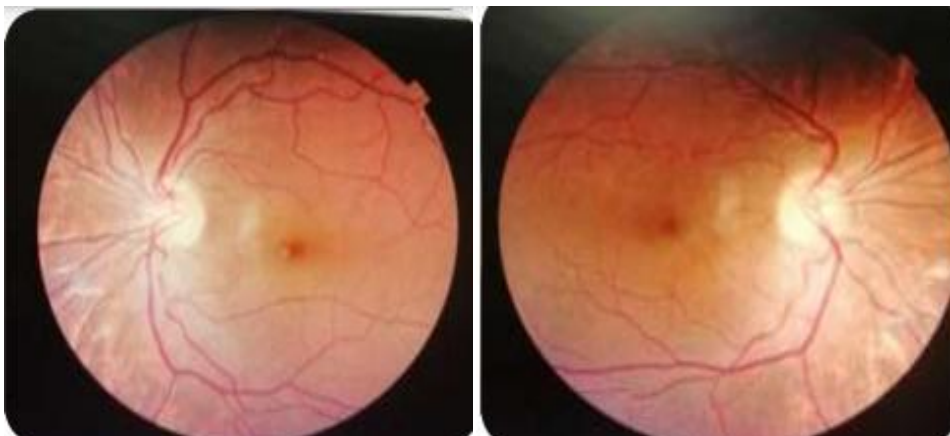

Fig. 3. Retinophotographs of both eyes showing the absence of anomalies in our patient

It is the most frequent cause of hyperthyroidism. It is a disease that affects 5 to 10 times more women than men [4,5].

Graves' disease is rare in the pediatric population. Its frequency is estimated to be 0.79 per 100,000 in Danish children to 6.5 per 100,000 in the Chinese pediatric population [6,7].

It is also important to point out that Graves' orbital disease reacts differently between adults and children on the one hand, and between different ethnic groups on the other hand [8].

In fact, Graves' orbitopathy appears to be more benign in children. Bartley et al. [8] studied 120 adult patients with Graves' orbitopathy and palpebral retraction was found in 91%, exophthalmos in 62%, restrictive strabismus in 43% and chemosis in 21%. Optic nerve dysfunction was present in 6% of patients.

In the pediatric population, studies have shown that the clinical manifestations of Graves' disease have involved more the eyelids, in contrast to other manifestations such as nerve dysfunction and restrictive strabismus [9-11].

It is assumed that this low frequency of extraocular myopathy is related to the lower levels of thyroid antibodies [10].

In Reader's study of 100 healthy eyes, the mean increase in IOP at 20 degrees of gaze elevation was 1.75 mm Hg. Five people had an IOP increase of 4 mm Hg and one subject had an elevation of 6 mm Hg. Thus, the elevation of intraocular pressure must be interpreted very carefully [12].

Regarding corneal involvement; In Liu's series [13], 11 patients had corneal complications fortunately they were mild punctate epithelial erosions. These results are explained by the high frequency of palpebral retraction and lagophthalmos. It can be easily managed with lubricating eye drops and euthyroidism [13].

Treatment should most often be maintained even if the disease is inactive, to prevent exposure keratitis [13].

A case study reported by Albrashdi [14] showed that the use of Tocilizumab in ophthalmological disorders associated with graves' disease accelerated the improvement of proptosis, edema and eyelid retraction.

#### 4. CONCLUSION

Ocular manifestations of Graves disease are common in children. Even if they're not as severe as adults.

Our attention must be drawn through this case to the problem of dry eye and surface alterations, which requires lubricating eye drops, and which may have an evolutionary potential, which may lead to vision loss.

A pediatrician and ophthalmologist cooperation is essential.

#### CONSENT

As per international standard, parental written consent has been collected and preserved by the author(s).

#### ETHICAL APPROVAL

As per international standard or university standard written ethical approval has been collected and preserved by the author(s).

#### COMPETING INTERESTS

Authors have declared that no competing interests exist.

#### REFERENCES

1. Aghini-Lombardi F, Antonangeli L, Martino E, et al. The spectrum of thyroid disorders in an iodine-deficient community: The Pescopagano survey. *J Clin Endocrinol Metab.* 1999;84:561–566
2. Henry Holt, MDA David G. Hunter, MD, PhD, b Jessica Smith, MD, b and Linda R. Dagi, MD Pediatric Graves' ophthalmopathy: The pre- and Post-pubertal Experience. 2008;12:357-360
3. Chan W, Wong G, Fan D, Cheng A, Lam D, Ng J. Ophthalmopathy in childhood Graves' disease. *Br J Ophthalmol.* 2002;86:740-2.
4. Vanderpump MP, Tunbridge WM, French JM, et al. The incidence of thyroid disorders in the community: A twenty-year follow-up of the Whickham Survey. *Clin Endocrinol (Oxf).* 1995;43:55–68.

5. Perrild H, Lavard L, Brock-Jacobsen B. Clinical aspects and treatment of juvenile Graves' disease. *Exp Clin Endocrinol Diabetes*. 1997;105(Suppl 4):55–7:55–7.
6. Wong GW, Cheng PS. Increasing incidence of childhood Graves' disease in Hong Kong: a follow-up study. *Clin Endocrinol*. 2001;54:547–50.
7. Sim B, Chng CL, Audrey C, Seah LL. A retrospective study of pediatric thyroid eye disease: the Asian experience. *Orbit*. 2022;41(1):69-78.
8. Bartley GB, Fatourech V, Kadrmas EF, Jacobsen SJ. The incidence of graves' ophthalmopathy in Olmsted County, Minnesota. *Am J Ophthalmol Am*. 1995; 120(4):511-7
9. Uretsky SH, Kennerdell JS, Gutai JP. Graves' ophthalmopathy in childhood and adolescence. *Arch Ophthalmol*. 1980;98: 1963–4.
10. Young LA. Dysthyroid ophthalmopathy in children. *J Pediatr Ophthalmol Strabismus* 1979;16:105–7.
11. Gruters A. Ocular manifestations in children and adolescents with thyrotoxicosis. *Exp Clin Endocrinol Diabetes* 1999;107(Suppl 5):S172–4.
12. Reader AL III. Normal variations of intraocular pressure on vertical gaze. *Ophthalmology* 1982;89:1084–7.
13. Liu GT, Heher KL, Katowitz JA, Kazim M, Moazami G, Moshang T, et al. Prominent proptosis in childhood thyroid eye disease. *Ophthalmology*. 1996;103: 779-84.
14. Albrashdi S, Alsharqi H, Habroosh F, Eatamadi H. Tocilizumab use in pediatric thyroid eye disease: First documented case. *American Journal of Ophthalmology Case Reports*. 2022;25: 101387.

© 2023 Azahrai et al.; This is an Open Access article distributed under the terms of the Creative Commons Attribution License (<http://creativecommons.org/licenses/by/4.0>), which permits unrestricted use, distribution, and reproduction in any medium, provided the original work is properly cited.

*Peer-review history:*  
The peer review history for this paper can be accessed here:  
<https://www.sdiarticle5.com/review-history/100865>