



An Unusual Presentation of Gall Bladder Perforation as an Anterior Abdominal Wall Abscess

Shaan Hassan ^{a*}, Sayema ^{b#}, Atiya Zaka-Ur-Rab ^{a‡} and Rajashree Kundu ^{a†}

^a Department of Surgery, JNMCH, AMU, Aligarh, India.

^b Department of Radiodiagnosis, JNMCH, AMU, Aligarh, India.

Authors' contributions

This work was carried out in collaboration among all authors. Author SH was equally involved in preparation of the manuscript of this case report. Authors Sayema and AZUR were involved actively in case management and provided useful suggestions regarding the case. All authors read and approved the final manuscript.

Article Information

Open Peer Review History:

This journal follows the Advanced Open Peer Review policy. Identity of the Reviewers, Editor(s) and additional Reviewers, peer review comments, different versions of the manuscript, comments of the editors, etc are available here: <https://www.sdiarticle5.com/review-history/92500>

Case Report

Received 20 July 2022
Accepted 30 September 2022
Published 05 October 2022

ABSTRACT

A lump in the abdominal wall in right upper quadrant of abdomen can be because of a myriad of reasons and a ruptured gall bladder is one of the least suspected underlying causes. Overall, gallbladder perforation is quite serious an entity with high morbidity and mortality rates and hence early detection of this entity and subsequent needed interventions are extremely important for successful treatment of the patient. We hereby report a case of a perforated gallbladder secondary to underlying acute calculous cholecystitis. The patient had presented with a painful swelling over right upper quadrant of abdomen with no septic complication and stable vitals. Upon cross sectional imaging it was diagnosed as acute calculus cholecystitis with rupture of gallbladder and adjacent pericholecystic and anterior abdominal wall abscess formation. It was managed with percutaneous pigtail placement under ultrasound guidance and was discharged with stable vitals with pigtail-in-situ after 6 days. Pigtail was functional and definitive therapy in the form of interval cholecystectomy was undertaken after a gap of 3 months which was uneventful. Appropriate identification of cause and subsequent intervention is imperative to patient's well-being. Also not rushing into a cholecystectomy in an acutely inflamed gall-bladder is a very good decision to prevent inadvertent bile duct injuries.

^aSenior Resident;

[#]Assistant Professor;

[‡]Professor;

[†]Junior Resident;

^{*}Corresponding author: E-mail: SHAANHASSAN82@GMAIL.COM;

Keywords: Gallbladder; perforation; abdominal wall abscess; cholecystitis; pigtail.

1. INTRODUCTION

Gall-bladder perforation is an unusual and potentially serious clinical scenario and timely diagnosis is extremely necessary to obtain good results. A perforated gallbladder being the cause of right upper quadrant anterior abdominal swelling is rather unusual. The main cause of gall bladder perforation is usually cholecystitis – which may or may not be associated with gallstones [1]. The incidence of gall bladder perforation in acute cholecystitis lies between 2-18% [2-6]. The chance of gallbladder perforation is even higher in a case of acalculous cholecystitis, varying between 10-20%. Clinical presentations of gallbladder perforations are similar irrespective of the underlying cause [4,5,7].

2. PRESENTATION OF CASE

A 72-year-old man was admitted with a painful lump of about 6x6cms over right hypochondrium for 2 weeks associated with nausea and vomiting (Figs. 1A & B). He was vitally stable. His blood reports were within normal range for age - haemoglobin 11 g/dl, white blood cell count 7600/cc and platelet count 1,73,000/cc. His Alkaline phosphatase level was 91U/L, Aspartate Transaminase (AST) and Alanine Transaminase (ALT) levels were 40 U/L and 24 U/L respectively. His total bilirubin was 0.5 mg/dl, urea was 14 mg/dL and creatinine 0.89 mg/dL. Serum amylase and lipase were 200 IU/L and 300IU/L respectively.

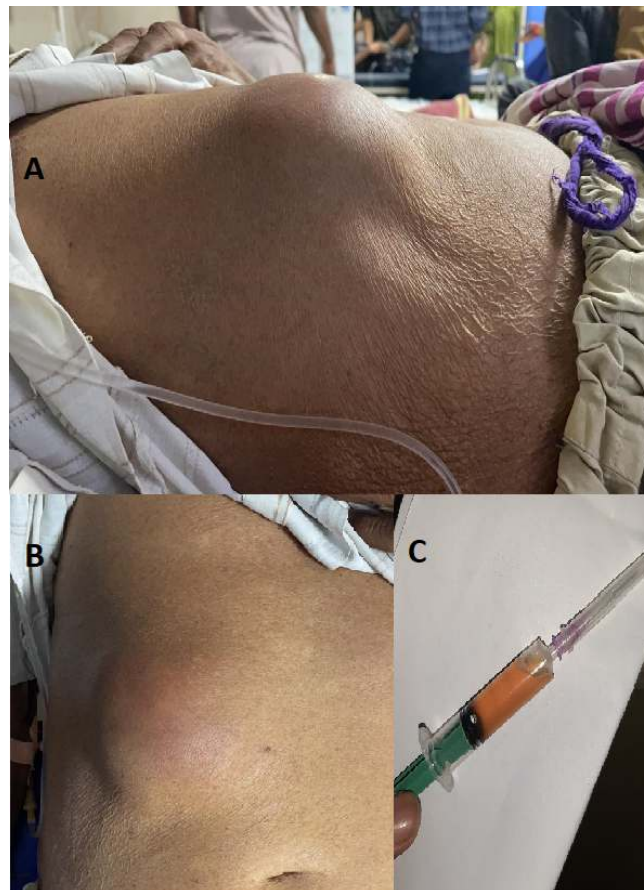


Fig. 1(A,B). Clinical picture of the patient's abdomen showing a right upper quadrant lump of anterior abdominal wall with mild skin inflammation evident as redness;
C. Ultrasound guided aspirate from the anterior abdominal wall collection reveals bile tinged serous fluid

3. IMAGING FINDINGS

Ultrasound abdomen: Revealed a defect in the wall of the gallbladder near fundus with loculated, hypoechoic collection of around 35-40 cc volume in pericholecystic region with contracted and edematous gall bladder with wall thickness of 6mm. Also a 6 mm stone in fundal region of gall bladder with dilated proximal common bile duct (11mm) and mild localized collection in parietal wall of right upper abdomen communicating with pericholecystic collection. On ultrasound guided fluid aspiration (Fig. 1C) a yellow-green tinged fluid aspirate was seen (bile tinged) and was sent for culture which was negative for any growth.

CECT Abdomen: (Figs. 2 & 3) - A contrast enhanced CT scan of abdomen was performed

which showed 4 mm focal defect in gallbladder fundal region with radio dense 6*6mm calculus within gall bladder with near total contracted lumen and thickened gall bladder wall (upto 6 mm). There was also evidence of irregularly shaped heterogenous, hypodense, peripherally enhancing collection in right upper quadrant region around gall bladder fossa, extending along liver with mesenteric fat streakiness leading to a focal elliptical lump formation measuring 89*42*80 mm. Extraperitoneal extension of collection in adjacent abdominal wall in right upper quadrant of abdomen was seen with subcutaneous oedema. Common bile duct was mildly prominent (upto 10 mm) but with a tapering course and with no intraluminal contents to suggest choledocholithiasis (due to stasis).

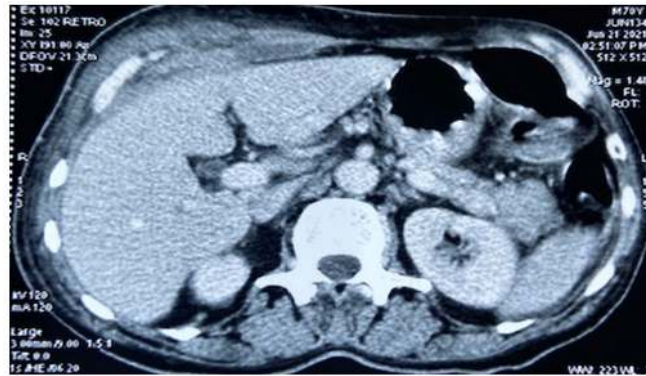

Fig. 2. Axial CECT Upper abdomen image reveals mild peripherally enhancing collection anterior to liver with heterogeneity and bulky anterior abdominal wall muscles

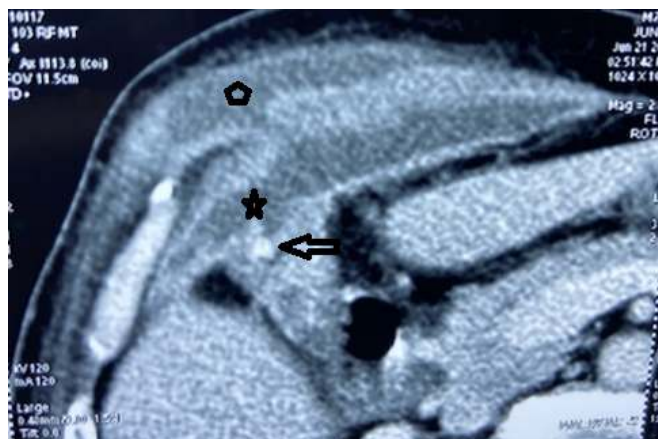


Fig. 3. Axial CECT zoomed view reveals a hyperdense calculus in gall bladder fundus (marked by black arrow), a focal defect in fundal wall of gall bladder (marked by star) and peripherally enhancing collection anterior to liver and going into the adjacent right abdominal wall within intermuscular planes forming a lump there (marked by pentagon). The gall bladder overall is contracted and thickened and liver bed is not infiltrated

4. MANAGEMENT

- **Immediate management:** A pigtail was placed under ultrasound guidance inside the abscess cavity. The pigtail started draining all the intraparietal as well as pericholecystic collection. Stat output of approximately 30cc was noted within collection bag. The pigtail was kept in-situ and the patient was discharged under stable condition next day and called for follow up in OPD.
- **Surgical management:** Interval cholecystectomy was done after 3 months interval. Histopathology revealed acute inflammatory infiltrates within background of chronic cholecystitis however negative for any features of malignancy.

5. DISCUSSION

Gallbladder perforation is potentially life-threatening. Niemier classified gallbladder perforation into three types- type 1: acute free perforation into peritoneal cavity, type 2: subacute perforation into pericholecystic abscess, type 3: chronic perforation into cholecysto-enteric fistula [8,9]. Roselyn et al concluded in their study that type 1 and 2 mostly take place in young patients whereas type 3 occurs in older population [3]. Gallbladder perforations can be further classified based on the underlying etiology into – 1) spontaneous, 2) traumatic and 3) iatrogenic. Although the cause of perforation is often debated, the most plausible cause is increased intraluminal pressure possibly due to an impacted stone in the neck which leads to venous and lymphatic stasis and eventually subsequent necrosis of the wall. The presence of 60% perforations in the fundus region which has the least blood-supply further substantiates this ischaemic theory [3,6,10-12].

Clinical diagnosis of gallbladder perforation is quite difficult and in mild cases, may be inseparable from acute uncomplicated cholecystitis cases. But its very important to distinguish these two entities as bile leak can cause an overwhelming biliary peritonitis in which case any delay in initiation of treatment will adversely affect the outcome [10] Ultrasound is the first imaging modality to be used in such cases but, many at times it may be very difficult to distinguish it from just an acute cholecystitis because in both conditions there is gallbladder distension and wall edema. A defect in the wall of

gall bladder (Hole sign) is a positive imaging sign for gallbladder perforation but can be demonstrated on high resolution ultrasound in only 70% cases [6,7,13]. Contrast enhanced CT abdomen (CECT) is usually the confirmatory investigation which not only depicts changes in gallbladder such as gallbladder wall thickness, edema and wall defects but also haemorrhage or abscess formation along with cystic duct or common bile duct stones and any evidence of intra-luminal gas. Pericholecystic changes are also detected on CECT abdomen which include pericholecystic fat stranding, pericholecystic fluid collection, abscess or bilioma formation, presence of extra-luminal stones, adjacent liver bed enhancement, liver abscess, portal vein thrombosis, lymphadenopathy, reactive mural thickening of adjacent hollow organs (hepatic flexure of colon and duodenum), intra-peritoneal free air, ascites and features suggesting Mirizzi syndrome [6,13].

In cases of type 1 perforation, there can be either exploratory laparotomy and open cholecystectomy with peritoneal lavage or, in some cases laparoscopic cholecystectomy with peritoneal lavage – both are equally acceptable and both have good results. In fact, most of the studies show good results post-operatively even after biliary peritonitis. But in cases of type 2 or type 3 gall bladder perforation with stable vitals, pigtail drainage of the local collection followed by interval cholecystectomy is a good option and should be considered. It has favourable outcome and very low risk of bile duct injuries that could take place if surgery takes place at the peak of inflammation [14-16].

6. CONCLUSION

Our case highlights a serious complication of acute cholecystitis which is gallbladder perforation presenting as a contained parietal and abdominal wall abscess. It is a rather uncommon etiology for a right upper quadrant abdominal lump. Gall bladder perforation needs early diagnosis and immediate management to prevent mortality. It is diagnosed with the help of prompt imaging (ultrasound and CECT abdomen) and managed by an immediate surgical intervention. In cases of contained perforation, minimally invasive intervention like pigtail drainage or cholecystostomy followed later by definitive surgical management - open interval cholecystectomy can be performed.

CONSENT

Informed consent was taken over our institutional consent form for procedure and publication of the case. Identity of the patient is not revealed anywhere in the case report directly/indirectly.

ETHICAL APPROVAL

As per international standard or university standard written ethical approval has been collected and preserved by the author(s).

COMPETING INTERESTS

Authors have declared that no competing interests exist.

REFERENCES

1. Sheoran SK, Sahai RN, Indora J, Biswal UC. Spontaneous perforation of gallbladder: Case report. *Gastroenterology Research*. 2016;9(2–3):61.
2. Kim HJ, Park SJ, Lee SB, et al. A case of spontaneous gallbladder perforation. *Korean J Intern Med*. 2004;19(2): 128-131.
DOI:10.3904/kjim.2004.19.2.128
3. Roslyn J, Busuttill RW. Perforation of the gallbladder: A frequently mismanaged condition. *Am J Surg*. 1979;137(3): 307-12.
DOI: 10.1016/0002-9610(79)90056-4.
PMID: 434321.
4. Kalliafas S, Ziegler DW, Flancbaum L, Choban PS. Acute acalculous cholecystitis: incidence, risk factors, diagnosis, and outcome. *Am Surg*. 1998;64(5):471-5.
5. Ryu JK, Ryu KH, Kim KH. Clinical features of acute acalculous cholecystitis. *J Clin Gastroenterol*. 2003; 36(2):166-9.
DOI: 10.1097/00004836-200302000-00015. PMID: 12544202.
6. Chaudhary R, Gupta N, Abrol RK, Sood S, Ambekar MM, Katoch S. Spontaneous type 1 gallbladder perforation in an elderly patient presenting with acute generalised peritonitis: A case report. *SN Compr Clin Med*. 2019;1:708–11.
7. Jamil Suleiman, Alex Mremi, Murad Tarmohamed, Adnan Sadiq, Jay Lodhia, Concealed gallbladder perforation: A rare case report, *Journal of Surgical Case Reports*. 2021;(6):245.
Available:https://doi.org/10.1093/jscr/rjab245
8. Niemeier OW. Acute Free Perforation of the Gall-Bladder. *Ann Surg*. 1934;99(6): 922–924.
9. Anderson BB, Nazem A. Perforations of the gallbladder and cholecystobiliary fistulae: A review of management and a new classification. *J Natl Med Assoc*. 1987;79(4):393-9.
PMID: 3586037; PMCID: PMC2625500.
10. Felice PR, Trowbridge PE, Ferrara JJ. Evolving changes in the pathogenesis and treatment of the perforated gallbladder. A combined hospital study. *Am J Surg*. 1985;149(4):466-73.
DOI:10.1016/s0002-9610(85)80041-6.
PMID: 3985286.
11. Estevao-Costa J, Soares-Oliveira M, Lopes JM, Carvalho JL. Idiopathic perforation of the gallbladder: A novel differential diagnosis of acute abdomen. *J Pediatr Gastroenterol Nutr*. 2002;35: 88–89.
12. Derici H, Kara C, Bozdog AD, Nazli O, Tansug T, Akca E. Diagnosis and treatment of gallbladder perforation. *World J Gastroenterol*. 2006;12(48): 7832-6.
DOI: 10.3748/wjg.v12.i48.7832.
PMID: 17203529;
PMCID: PMC4087551.
13. Sood BP, Kalra N, Gupta S, Sidhu R, Gulati M, Khandelwal N, Suri S. Role of sonography in the diagnosis of gallbladder perforation. *J Clin Ultrasound*. 2002;30: 270–274.
14. Cho SW, Shim CS, Lee JS, Lee MS, Park CW, Song DW, Kwon KH, Hong SJ. A case of gallbladder perforation treated by percutaneous transhepatic cholecystic drainage and percutaneous peritoneal drainage. *Korean J Gastrointest Endosc*. 1994;14(4):482-488.
15. Kim HC, Kim SE, Han SH, Shin DH, Lee WJ, Lee JS, Baik HW, Jeon YB, Kim YT, Yoon YB. Percutaneous cholecystostomy and percutaneous abscess drainage in two

- patients of gallbladder perforation with high surgical risk. Korean Journal of Gastrointestinal Endoscopy. 2002;24(1): 52-8.
16. Doherty GM, Way LW. Biliary Tract. In: Way LW, Doherty GM, editors. Current Surgical Diagnosis & Treatment. 11st Ed. New York: McGraw-Hill. 2003;595–624.

© 2022 Hassan et al.; This is an Open Access article distributed under the terms of the Creative Commons Attribution License (<http://creativecommons.org/licenses/by/4.0>), which permits unrestricted use, distribution, and reproduction in any medium, provided the original work is properly cited.

Peer-review history:

The peer review history for this paper can be accessed here:

<https://www.sdiarticle5.com/review-history/92500>