



Postmenopausal Bleeding with an Accidental Discovery of an Ovarian Strumal Carcinoid Tumor: A Case Report

Eman M. Ibrahim¹, Salma S. El Ashwah², Fatma I. El-Saeed³,
Hosam A. F. Halim⁴ and Amal A. F. Halim^{5*}

¹Pathology Department, Faculty of Medicine, Mansoura University, Egypt.

²Medical Oncology Unit, Mansoura Oncology Center, Mansoura University, Egypt.

³Clinical Oncology Department, Meet Ghmmr Oncology Center, Egypt.

⁴General Surgery Department, Student Hospital, Mansoura University, Egypt.

⁵Clinical Oncology and Nuclear Medicine Department, Faculty of Medicine, Mansoura University, Egypt.

Authors' contributions

This work was carried out in collaboration among all authors. Author EMI selected the case and prepared the images. Authors SSEA and FIE-S reviewed the patient detailed data and shared in collecting the literature. Author HAFH Shared in collecting the literature and writing the draft. Author AAFH selected the needed literature and wrote the manuscript. All authors read and approved the final manuscript.

Article Information

DOI: 10.9734/JCTI/2021/v11i130141

Editor(s):

(1) Dr. Pandiaraja. J, Shree Devi Hospital, India.

Reviewers:

(1) Petros Hirides, Athens Medical Centre, Greece.

(2) Sadequel Islam Talukder, Mymensingh Medical College, Bangladesh.

Complete Peer review History: <http://www.sdiarticle4.com/review-history/65177>

Case Report

Received 25 November 2020

Accepted 02 February 2021

Published 25 February 2021

ABSTRACT

Aim: Ovarian strumal carcinoid is a tumor formed of thyroid tissue and carcinoid elements. It represents less than 2% of all ovarian tumors and less than 5% of mature teratomas. Physicians in many locations may not be aware about this pathology.

Presentation of Case: A multiparous 78-year-old woman presented by postmenopausal vaginal bleeding. The abdomen & pelvic sonar detected atrophied endometrium and a right adnexal mass with mixed echogenicity and increased blood flow, a finding that was confirmed later with a pelvic MRI which revealed a well-defined mass of abnormal signal at the right adnexa showing cystic

*Corresponding author: Email: halim43210@mans.edu.eg;

changes contacting anteriorly the related intestinal loops and the urinary bladder, while contacting posteriorly the recto-sigmoid. It measured 8x6x6cm. Biopsy revealed atypical epithelial proliferation. CA125 was 90KU/L (normal range, 0-35KU/L) while the levels of CEA, CA19-9 and alpha feto protein were normal. After discussion with the family, exploratory hysterectomy and bilateral salpingo-oophorectomy, along with omentectomy, peritoneal washing and peritoneal sampling were performed. Grossly, the right ovary was largely occupied by an ovoid mass (9cmx6cmx2 cm). The tumor was staged as IA according to AJCC 2010. Histological examination of the adnexal mass revealed admixture of benign thyroid tissue and tumor tissue formed of trabeculae & nests of monotonous round cells. Such cells showed positivity for thyroglobulin, synaptophysin, chromogranin and low positivity for ki67 and so a diagnosis of strumal carcinoid tumor was documented. The patient was set to a close follow up. The last follow up was at August 2020 and was satisfactory.

Discussion and conclusion: Strumal carcinoids are rare. Pelvic sonar and CA125 are not specific diagnostic tools. They should be considered in the differential diagnosis of any ovarian mass. The disease usually presents at an early stage.

Keywords: Ovarian teratoma; strumal carcinoid; Carcinoid syndrome.

1. INTRODUCTION

Mature cystic teratomas (MCT) are the most common among all ovarian neoplasms, representing 30-40% of the cases [1]. Rarely MCT, undergo malignant transformation (0.94-2%) [2]. Struma ovarii is a variant of MCT, with a predominant thyroid element. Confirmatory diagnosis is through histopathology [3]. Malignant transformation in struma ovarii is uncommon and mostly in the form of follicular thyroid carcinoma [4].

2. PRESENTATION OF THE CASE

A multiparous 78-year-old woman presented by vaginal bleeding without any criteria of a carcinoid syndrome. The woman had an uncomplicated medical and gynecological history with regular menstrual cycle. The general examination was uneventful. Abdominal and pelvic examination revealed a firm right adnexal mass of limited mobility. The abdomen & pelvic sonar detected an atrophied endometrium and a right adnexal mass with mixed echogenicity and increased blood flow. The biopsy of which (May 2018) revealed atypical epithelial proliferation. MRI of abdomen and pelvis revealed a well-defined mass of abnormal signal at the right adnexa showing cystic changes contacting anteriorly the related intestinal loops and the urinary bladder, while contacting posteriorly the recto-sigmoid. Superiorly, it was contacting the related right iliac vessels. It measured 8x6x6cm. Biopsy revealed atypical epithelial proliferation. Unfortunately, we found in the archive the reports of the sonography and the MRI but not the films.

Ca125 was 90ku/l (normal range, 0-35ku/l) while the levels of CEA, CA 19-9 and alpha feto protein were normal. CT scan of chest was free. After discussion with the patient and her family, exploratory hysterectomy and bilateral salpingo-oophorectomy, along with omentectomy, peritoneal washing and peritoneal sampling were performed. Fortunately, the postoperative period was uneventful, and the patient was discharged on the fifth postoperative day.

Grossly, the left ovary and tube were free. The right ovary showed a lobulated surface. The cut surface was yellow in color and with areas of mixed firm and cystic consistency. The right ovary was largely occupied with an ovoid mass (9cmx6cmx2 cm). The tumor was staged as IA according to AJCC 2010.

Microscopic examination revealed a compressed normal ovarian tissue with underlying tumor tissue. The tumor was composed partly of thyroid tissue with thyroid follicles filled with colloid and partly of tumor cell clusters composed of monomorphic cells of granular cytoplasm. The nuclear chromatin was finely granular and mitosis was hardly detected. The tumor cells were arranged in trabecular structures or in solid nests (Fig. 1). Moreover, immunohistochemistry revealed positivity for thyroglobulin, synaptophysin, chromogranin and low positivity for ki67 (Fig. 2). The endometrium was atrophic.

The patient was set to a close follow up with gynecological examination and ultrasound imaging every 3-6 months and CT scan of abdomen & pelvis every 6-12 months in the first year following surgery. The follow up during the

following years was recommended to be less frequent. The last follow was satisfactory and was in august 2020.

The Patient Gave Her Consent To Publish The Case.

The Institutional Review Board Approved The Work.

3. DISCUSSION

Carcinoid tumors are usually a slow-growing type of neuroendocrine tumors. It is worth to note that neuroendocrine tumors originate mainly from gastroenteric tissue, pancreatic islet cells, neuroendocrine cells within the respiratory epithelium, and parafollicular cells distributed within the thyroid. They occasionally have secretory characteristics, with a rather unusual and complex disease spectrum with various manifestations, such as flushing, diarrhea, hirsutism, or constipation [5]. Our case did not present with any of these symptoms. Her

postmenopausal vaginal bleeding may be due to the atrophic endometrium [6]. Primary carcinoid tumors of the ovary account for <0.1% of all ovarian malignancies, and only 5% of carcinoid tumors are of the ovarian origin. The ovarian carcinoid tumors are typically divided into 4 categories based on the histopathologic patterns: insular, trabecular, mucinous, and strumal [7]. On searching through the PubMed for strumal carcinoid tumors, 100 publications were retrieved. However, none of them were related to our locality. The rate of malignant transformation in MCT worldwide is much higher in postmenopausal ages [8] which coincides with the age of our case. In less than 10% of the published stromal carcinoids, there was a contralateral neoplasm of the ovary [9]. We did not find a contralateral ovarian pathology. Our case was stage I similar to most literature [10]. Coexisting of graves' disease and functioning struma ovarii is a rare condition [11]. One of the limitations of this case report is that no thyroid function tests were documented.

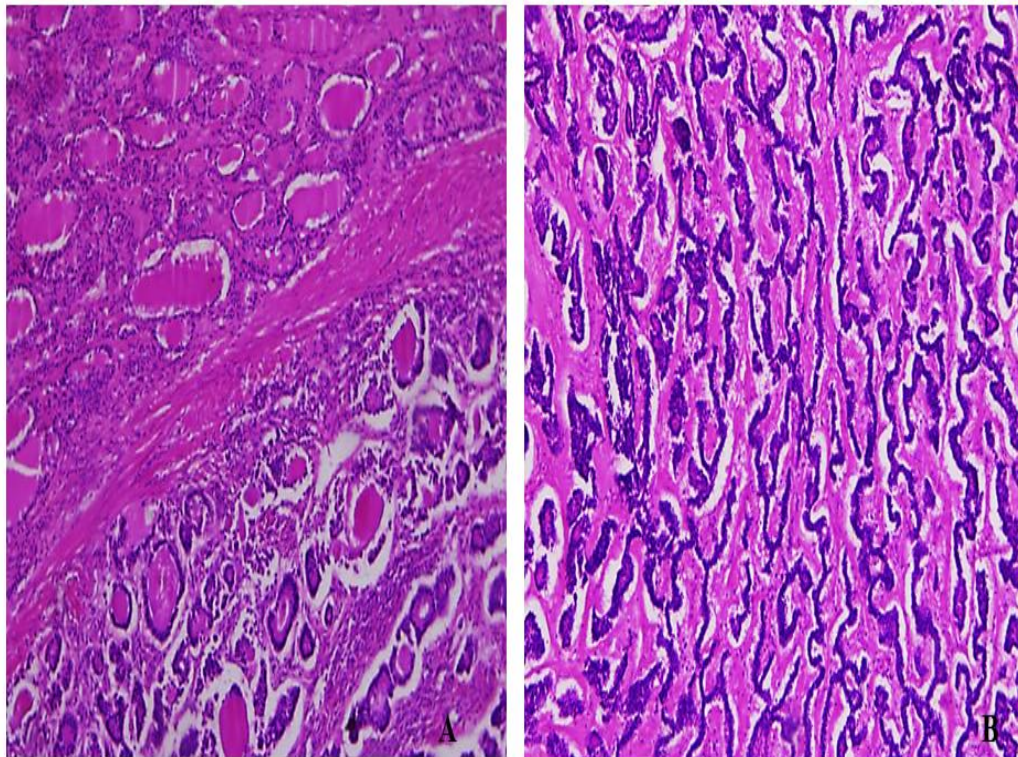


Fig. 1. Histological features of the ovarian tumor
A-admixture of benign thyroid tissue (left) and tumor tissue (right) (H&E; x10)
B-the tumor cells are arranged in acinar and trabecular structures (H&E; x10)

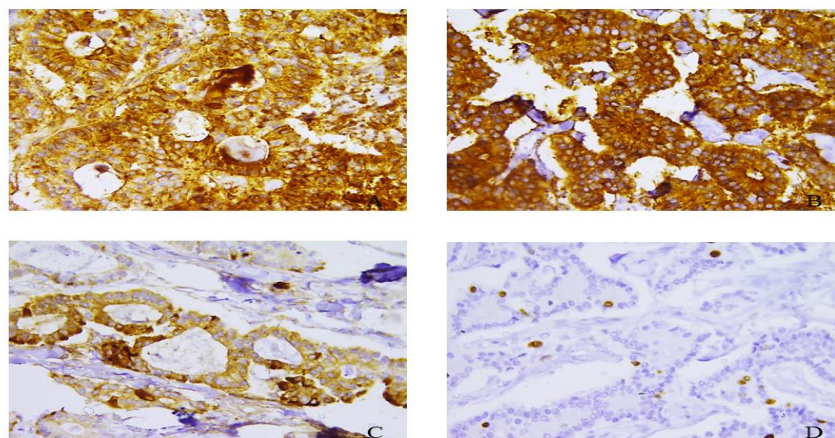


Fig. 2. Immunohistochemical features of the ovarian tumor
Positive staining of the tumor cells for thyroglobulin(A) ,synaptophysin(B), and chromogranin(C). Ki-67(D)revealed low proliferation index(x40)

4. CONCLUSION

Strumal carcinoid rarely occurs. It is most probably even rarer in our locality. Pelvic sonar and CA125 are not specific diagnostic tools. Strumal carcinoid should be considered in the differential diagnosis of an ovarian mass in postmenopausal patients.

CONSENT

The patient gave her consent to publish the case.

ETHICAL APPROVAL

The institutional review board approved the work.

ACKNOWLEDGEMENT

We present our deep appreciation to the IT team.

COMPETING INTERESTS

Authors have declared that no competing interests exist.

REFERENCES

- Mabuchi Y, Ota N, Kobayashi A, Tanizaki Y, Minami S, Ino K. Identical twins with mature cystic teratomas treated with laparoscopic surgery: two case reports. *Mol Clin Oncol*. 2017;6(2):276-278. DOI:10.3892/mco.2016.1118
- Momin YA, Kulkarni MP, Pandav AB, Sulhyan KR. Mucoepidermoid carcinoma in a mature cystic teratoma: A rare case report with review of literature. *Indian J Pathol Microbiol*. 2017;60(1):117-118. DOI: 10.4103/0377-4929.200038
- Singh P, Lath N, Shekhar S, Goyal M, Gothwal M, Yadav G, et al. Struma ovarii: A report of three cases and literature review. *J Midlife Health*. 2018;9(4):225-229. DOI: 10.4103/jmh.jmh_53_18
- Mandić A, Rajović J, Tesić M, Vujkov T, Krnojelac D, Komazec S. Benign and malignant struma ovarii: Report of three cases and review of the literature. *J Buon*. 2002;7:67-70.
- Noh HK, Kwon BS, Kim YH, Lee NK, Choi KU, Suh DS, et al. Peptide YY producing strumal carcinoid tumor of the ovary in a postmenopausal woman: A rare cause of chronic constipation. *Obstet Gynecol Sci*. 2017;60(6):602-607. DOI: 10.5468/OGS.2017.60.6.602
- Lidor A, Ismajovich B, Confino E, David MP. Histopathological findings in 226 women with post-menopausal uterine bleeding. *Acta Obstet Gynecol Scand*. 1986;65(1):41-43. PMID: 3716779. DOI: 10.3109/00016348609158227
- Antovska VS, Trajan Ova M, Kristeva I, Gosheva I, Chelebieva J, Prodanova I. Ovarian strumal carcinoid tumour: case report. *Open Access Maced J Med Sci*. 2018;6(3):540-543. DOI: 10.3889/oamjms.2018.138
- Rathore R, Sharma S, Agarwal S. Malignant transformation in mature cystic teratoma of the ovary: A retrospective study of eight cases and review of

- literature. Prz Menopauzalny. 2018; 17(2):63-68.
DOI: 10.5114/PM.2018.77304
9. Robboy SJ, Scully RE. Strumal carcinoid of the ovary: An analysis of 50 cases of a distinctive tumor composed of thyroid tissue and carcinoid. 1980;46(9):2019-2034.
DOI:10.1002/10970142(19801101)46:9<2019:aid-cnrcr2820460921>3.0.co;2-w.
10. Yamaguchi M, Tashiro H, Motahari K, Ohba T, Kawauchi H. Primary strumal carcinoid tumor of the ovary: A pregnant patient exhibiting severe constipation and cea elevation. Gynecol Oncol Case Rep. 2012;4: 9-12.
DOI: 10.1016/j.gynor.2012.11.003
11. Sitasuwan T, Hanamornroongruang S, Peerapatdit T, Thongtang N. Coexistence of graves' disease and unilateral functioning struma ovarii: A case report. Case Reports BMC Endocr Disord. 2015;15:68.
DOI: 10.1186/s12902-015-0060-z

© 2021 Ibrahim et al.; This is an Open Access article distributed under the terms of the Creative Commons Attribution License (<http://creativecommons.org/licenses/by/4.0>), which permits unrestricted use, distribution, and reproduction in any medium, provided the original work is properly cited.

Peer-review history:

*The peer review history for this paper can be accessed here:
<http://www.sdiarticle4.com/review-history/65177>*