

# Retropharyngeal Abscess Presenting as Stridor in a 35 Days Male Infant: A Case Report

Achinta Kumar Mallick <sup>a\*</sup>, Abhishek Mishra <sup>b</sup>, Pravin Kumar Yadav <sup>c</sup>  
and Anushree Mishra <sup>d</sup>

<sup>a</sup> Department of Pediatrics, Military Hospital Bathinda, Punjab, India.

<sup>b</sup> Department of Radiology, Military Hospital Bathinda, Punjab, India.

<sup>c</sup> Department of Otorhinolaryngology, Military Hospital Bathinda, Punjab, India.

<sup>d</sup> Department of Ophthalmology, Military Hospital Bathinda, Punjab, India.

## Authors' contributions

This work was carried out in collaboration among all authors. Author AKM, PKY and AM contributed in finalization of the manuscript. Author AKM drafted the final manuscript. All authors read and approved the final manuscript.

## Article Information

DOI: 10.9734/AJPR/2022/v8i330243

## Open Peer Review History:

This journal follows the Advanced Open Peer Review policy. Identity of the Reviewers, Editor(s) and additional Reviewers, peer review comments, different versions of the manuscript, comments of the editors, etc are available here: <https://www.sdiarticle5.com/review-history/84565>

Case Report

Received 12 January 2022

Accepted 14 March 2022

Published 19 March 2022

## ABSTRACT

Retropharyngeal abscess (RPA) is a rare entity in infants. There is limited knowledge and literature available about RPA in neonates and young infants owing to its atypical presentation, often causing a diagnostic dilemma to the treating physicians. RPA should always be kept in mind for all infants presenting with upper respiratory tract symptoms. Proper history, meticulous clinical examination and a very high index of suspicion is key to its prompt diagnosis. There is always a risk of airway compromise in neonates and young infants, owing to the narrow airway and an early surgical intervention is mandatory. We hereby present a rare case of RPA in a 35 day old male infant having atypical presentation of stridor and sepsis. Timely radiological evaluation in form of ultrasonography (USG) & contrast enhanced computerized tomography (CECT) neck was instrumental not only in prompt diagnosis but also in immediate decompression drainage of abscess which turned out to be lifesaving.

**Keywords:** Retropharyngeal abscess; infant; staphylococcus aureus; stridor.

\*Corresponding author: Email: [achinta.mallick@gmail.com](mailto:achinta.mallick@gmail.com), [mallick.achinta@gmail.com](mailto:mallick.achinta@gmail.com);

## 1. INTRODUCTION

Retropharyngeal abscess (RPA) in children is a rare entity with median age of presentation 3.7–5.1 years [1]. RPA in infants under 6 months has rarely been reported. Younger children often have atypical presentation compared to older children. The youngest age of RPA reported in early infants in literature till the best of knowledge is 3 months [2]. The commonest etiology is assumed to be infection and suppuration of the retropharyngeal lymph nodes draining the nasopharynx, adenoids and posterior nasal sinuses. RPA can cause high morbidity with possible complications like airway compromise, pneumonia, sepsis, carotid artery aneurysm, internal jugular vein thrombosis or even death [3]. Here, we present a rare case of RPA in a 35 day old male infant with atypical presentation, whose prompt diagnosis and immediate surgical intervention had a favourable outcome.

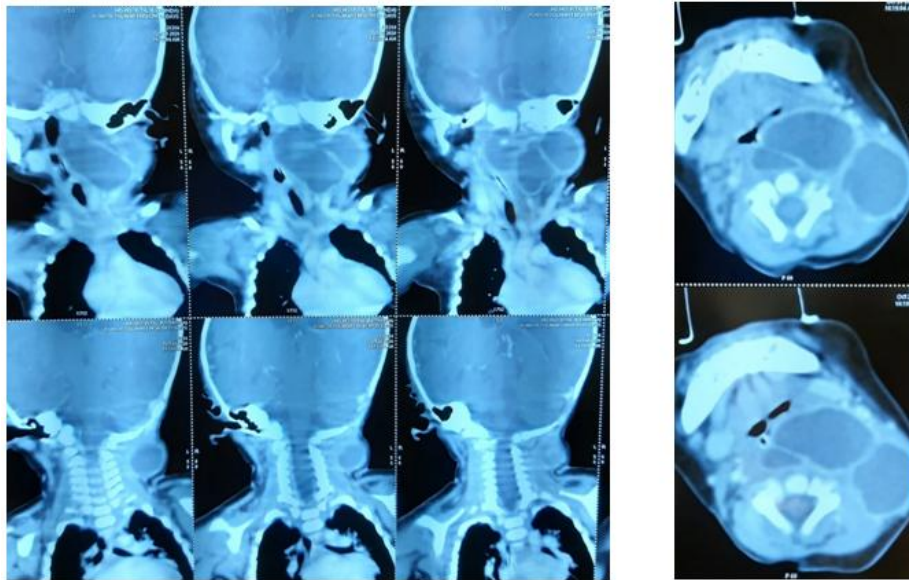
## 2. CASE PRESENTATION

35 days old male infant presented to the emergency department with history of rhinorrhea of 7 days and occasional noisy breathing of 3 days, associated with poor feeding, lethargy and fast breathing since 1 day. On examination the infant was thriving well, weighing 4.3 kg (birth weight of 3.7 kg). But he had toxic look with mottling of skin and cold extremities. There was inspiratory stridor, with suprasternal and subcostal chest retractions. Capillary refill time was prolonged, and SpO<sub>2</sub> at room air was 92-93%. Baby was admitted in NICU, put under warmer, started on oxygen by hood & IV fluids. He was initially managed as Croup with Adrenalin nebulization and antibiotics (Cefotaxime and amikacin), but had poor response. Investigation revealed Hb 10.5 gm/dl, TLC 27,900/mm<sup>3</sup>, DLC P75%, L21% M03% E01%, Plt 10.99 Lacs/mm<sup>3</sup>, CRP was 150 mg/L. Respiratory distress and stridor worsened over next 24 hours. Chest X Ray was normal. Attempt to navigate the nasogastric tube revealed inability to navigate the left nostril. Foreseeing no clinical improvement, USG neck was done which showed 5 x 2.2 cm cystic lesion on left side of neck, with internal echoes. Contrast Enhanced CT neck showed large 5.3 cm x 3.5 cm x 3.4 cm multiloculated peripherally enhancing hypodense mass/collection in neck on left side ( Fig 1 & 2) with its epicentre in retropharyngeal space. The lesion showed significant mass effect displacing the laryngopharynx to right-anteriorly and compromising the laryngeal airway. The

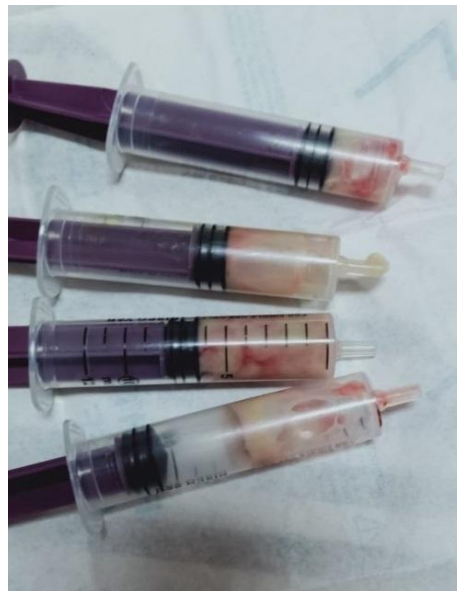prevertebral muscles were also displaced posteriorly suggesting retropharyngeal abscess. A USG guided needle with syringe was inserted and 10 ml of thick pus was aspirated, confirming the diagnosis (Fig. 3). Since the child had worsening distress, a decision for an urgent surgical intervention was made and 75 ml thick yellowish blood stained pus was drained. Feeding tube was inserted and antibiotic cover was upgraded to Meropenem and Vancomycin. Patient responded thereafter with improvement in stridor. Breastfeeding was started after 72 hr. Gram stain of pus showed Gram positive cocci. Aerobic pus culture was done which grew methicillin-resistant *Staphylococcus aureus* (MRSA). The baby made an uneventful recovery and was discharged after 10 days with complete resolution of symptoms. Repeat USG neck showed complete resolution of abscess.

## 3. DISCUSSION

Retropharyngeal abscess (RPA) in neonates and young infants is a rare entity, and often has atypical presentation. They generally occur in older children with mean age of presentation 3.7-5.1 Yr [4-6]. They mainly present with a mass in neck, fever, torticollis and oropharyngeal swelling [7-9]. Neonates and young infants often have atypical presentation, causing diagnostic dilemma for the clinicians. However, stridor has been encountered by some clinicians but it can be seen in laryngomalacia, laryngeal web, vocal cord paralysis as well as subglottic stenosis. Since laryngomalacia & laryngeal webs are congenital, they generally present soon after birth, are benign and without acute life threatening presentation. Subglottic stenosis and vocal cord paralysis are generally precipitated by procedures like traumatic or prolonged intubation. But our patient did not have any such prior history. Other atypical presentations of RPA in these young infants may be sepsis, respiratory distress, neck swelling and hoarseness with weak cry [5,7,8]. Fever has not been commonly encountered [8,9]. Flexible fiberoptic bronchoscopy is often diagnostic but its use is limited because of the paucity of its availability and expertise in such a small baby in a small hospital setting [10]. Retropharyngeal space shares common border with the parapharyngeal spaces bilaterally, containing lymph nodes draining the adenoids, nasopharynx and posterior nasal sinuses. Suppuration of these draining lymph nodes due to upper respiratory infection is postulated to be the commonest etiology of RPA [7,8].



**Fig. 1 & 2. CECT Neck and upper thorax: Contrast enhanced axial and coronal sections of neck and superior mediastinum in the same pediatric patient shows a large multiloculated peripherally enhancing hypodense mass/collection in neck on left side with its epicenter in retropharyngeal space showing significant mass effect in the form of displacement of laryngopharynx to right -anteriorly with severe luminal compromise of the laryngeal air-way. The prevertebral muscles are displaced posteriorly suggesting retropharyngeal origin of this mass/collection**



**Fig. 3. 10 ml thick pus aspirated with USG guided needle aspiration**

As per available literature airway obstruction has been found to have inverse relation with the age of the child with mean age of presentation 1.4 years [11]. Another study found the same to be commonly related with children less than 2 years [12]. The commonest complication of RPA as

described in literature are mediastinitis, airway obstruction, persistence of abscess, sepsis carotid artery aneurysm and Jugular vein thrombosis [6-8]. In older children RPA has been found to be commonly associated with vertebral bone osteomyelitis, foreign body and neck

trauma [13] but are not commonly seen in young infants. X-ray neck may help in the diagnosis but may be missed. USG neck and CECT may clinch the diagnosis but one needs to have such high index of suspicion, mainly attributed to the atypical presentation in these children and are often missed. [13,14] The causative organisms in RPA are most commonly the aerobes like *Staphylococcus aureus*, *Streptococcus pneumoniae*, *Hemophilus influenza*, and few anaerobes like *Bacteroides sp*, *Peptostreptococcus sp*, and *Clostridium sp*. [13] Early surgical intervention of RPA has been advocated by many groups as treatment modality [4,7] while some prefer conservative management with parenteral broad spectrum antibiotics and reserving surgery for any complications [2,15]. However, given the limited information in literature about the different treatment modality in young infants and neonates, higher risk of their airway compromise and septicemia in this subset of population, there are no frank guidelines on their definitive management and surgical intervention may be considered a safer modality in term of favourable outcome. It is also prudent to say that RPA in 35 days old infant has rarely been reported in literature.

#### 4. CONCLUSION

RPA is a rare entity in the neonate and young infants. They often have atypical presentations, which may delay the diagnosis. Hence one needs to have a very high index of suspicion. CECT neck is the investigation modality of choice and early surgical intervention may be needed to prevent airway compromise.

#### DISCLAIMER

The products used for this research are commonly and predominantly use products in our area of research and country. There is absolutely no conflict of interest between the authors and producers of the products because we do not intend to use these products as an avenue for any litigation but for the advancement of knowledge. Also, the research was not funded by the producing company rather it was funded by personal efforts of the authors.

#### CONSENT

As per international standard, parental written consent has been collected and preserved by the author(s).

#### ETHICAL APPROVAL

As per international standard or university standard written ethical approval has been collected and preserved by the author(s).

#### COMPETING INTERESTS

Authors have declared that no competing interests exist.

#### REFERENCES

1. Elsherif AM, Park AH, Alder SC, Smith ME, Muntz HR, Grimmer F. Indicators of a more complicated clinical course for pediatric patients with retropharyngeal abscess. *Int J Pediatr Otorhinolaryngol*. 2010 ;74(2):198-201. Epub 2009 Dec 5. PMID: 19963280.
2. Katavić M, Štefanović I, Vrsalović R, ZlatićGlogoški M, Tešović G, Baudoin T. Retropharyngeal abscess in a four month old female infant case report. *Int J Pediatr Neonatal Care*. 2016;2:121
3. Baldassari CM, Howell R, Amorn M, Budacki R, Choi S, Pena M. Complications in pediatric deep neck space abscesses. *Otolaryngol Head Neck Surg*. 2011;144(4):592-5. Epub 2011 Feb 4. PMID: 21493241.
4. Harkani A, Hassani R, Ziad T, Aderdour L, Nouri H, Rochdi Y, Raji A. Retropharyngeal abscess in adults: five case reports and review of the literature. *ScientificWorldJournal*. 2011;11: 1623-9. Epub 2011 Sep 12. PMID: 22125422; PMCID: PMC3201680.
5. Johnston D, Schmidt R, Barth P. Parapharyngeal and retropharyngeal infections in children: argument for a trial of medical therapy and intraoral drainage for medical treatment failures. *Int J Pediatr Otorhinolaryngol*. 2009;73(5): 761-5. Epub 2009 Mar 17. PMID: 19297031.
6. Lander L, Lu S, Shah RK. Pediatric retropharyngeal abscesses: a national perspective. *Int J Pediatr Otorhinolaryngol*. 2008;72(12):1837-43. Epub 2008 Oct 15. PMID: 18926577.
7. Page NC, Bauer EM, Lieu JE. Clinical features and treatment of retropharyngeal abscess in children. *Otolaryngol Head Neck Surg*. 2008;138(3):300-6. PMID: 18312875.

8. Thompson JW, Cohen SR, Reddix P. Retropharyngeal abscess in children: a retrospective and historical analysis. *Laryngoscope*. 1988;98(6 Pt 1):589-92. PMID: 3374231.
9. Kirse DJ, Roberson DW. Surgical management of retropharyngeal space infections in children. *Laryngoscope*. 2001;111(8):1413-22. PMID: 11568578.
10. Daniel SJ. The upper airway: congenital malformations. *Paediatr Respir Rev*. 2006;7 Suppl 1:S260-3. Epub 2006 Jun 6. PMID: 16798587.
11. Craig FW, Schunk JE. Retropharyngeal abscess in children: clinical presentation, utility of imaging, and current management. *Pediatrics*. 2003;111(6 Pt 1):1394-8. PMID: 12777558.
12. Coulthard M, Isaacs D. Retropharyngeal abscess. *Arch Dis Child*. 1991;66(10):1227-30. PMID: 1953008; PMCID: PMC1793510.
13. Ein SH, Shandling B, Humphreys R, Krajbich I. Osteomyelitis of the cervical spine presenting as a neurenteric cyst. *J Pediatr Surg*. 1988;23(8):779-81. PMID: 3171853.
14. Jevtic V. Vertebral infection. *Eur Radiol*. 2004 Mar;14 Suppl 3:E43-52. PMID: 14749956.
15. Sichel JY, Dano I, Hocwald E, Biron A, Eliashar R. Nonsurgical management of parapharyngeal space infections: a prospective study. *Laryngoscope*. 2002;112(5):906-10. PMID: 12150626.

© 2022 Mallick et al.; This is an Open Access article distributed under the terms of the Creative Commons Attribution License (<http://creativecommons.org/licenses/by/4.0>), which permits unrestricted use, distribution, and reproduction in any medium, provided the original work is properly cited.

*Peer-review history:*  
*The peer review history for this paper can be accessed here:*  
<https://www.sdiarticle5.com/review-history/84565>