

Analysis of Orthopedic Surgery for Long Bone Metastases and Pathologic Fractures

A. I. Radchenko^{1*}, A. G. Zhukovets² and Y. M. Bogdayev¹

¹*N. N. Alexandrov National Cancer Centre, Minsk, Belarus.*

²*Department of Oncology, Belarusian Medical Academy of Post-Graduate Education, Minsk, Belarus.*

Authors' contributions

This work was carried out in collaboration between all authors. Author AIR designed the study, performed the statistical analysis, wrote the protocol and wrote the first draft of the manuscript. Authors AGZ and YMB managed the analyses of the study. Author YMB managed the literature searches. All authors read and approved the final manuscript.

Article Information

DOI: 10.9734/JCTI/2017/36830

Editor(s):

(1) Sung-Chul Lim, Industry-Academic Cooperation Foundation, Chosun University, South Korea.

Reviewers:

(1) Serkan Degirmencioglu, Pamukkale University, Turkey.

(2) Duncan Mugala, Copper Belt University, Zambia.

(3) Bassam Abdul Rasool Hassan, Universiti Teknologi MARA, Malaysia.

Complete Peer review History: <http://www.sciencedomain.org/review-history/21411>

Received 19th September 2017

Accepted 10th October 2017

Published 14th October 2017

Original Research Article

ABSTRACT

The study made a retrospective analysis of treatment outcomes in 105 patients subjected to 128 surgical interventions for metastatic involvement of long tubular bones. Endoprosthetic replacement of large joints (40.2%) and intramedullary osteosynthesis (29.7%) were the main types of surgical interventions. The postoperative morbidity rate was 24.2%. The treatment administered made it possible to preserve extremity functioning in 85.7% of the patients and to significantly improve their quality of life, with one-year survival rate being 62.0%, 3-year – 28.5%, 5-year – 11.4%. Lung cancer, the presence of visceral metastases and the time of distant metastasis development were proved to be the unfavourable prognostic factors.

Keywords: Long bone metastases; surgical treatment; quality of life; functional result.

*Corresponding author: Email: aradchenko@mail.ru;

1. INTRODUCTION

Over the past decade, owing to the comprehensive approach and introduction of new antitumor drugs and radiotherapy techniques, as well as to the improvement of diagnostic methods, the survival of patients with malignant tumors significantly ameliorated. A considerable increase in the number of long-living patients with distant metastases is the consequence of these encouraging results.

Skeletal bones rank third after lung and liver in the metastatic involvement rate [1]. Up to 80% of bone metastases develop from malignant tumors of prostate, breast, thyroid, lung and kidney [2]. Most common metastases of solid tumors are in spine (up to 70%), pelvic bones (up to 40%) and lower extremity (up to 32%). Of the long tubular bones, metastatic disease mainly affects femoral (24%), humeral (13%) and tibial (6%) bones [3].

The following treatments are employed for most of the patients with bone metastases: systemic chemo- and hormonotherapy, bisphosphonates, external-beam radiotherapy, radionuclide therapy; they make it possible to attain a satisfactory symptomatic analgetic effect in two thirds of the patients and to achieve different levels of the neoplastic disease control [4]. Nevertheless, bone metastases are complicated with pathologic fractures in 10-25% of the cases [5].

The treatment of choice of metastatic lesions of long tubular bones should be based on a location of metastatic focus, extent of bone destruction, the presence of pathologic fracture, nosological form of a tumor as well as the degree of functional limb impairment and the patient's expectations. Nowadays there have been only a few reports concerning the development of surgical treatment options for management of bone metastasis [6,7]. In this regard, surgical treatment of metastatic bone disease is performed on the general principles underlying the management of oncology and traumatology and often - on surgeon's preference.

The present study analyzes the results of surgical treatment of long tubular bones affected by metastases to identify how it impact on survival, quality of life and functional results.

2. MATERIALS AND METHODS

The study enrolled 105 patients subjected to 128 surgical interventions for metastases in long

tubular bones. The median age of the patients is 57.8 years. In most cases the patients had metastasis from renal cancer (51 [48.6%]), breast cancer (23 [21.9%]) and lung cancer (11 [10.5%]).

The metastatic sites were mainly in femoral (71.7%) and humeral (18.6%) bones. A single bone metastasis was diagnosed in 36 (34.3%) patients, multiple metastases in 23 (21.9%). At presentation, 74 (70.5%) patients had pathologic fractures of long tubular bones. A menace of pathological fracture existed in 20 (19.0%) cases (the mean value of Mirels score 9.6). In 5 (4.8%) patients, the bone metastasis was the only manifestation of the neoplastic disease. Bone metastasis-related pain syndrome uncontrolled by conservative therapies occurred in 6 (5.7%) cases.

Extrasosseous metastases concurrent with bone metastases were diagnosed in 45 (42.9%) patients. A solitary lung lesion was found in 23 (51.1%) cases, liver – in 4 (8.9%), brain – in 4 (8.9%), adrenal – in 3 (6.7%). The involvement of two or more internal organs was diagnosed in 11 (24.4%) patients.

Chemotherapy before or after bone metastasis resection was administered to – 43 (41.0%) patients. Radiation treatment of bone metastases prior to surgery was performed in 11 (10.5%) cases, and in 15 (14,3%) in the postoperative period.

The data on the types of surgical interventions are presented in Table 1.

Extremity amputation was carried out in 2 cases because of bulky metastatic tumor invading great vessel structures, and in 6 cases due to the onset of complications, local recurrence or continuing tumor growth after surgical treatment.

Surgical removal of the primary tumor was performed in 19 (43.2%) of 44 patients with newly diagnosed stage IV disease. Primary tumor excision prior to surgical treatment of bone metastases was conducted in 12 (27.3%) cases, simultaneously with primary tumor ablation in 2 (4.5%), after surgical removal of bone metastases in 5 (11.4%). Six patients underwent surgical intervention on two metastatic foci, one patient – on 3 foci in long tubular bones.

The quality of life and the functional status of the extremity were assessed before surgery and 3 to

5 months after it. In case of recurrent disease or complication in the course of 3 months after the surgical treatment, the quality of life was assessed 3 months after operative exploration.

To assess the quality of life, EORTCQLQ-C30 questionnaire, v.3 was used.

The functional status of upper and lower extremities was assessed using the MSTS score (Musculo-Skeletal Staging System, 1993). Statistical processing of the results was fulfilled with Statistica 6.0 software package. The survival rates were calculated with Kaplan-Meier method. The statistical significance of the effect of various factors on survival was evaluated using the log-rank test ($p < 0.05$).

To compare life quality indices and the extremity functioning in the patient groups, the non-parametric Mann-Whitney test was employed; the non-parametric Wilcoxon test was used to assess the changes in the quality of life and the

extremity functioning. The revealed patterns and relations of the parameters studied between groups and criteria were considered statistically significant with $p < 0.05$.

3. RESULTS AND DISCUSSION

Organ-sparing surgical interventions for bone metastases allowed to save the extremity functioning in 85.7% of the patients. The postoperative morbidity rate was 24.2% (Table 2).

The mean time periods of complication development after osteosynthesis, endoprosthetic replacement with metal prostheses and allografts were 5.5 months, 15.7 months and 1.6 months, respectively.

The bridging of bone defects with endoprostheses was performed in 40.2% of the cases. The total morbidity rate for endoprosthetic replacement was 17.6% (9/51). Infection with

Table 1. Types of surgical interventions, taking into account repeat operations associated with complications and recurrences

No	Type of surgery	n (%)
1.	Endoprosthetic replacement	
2.	hip joint	41 (32.0%)
3.	knee joint	7 (5.5%)
4.	shoulder joint	3 (2.3%)
5.	Intramedullary osteosynthesis	35 (27.4%)
6.	Episeous osteosynthesis	3 (2.3%)
7.	Alloplasty with locking intramedullary nail fixation	16 (12.5%)
8.	Fibular bone autoplasty	2 (1.6%)
9.	Metastasis resection without reconstructive surgery	3 (2.3%)
10.	Curettage with cement plasty	10 (7.8%)
11.	Amputation / exarticulation	8 (6.3%)
Total		128 (100%)

Table 2. Information about local postoperative complications and the number of operative explorations

Complication	Reconstruction technique					
	Endoprosthetic replacement n=51		Osteosynthesis n=38		Alloplasty n=16	
	n (%)	Operative explorations n (%)	n (%)	Operative Explorations n (%)	n (%)	Operative explorations n (%)
Infection	5 (9,8%)	2 (3,9%)	–	–	5 (31,3%)	5 (31,3%)
Construction instability	4 (7,8%)	3 (5,9%)	1 (2,6%)	–	–	–
Fracture of the construction	–	–	3 (7,9%)	1 (2,6%)	–	–
Local tumor growth	–	–	7 (18,4%)	6 (15,8%)	–	–
Total, %	9 (17,6%)	5 (9,8%)	11 (28,9%)	7 (18,4%)	5 (31,3%)	5 (31,3%)

replacement developed in 5 cases, in two of them replacement of the endoprosthesis was necessary. Hip joint prosthesis dislocation occurred in 3 patients; in two of them, the endoprosthesis was repositioned, and in the third case extremity exarticulation was needed because the dislocation was accompanied with postoperative wound diastasis and hemorrhage. One patient developed aseptic instability of knee joint endoprosthesis, making it necessary to perform operative exploration with replacing the femoral component of the prosthesis.

Episeous and intramedullary osteosynthesis was done in 29.7% of the cases. The total morbidity rate for this reconstruction technique was 28.9% (11/38). Further tumor growth in the fracture area was observed in 7 cases, which required resection of the affected bone part with subsequent endoprosthetic replacement in 6 patients and extremity amputation in one. The fixing construction fracture in the absence of fracture consolidation occurred in 3 cases, in one of them bone resection with endoprosthetic replacement was performed. Pathological bone fracture in the distal part of the intramedullary nail was found in one patient.

The bridging of articular and diaphyseal defects with a massive allograft was carried out in 12.5% of the cases. The infection rate in alloplasty amounted to 31.3% (5/16). The development of infectious morbidity required a repeat surgical intervention: extremity amputation was

performed in 4 cases and autoplasty with fibular shaft in one.

The local continuing growth of the tumor and onset of recurrence were detected after 5 months and 17.4 months on the average, respectively. They were most common renal cell cancer metastases. So after nonradical surgical resection (osteosynthesis, cement plasty), the continuing growth led to recurring extremity dysfunction in 53.3% of the cases (8/15).

The results of overall survival calculation were as follows: 1-year survival 62.0% (95% confidence interval [CI]: 56.9 – 67.1), 2-year survival – 45.9% (95% CI: 40.1 – 49.9), 3-year survival – 28.5% (95% CI: 23.3 – 33.7), 5-year survival – 11.4% (95% CI: 7.0 – 15.8) (median survival 20 months). Progression-free 5-year survival was 4.8% (5 patients).

The analysis of survival rates found statistically significant differences related to the extent of tumor spread, time of distant metastasis development, tumor pathology, type of surgical treatment and onset of local recurrence (Table 3).

Lung cancer, the presence of visceral metastases and the time of distant metastasis development (less than 6 months after primary tumor detection) proved to be the unfavourable prognostic factors.

Table 3. Survival of patients with bone metastases

Indices	Number of patients	Survival			P value
		1-year	3-year	Median (months)	
Extent of tumor spread					0.001
Only bone metastases	60	73.9±6.0	36.7±7.1	27.8	
Bone metastases and visceral metastases	45	45.7±8.1	15.8±6.9	11.6	
Time of distant metastasis development after primary tumor detection					0.03
≤ 6 months	49	59.6±9.1	19.5±8.4	19.3	
> 6 months	56	65.6±6.8	54.7±7.2	26.8	
Primary tumor					0.007
Renal cancer	51	69.5±6.8	28.0±7.4	26.0	
Breast cancer	23	62.2±10.6	24.6±10.2	15.7	
Lung cancer	10	40.0±15.5	–	4.0	
Bone metastasis resection					0.001
Radical	31	83.7±6.7	46.9±10.2	35.4	
Nonradical	74	51.3±6.4	19.1±5.5	12.7	
Local recurrence					0.004
Yes	13	87.5±11.7	72.9±16.5	42.3	
No	92	59.2±5.4	23.6±5.2	17.0	

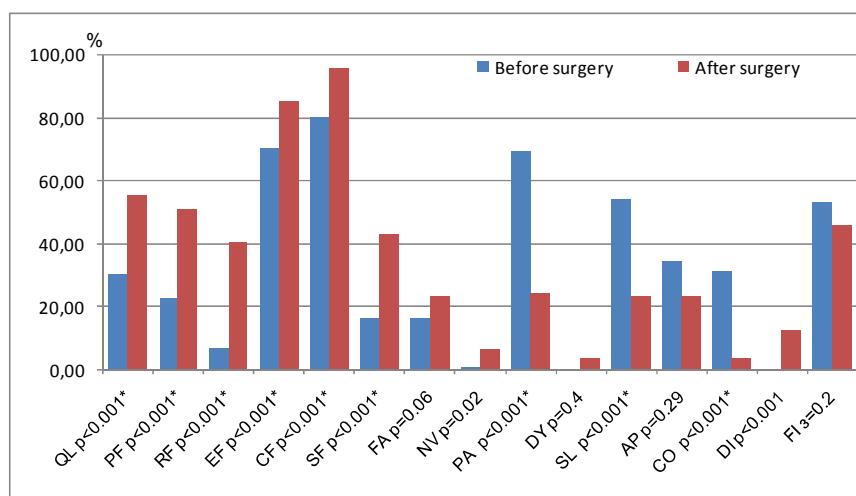


Fig. 1. Median values of life quality scales before surgical treatment and 3 months after it

**statistically significant differences*

Local recurrence was noted, as a rule, in long-living patients.

The statistically significant difference in the survival rates of patients with radical and nonradical excision of bone metastasis was determined by the fact that the magnitude of the surgical intervention was based on patient life expectancy.

Gender, age, presence of pathologic fracture, systemic treatment, postoperative morbidity did not have a statistically significant effect on survival.

A significant improvement of extremity functioning after surgical treatment was observed in the overwhelming majority of the cases. The mean MSTS score value increased from 5.4 (SD±5.2) to 16.7 (SD±6.6) ($p \leq 0.001$) 3 months after surgical treatment.

The functional result was regarded as satisfactory in 79.5% of the cases. Unsatisfactory functional result was ascertained for lower extremity bone osteosynthesis in 20.0% of cases, as well as in 3 cases of knee joint replacement with allograft.

The monitoring of life quality indices in patients with metastatic involvement of long tubular bones has demonstrated a significant decline in physical (48%), role (40%) and social (42%) functions, as well as in the performance status

(53%) before surgical treatment. The symptoms atypical for the clinical presentation of bone metastases (diarrhea, dyspnea, nausea, asthenia) before surgical treatment were observed in single cases.

The surgical treatment of metastatic disease resulted in a statistically significant improvement in all functional scales, performance status, and also in diminishing complaints of pain, insomnia and constipation (Fig. 1).

Three months after surgery, the most common patient complaints were stool derangements and nausea. This may be related to the fact that most of the patients received systemic antitumor therapy during that period.

4. CONCLUSIONS

Thus, active surgical policy is indicated for patients with metastases in tubular bones, in the presence of pathologic fracture or its threat, their general condition being satisfactory. Such policy enables not only to improve the extremity functioning, to alleviate the pain syndrome and to enhance the quality of life but also arrange settings for timely special treatment.

In the cases of a single bone metastasis, as well as in those of stable disease, it is rational to perform an extensive radical resection of the bone with metastatic involvement, and single-step endoprosthetic replacement.

Osteosynthesis is a preferable option for surgical management of pathologic fractures in patients with poor prognosis, if only the clinical situation does not require endoprosthetic replacement (the metastatic site in the intertrochanterian area, and also in femoral neck or head).

Visceral metastases are not a contraindication to surgical treatment of metastases in tubular bones. With this in mind, the choice of the extent of metastasis and affected bone resection, as well as of the technique for bone defect elimination should be made with regard to the expected efficacy of systemic antitumor treatment and the anatomic site of metastatic disease in the bone.

CONSENT

It is not applicable.

ETHICAL APPROVAL

It is not applicable

COMPETING INTERESTS

Authors have declared that no competing interests exist.

REFERENCES

1. Weber K, et al. Management of lower-extremity bone metastasis. *J Bone Jt Surg Am.* 2006;88(4):11–19.
2. Galasko C. The anatomy and pathways of skeletal metastases. In: Weiss L., Gilbert A., eds. *Bone metastases.* Boston: GK Hall. 1981;49–63.
3. Bauer HCF. Controversies in the surgical management of skeletal metastases. *J. Bone Joint Surg.* 2005;87:608–17.
4. Ratasvuori M, et al. Prognostic role of en-bloc resection and late onset of bone metastasis in patients with bone-seeking carcinomas of the kidney, breast, lung, and prostate: SSG study on 672 operated skeletal metastases. *J Surg Oncol.* 2014; 110:360–365.
5. Saad F, et al. Pathologic fractures correlate with reduced survival in patients with malignant bone disease. *Cancer.* 2007;110:1860–7.
6. Ruggieri P, Mavrogenis AF, Casadei R, Errani C, Angelini A et al. Protocol of surgical treatment of long bone pathological fractures. *Injury.* 2010;41(11):1161-67. DOI: 10.1016/j.injury.2010.09.018
7. Willeumier JJ, van der Linden YM, van de Sande MAJ, Dijkstra PDS. Treatment of pathological fractures of the long bones. *EFORT Open Rev.* 2016;1:136-45. DOI: 10.1302/2058-5241.1.000008

© 2017 Radchenko et al.; This is an Open Access article distributed under the terms of the Creative Commons Attribution License (<http://creativecommons.org/licenses/by/4.0>), which permits unrestricted use, distribution, and reproduction in any medium, provided the original work is properly cited.

Peer-review history:
The peer review history for this paper can be accessed here:
<http://sciencedomain.org/review-history/21411>