



Hysteroscopic Finding in Patients with Secondary Infertility at Tanta University Hospitals

**Enas Gamal Kabeil ^{a*}, Mai Nabil Ageez ^a, Adel Elsayed Algergawy ^a
and Ahmed Hussein Abu Freikha ^a**

^a *Obstetrics and Gynecology Department, Faculty of Medicine, Tanta University, Egypt.*

Authors' contributions

This work was carried out in collaboration among all authors. All authors read and approved the final manuscript.

Article Information

DOI: 10.9734/JAMMR/2022/v34i1331373

Open Peer Review History:

This journal follows the Advanced Open Peer Review policy. Identity of the Reviewers, Editor(s) and additional Reviewers, peer review comments, different versions of the manuscript, comments of the editors, etc are available here: <https://www.sdiarticle5.com/review-history/84715>

Original Research Article

Received 11 January 2022

Accepted 22 March 2022

Published 02 May 2022

ABSTRACT

Background: About 7.5% of married couples experience infertility. It has been reported that an abnormal uterine finding occurs in approximately 40% of infertile women. The aim of this study was to evaluate the role of Hysteroscopy in diagnosing the abnormalities of the uterine cavity among female having secondary infertility at Tanta University Hospitals.

Methods: This study was conducted on 80 women referred for diagnostic hysteroscopy due to secondary infertility. All patients were subjected to complete history taking, clinical examination and routine laboratory investigation. Patients also were subjected to vaginal speculum examination, ultrasound, hysteroscopic examination and hysteroscopic septum resection, hysteroscopic myomectomy.

Results: The mean age of the included cases was 31.46 ± 6.07 years, and their median age was 30 years with range 19 and 40 years. The highest percentage of the included cases were in the age group between 19 and 30 years (56.25%) followed by the age group between 31 and 40 years (53.75%). There were 41 housewives (51.3%) and the remaining 39 (48.7%) were working. The highest percentage of the cases came from rural areas (61.3%) and 38.7% from urban areas.

Conclusions: Our data are an additional argument to suggest hysteroscopy as part of investigation in infertile woman. Routine diagnostic hysteroscopy and ultrasound should be part of an infertility workup secondary infertility. Obesity is associated with hormonal derangement which are responsible for infertility weight loss should be considered as a first line treatment.

Keywords: Hysteroscopic; secondary; infertility.

1. INTRODUCTION

About 7.5% of married couples experience infertility [1]. It has been reported that an abnormal uterine finding occurs in approximately 40% of infertile women [2].

Most endometrial pathologies implicated in infertility result in both structural and functional impairments [3]. Therefore, endometrial cavity assessment should be included in the evaluation of infertile couples. This can be done through transvaginal sonography, hysterosalpingography, sono-hystero-graphy and hysteroscopy [4].

The goal of uterine cavity evaluation is either to identify structural abnormalities such as polyps, myomas, or uterine septum or to obtain a sample of the endometrium (hyperplasia or neoplasia). Hysteroscopic examination is probably superior to hystero-graphy in evaluating the endometrial cavity [5].

Furthermore; abnormal hysteroscopic findings have been reported in patients with normal hystero-graphy or transvaginal ultrasonography. Hysteroscopy has been proven to have superior sensitivity and specificity in evaluating the endometrial cavity [6].

Mini-hysteroscopies allow for the performance of uterine cavity evaluation in an office setup, with or without local anesthetics, for diagnostic and certain therapeutic interventions [7].

However, the World Health Organization (WHO) recommends hysterosalpingography (HSG), alone, for management of infertile women probably because of its ability to provide information regarding tubal patency [8].

Nevertheless, hysteroscopy is a more accurate tool because of the high false-positive and false negative rates of intrauterine abnormality with HSG [9].

Furthermore, usage of Hysteroscopy can play an important role in detecting intrauterine pathologies in In Vitro Fertilization (IVF) patients. Therefore, it may have a positive impact on pregnancy outcome and treatment costs [10].

In addition, abnormal hysteroscopic findings are significantly higher in patients with previous

assisted reproductive technique failure and hysteroscopy could be seen as a positive prognostic factor for achieving pregnancy in subsequent In vitro fertilization (IVF) procedure in women with a history of recurrent induced fertilization (RIF) [11].

The aim of this study was to evaluate the role of hysteroscopy in diagnosing the abnormalities of the uterine cavity among female having secondary infertility at Tanta University Hospitals.

2. PATIENTS AND METHODS

This study was conducted on 80 women referred for diagnostic hysteroscopy due to secondary infertility at Tanta University Hospitals from inpatient department, Obstetrics and Gynecology Department, from June 2020 to May 2021. Women who were diagnosed as secondary infertility, age is > 18 and < 40 years, twelve months or more with regular unprotected sexual were included.

Any contraindication to hysteroscopy e.g., untreated cervicitis, bleeding tendencies or pregnancy, suspicious cervix, women who refuse to join the study, clinical suspicion of pelvic inflammatory disease were excluded.

All patients in this study were subjected to the following:

History taking: personal (age, duration of marriage, special habits), menstrual: regularity of the cycle length of the cycle and amount of flow (LMP), obstetric (gravidity, parity, mode of delivery, fetal outcome and type of abortion if found), present and past history of any medical problems, contraceptive history, family history, personal, medical, surgical and family history of her partner and complete general examination (vital signs including blood pressure, pulse, temperature and all body systems examination (cardiac, chest and abdominal examination as a routine checkup, vaginal speculum examination) to exclude local causes of infertility, routine laboratory investigations (complete blood count, prothrombin time and activity, liver function, kidney function), ultrasound: trans vaginal and trans abdominal to detect other causes of infertility by showing myometrium (fibroid), endometrium (structure, polyo, submucosal fibroid), ovaries (follicles, cysts), adnexa

(hydrosalpinx), cul-de-sac, (endometriosis) and cervix for cervical polyp.

Hysteroscopy examination was performed as inpatient procedure at the follicular phase under general endotracheal anesthesia.

The Hysteroscopic Examination was performed using a rigid hysteroscope (continuous flow; 30-degree forward-oblique view) assembled in a 4-mm diameter diagnostic sheath. A high-intensity cold light source and fiberoptic cable were used to illuminate the uterine cavity.

Normal saline (0.9%) was used as the distention medium, keeping the pressure between 100- and 120-mm Hg using hystromat (infusion pump), with the aim to adequately distend uterine cavity allowing good visualization. After explanation of the procedure the patient was asked to empty her bladder. The patient was lying in the lithotomy position. Normal saline was used as a distention media for uterine distension connected to the inflow channel on the sheath. A vaginal disinfection with povidone iodine 10% without placing speculum was done.

The tip of the hysteroscopy was positioned in the vaginal introitus, the labia being slightly separated with fingers. The vagina was distended with saline. The scope was driven to the posterior fornix to readily visualize the portion and slowly backwards anterior to identify the external cervical os. When this became visible, the scope was carefully moved forward to the internal os. And then to the uterine cavity with least possible trauma.

The uterine cavity was systematically explored in a panoramic view by rotating the fore-oblique scope in order to identify any anomaly in the uterine walls and the right and left tubal ostia.

2.1 Hysteroscopic Septum Resection

It is simply localized fibromuscular overgrowth at the center of the uterus seen by hysteroscopy as midline projection separate the uterine cavity into two halves. The septum is cut by the hysteroscopic micro scissors to reshape the uterine cavity to it is normal shape so gentle cuts were made in the intervening bridge. The initial part of the septum is fibrous and does not have blood supply but as we go deeper more and more areas richly supplied with blood vessels which is a good sign that mean that the uterus is

now getting back to it is normal content Hysteroscopic Polypectomy.

The polyp cut from its origin by hysteroscopic micro scissors. Because we used a magnification up to twenty times the normal size the tissue, the tissues appear magnified and precise clear surgery can be performed. once the polyp has been detached held with grasping forceps and gently removed from the patient by hysteroscopic grasper and inspected and sent for histopathology. For proper hysteroscopic myomectomy proper case selection, good instrumentation, good surgical technique and fluid balance have been done. Firstly, by ultrasound fibroid appear hypo echoic and a polyp appear hyper echoic. The cases selected according to LASMAR score. Sub mucus fibroid grades 0 and 1 undergo hysteroscopic removal. The size, grade, and location of the base identified and decided how myoma resection will be done. Once resection started resection started from tip to base.

Don't cut stalk directly as fibroid will be loose. the loop pulled toward the surgeon.as cutting continued strips taken till complete strip detached. Multiple small strips of the fibroid left in the uterine cavity. The maximum possible mass resected at a time with avoidance of frequent removal and reinsertion of the hysteroscope as this increase the possibility of air embolism

In type 2 myoma vigorous uterine massage needed to shift the fibroid toward the uterine cavity making it easily approachable for resection. Intramural fibroid just touching the endometrial lining so fibroid mapping carefully done by ultrasound preoperative and after the first endometrial cut the fibroid become visible and with using gentle mechanical force the fibroid pushed away from it is attachment to the myometrium.as this process continues the fibroid seem to be shift toward the uterine cavity a completely seen so now it is easily resected with minimal risk of perforation of the uterine cavity.

- All work done with low pressure
- Chronic endometritis (C.E).
- Hysteroscopic diagnosis of chronic endometritis was based on demonstration of endometrial congestion, stromal edema, many white points, and blood vessels over the surface, micro polyps and focal or diffuse hyperemia. When there were not abnormalities the distending flow was stopped, and 5 ml of 1% methylene blue

dye was introduced through the Hysteroscopic inlet and waiting for 5 minutes then the distending medium flow was started again washing the endometrium.

- Then, the endometrium was visualized for staining pattern:
- Diffuse light blue staining was considered normal
- Focal dark blue staining above the cervical ostium was considered positive finding.
- After diagnostic hysteroscopy, the scope was removed then endometrial biopsy was taken by a Novak' curette and specimens sent for histopathological and microbiological

2.2 Statistical Analysis

Statistical analysis was done by SPSS v26 (IBM Inc., Chicago, IL, USA). Quantitative variables were presented as mean and standard deviation (SD). Qualitative variables were presented as frequency and percentage (%) and were analysed utilizing the Chi-square test or Fisher's exact test when appropriate.

3. RESULTS

The mean age of the included cases was 31.46 ± 6.07 years, and their median age was 30 years

with range 19 and 40 years. The highest percentage of the included cases were in the age group between 19 and 30 years (56.25%) followed by the age group between 31 and 40 years (43,75%).

The mean BMI of the included cases was 29.46 ± 2.2 kg/m² and their median BMI was 29.5 kg/m² with range 24 and 36.68 kg/m². There were 10 cases (12.5%) with normal BMI, 40 cases (50%) overweight and 30 cases (37.5%) obese. There was a statistically significant increase in the overweight and obese cases as compared with the cases with normal weight (P < 0.001).

There were 41 housewives (51.3%) and the remaining 39 (48.7%) were working. The highest percentage of the cases came from rural areas (61.3%) and 38.7% from urban areas.

There were 31 cases (38.3%) primigravida, 34 cases (42.5%) were second gravida, 11 cases (46.5%) third gravida, 1 case (1.3%) was fourth gravida and 3 cases (3.8%) fifth gravida. Among the included cases, there were 20 nullipara (25%), 39 cases (48.8%) had previous single delivery and 20 cases (25%) had previous two deliveries. Among the included cases there were 35 cases (46,2%) with history of previous abortion.

Table 1. Patients' characteristics of the studied patients

| Items | | Study cases (n=80) |
|-------------------------------|------------------|---------------------------------------|
| | Mean ± SD | 31.46 ± 6.07 |
| Age (years) | Median (min-max) | 30 (19-40) |
| Age group | | |
| 19-30 years | | 45 (56.25%) |
| 31-40 years | | 35 (43.75%) |
| BMI (Kg/m²) | Mean ± SD | 29.46 ± 2.2 |
| | Median (min-max) | 29.5 (24-36.68) |
| BMI groups | | |
| Normal | | 10 (12.5%) |
| Overweight | | 40 (50%) |
| Obese | | 30 (37.5%) |
| test of significance | | $\chi^2 = 9.645$ P < 0.001* |
| Occupation | | |
| Housewife | | 41 (51.3%) |
| Worker | | 39 (48.7%) |
| Residence | | |
| Rural | | 49 (61.3%) |
| Urban | | 31 (38.7%) |

BMI: body mass index, Continuous data expressed as mean ± SD and median (range) Categorical data expressed as Number (%)

Table 2. Obstetric history in the study cases

| Items | Study cases (n=80) |
|------------------|--------------------|
| Gravidity | |
| 1 | 31 (38.8%) |
| 2 | 34 (42.5%) |
| 3 | 11 (46.5%) |
| 4 | 1 (1.3%) |
| 5 | 3 (3.8%) |
| Parity | |
| 0 | 20 (25%) |
| 1 | 39 (48.8%) |
| 2 | 21 (26.3%) |
| Abortion | |
| 0 | 35 (43.8%) |
| 1 | 31 (38.8%) |
| 2 | 6 (7.5%) |
| 3 | 5 (6.3%) |
| 4 | 3 (3.8%) |

Categorical data expressed as Number (%)

Regarding transvaginal US in the cases included in the study. Normal findings were detected in 30%, Arcuate Uterus in 10% where a normal external uterine contour, with abroad smooth indentation on the fundal segment of the endometrium., % Uterine septum in 17,5%, Uterine polyp in 12.5%, Endometrial fibroid in 8.75%, Cervical polyp in 3.75%, Chronic endometritis in 1.25 %where endometrium appear bright, hyperechoic, with mild free fluid and thickened endometrium, Dehiscence of C.S scar in 5% Size of the cesarean scar dehiscence. Scar defect may be large or small. The defect described from the depth of indentation from the cervical canal or by measurement of residual myometrium small defect is less than 2 ml in depth, large defect described when residual myometrium less than 2 or 3 ml or the depth of indentation greater than 50 to 80 % of myometrial thickness, Intrauterine adhesion in 2.5% and PCO in 2.5%.

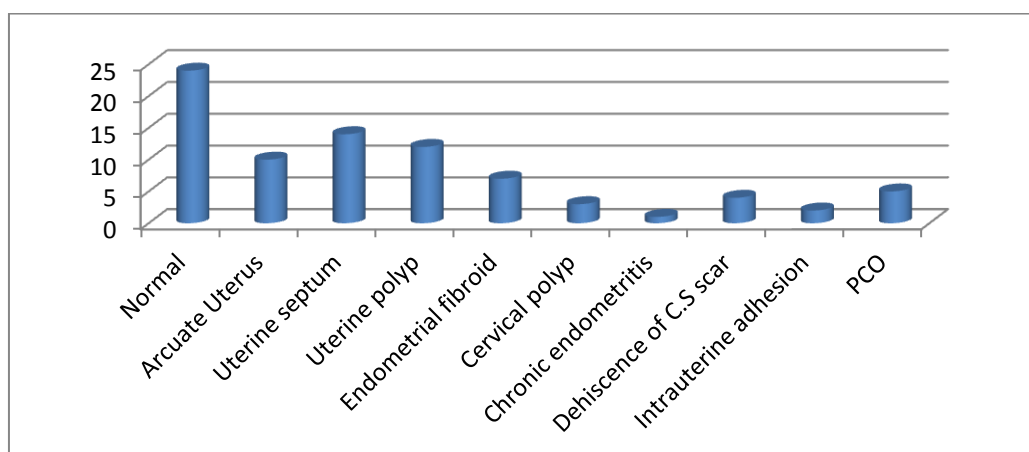


Fig. 1. Findings of transvaginal US in the cases of the study

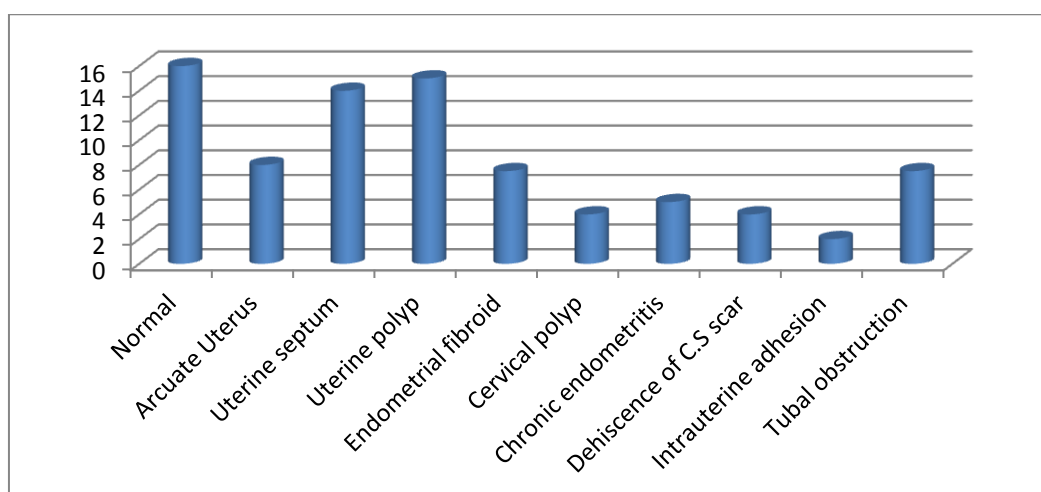


Fig. 2. Findings of hysteroscope in the cases of the study

Regarding findings of hysteroscope in the cases included in the study. Normal findings were detected in 20%, Arcuate Uterus in 10%, Uterine septum in 17.5%, Uterine polyp in 18.75%, Endometrial fibroid in 7.5%, Cervical polyp in 5%, Chronic endometritis in 6.25%, Dehiscence of C.S scar in 5%, Intrauterine adhesion in 2.5% and tubal obstruction in 7.5%.

4. DISCUSSION

Office hysteroscopy (OH) is increasingly recommended by many studies as a routine procedure in the infertility work up because office hysteroscopy has the advantages of faster ambulation, enhanced cost effectiveness and reduced anesthesiologic risks [12].

The mean age of the included cases was 31.46 ± 6.07 years, and their median age was 30 years with range 19 and 40 years. The highest percentage of the included cases were in the age group between 19 and 30 years (56.25%) followed by the age group between 31 and 40 years (53.75%). There were 41 housewives (51.3%) and the remaining 39 (48.7%) were working. The highest percentage of the cases came from rural areas (61.3%) and 38.7% from urban areas.

However, in the study of Meng et al., [13] reported that at enrollment, the mean age was 24.0 ± 3.6 years for women.

Agree with this study Sahu et al., [14] they demonstrated that age <30 years were 177 (54.62%) patients and 147 (45.38%) were of >30 years.

Also agree with this study, Sami et al., [15] revealed that the mean age of cases of secondary infertility and controls was similar (29.0 ± 4.9 vs. 29.2 ± 4.7 year). As compared to controls, a smaller proportion of women among cases was literate and employed (43.5% vs. 47.3% and 12.5% vs. 24.0% respectively). Similar trend was observed for literacy status of spouses of cases and controls.

The present study showed that the mean BMI of the included cases was 29.46 ± 2.2 kg/m² and their median BMI was 29.5 kg/m² with range 24 and 36.68 kg/m². There were 2 cases (2.5%) with normal BMI, 46 cases (56.1%) overweight and 32 cases (40%) obese. There was a statistically significant increase in the overweight and obese cases as compared with the cases

with normal weight ($P < 0.001$). However, in the study of Yadav et al., [16] the mean BMI of their studied group was 25.41 ± 3.41 Kg/m². In the study of Meng et al., [13] approximately 80% of the women had a BMI of 15–25 kg/m².

The epidemiology of secondary infertility is not well understood. In developing countries, infections are the leading cause of secondary infertility among women. Of these, sexually transmitted infections (STIs) as well as infections strewn through iatrogenic factors, unsafe termination of pregnancy, and unsafe birthing practices have been identified as causes of secondary infertility in women from developing countries [17].

There is a dearth of information on prevalence of and factors associated with secondary infertility. However, there is evidence of unsafe practices commonly opted by service providers as well as by women during childbirth and postpartum period, resulting in pelvic inflammatory diseases (PID), tubal blockage and infertility [18].

The current study showed that there were 31 cases (38.3%) gravida one, 34 cases (42.5%) were second gravida, 11 cases (46.5%) third gravida, 1 case (1.3%) was fourth gravida and 3 cases (3.8%) fifth gravida. Among the included cases, there were 20 nullipara (25%), 39 cases (48.8%) had previous single delivery and 20 cases (26.3%) had previous two deliveries. Among the included cases there were 45 cases (46.2%) with history of previous abortion.

Agree with this study, Sahu et al., [19] in the group with secondary infertility, the parity ranged from 1 to 2, the spontaneous abortions ranged from 0 to 7, and induced abortions ranged from 0 to 2.

In contrast of this study Yadav et al., [20] demonstrated that mean age of the study group was 43.49 ± 4.42 yrs and average parity was 3.

According to Dhont et al., [21] of the 312 fertile women enrolled in the control group, 29 reported to have tried more than one year for the previous pregnancy and 64 had only one pregnancy in the past, leaving 219 fertile women for this analysis. Emmanuel et al., [18] reported that association with secondary infertility was found with a history of unsafe abortion (adjusted odds ratio [AOR] = 9.3607, confidence interval [CI] = 3.7664–23.2645). Meng et al., [13] found that fifteen per cent of the women had a history of previous

pregnancy, and 9% of them had experienced previous spontaneous abortions.

Uterine factors are responsible for 2-3% of infertility cases and intra-uterine lesions are much more common in infertile women (40-50%). Structural pathologies in the uterine cavity such as congenital Mullerian anomalies and intrauterine lesions can affect endometrial receptivity, resulting in implantation failure that manifests as recurrent pregnancy loss or infertility [22].

In this study, as regard findings of transvaginal US in the cases included in the study. Normal findings were detected in 30%, Arcuate Uterus in 10%,

Uterine septum in 17.5%, uterine fibroid in 8.75%, Endometrial polyp in 15%, Cervical polyp in 3.75%, Chronic endometritis in 1.25% where the endometrium appeared bright, hyperechoic, thickened endometrium with mild free fluid. Dehiscence of C.S scar in 5%, Intrauterine adhesion in 2.5% and PCO in 6.5%. The high rate of CS in Egypt may be the results of increase the Dehiscence of C.S scar and we should take in account the proper selection of cases for cesarian section.

Agree this study, the study of Niknejadi et al., [22] as regard sonography, they reported that 23 had polypoid lesions, 30 had sub-septate, three had long uterine septa, 14 had adhesions, seven had endometrial hyperplasia and three had unicornate uteruses.

Against this study Farooq et al., [23] among 138 females, PCOS was seen in 40.6% of the subjects. And the incidence of multiple fibroids was 5.1% as third most common pathology in both primary and secondary infertility cases. Most ovarian pathologies were found to be bilateral. 12.3% subjects had no findings on ultrasound.

Against this study Hussain et al., [24] demonstrated that all the 100 cases undergone TVS study where PCO was found among 69(69%) cases, chronic pelvic inflammatory disease 14(14%) fibroids 6(6%) anatomical problems 19(19%) endometrial/cervical polyp 18(18%) free fluid in pelvic/abdominal cavity 7(7%) endometritis 5(5%) endometriosis 4(4%) adenomyosis 5(5%) chocolate cyst 8(8%) tubo-ovarian mass 2(2%) intrauterine and intra pelvic

adhesions 2(2%) septate uterus 29(29%) pelvic abscess 1(1%).

In the study of Kolade-Yunusa et al., [25] out of 203 patients, 110(54.2%) had normal findings on TVS while the remaining 93(45.8%) of patients had abnormal ultrasound. This was statistically significant $p=0.02$. Uterine fibroid, polycystic ovary were the common pathologies seen on TVS with uterine fibroid the most common.

Furthermore, Mohammed et al., [26] stated that in most cases of female infertility in their study, ultrasound has been of great value: e.g., uterine malformations (sub septate and bicornuate uterus), endometrial abnormalities (endometrial polyp and focal endometrial hyperplasia), myometrial diseases (fibroids and uterine adenomyosis), tubal abnormalities (including hydrosalpinx and endometriosis), ovarian functional abnormalities (polycystic ovary) and cervical abnormalities (cervical masses).

Hysteroscopy is a valuable diagnostic and therapeutic modality in the management of infertility. Hysteroscopy is the gold standard procedure for uterine cavity exploration. It is widely accepted that a complete infertility workup should include an evaluation of the uterine cavity. Uterine abnormalities, congenital or acquired, are implicated as one of the causes of infertility. In fact, infertility related to uterine cavity abnormalities has been estimated to be the causal factor in as many as 10% to 15% of couples seeking treatment. Moreover, abnormal uterine findings have been found in 34% to 62% of infertile women [27].

The World Health Organization (WHO) recommends hysterosalpingography (HSG) alone for management of infertile women. The explanation for this discrepancy is that HSG provides information on tubal patency or blockage. Office hysteroscopy is only recommended by the WHO when clinical or complementary exams (ultrasound, HSG) suggest intrauterine abnormality or after in vitro fertilization (IVF) failure. Nevertheless, many specialists feel that hysteroscopy is a more accurate tool because of the high false-positive and false negative rates of intra uterine abnormality with HSG. This explains why many specialists use hysteroscopy as a first line routine exam for infertility patients regardless of guidelines [28].

The present study showed that as regard findings of hysteroscope in the cases included in the study. Normal findings were detected in 20%, Arcuate Uterus in 10%, Uterine septum in 17.5%, Uterine fibroid in 7.5%, Endometrial polyp in 18.7 5%, Cervical polyp in 5%, Chronic endometritis in 6.25%, Dehiscence of C.S scar in 5%, Intrauterine adhesion in 2.5% and tubal obstruction in 7.5%.

In this study, endometrial polyp was the most common uterine abnormality (in 15 cases, 18.7 5%).

Agree with this study Apirakviriya et al. [29] (18 cases, 26%), Shawki et al. [30] (11 cases, 32.4%), El Huseiny and Soliman, [31] (18 cases, 36.73%) Rama Raju et al. [32] (32 cases, 33.68%), Oliveira et al. [33] (18%), Doldi et al. [34] (65%), El-Mazny et al. [35] (8 cases, 5.5%).

The current study has shown that the second most common reported abnormal uterine finding was uterine septum in (9 cases, 11.25%) which is higher than the prevalence reported by Rama Raju et al. [32] (8.42%), El-Mazny et al. [35] (1case, 0.7%), Apirakviriya et al. [29] (1case, 0.7%), Shawki et al. [30](1case,2.8%), Sahu et al. [19] (10 cases, 3,08%).

Agree with this study Farag et al. [36] the most prevalent abnormality was endometrial polyp(18.4%) followed by uterine septum (6.9%).

Agree with this study Koskas et al. [28] the most prevalent abnormality was endometrial polyp 54 cases (9.7%).

In this study, submucous myoma was found in 6 cases with 7.5% prevalence.

Agree with this study Husseiny and Soliman [31] (7 cases, 7.95%), Shawki et al. (4 cases, 11.4%) [30] and higher than the prevalence of other studies as Fatemi et al. [37] (6 cases, 1%), Sahu et al. [19] (2 cases, 0.62%), Rama Raju et al. [32] (1 case, 1.05%) Bareg et al. [38] (8 cases, 4%), El-Mazny et al. (2011) [35](6 cases, 4.1%), Apirakviriya et al. (2016) (3 cases, 4.3%) [29].

Against this study, Mardanian et al., [39] showed that Hysteroscopy was normal in 29 (59%) of the 49 cases. Endometrial myoma was most common finding (seven cases) among women with abnormal results. The other findings were submucous myoma (four cases) and uterine septum (two cases).

In this study, tubal ostia block seen in 6 cases (7.5%) Agree with this results osteal abnormalities reported by other studies were tubal block in 29 cases (8.95%) in Sahu et al., [19]. But In other studies, the prevalence of tubal bock is 1.4% (El-Mazny et al., 2011) [35].

This study concluded that chronic endometritis were found in 5 reports with a prevalence of 6,25%.

Agree with this study Shawki et al. [30] (2 cases, 5.7%), but higher than El-Mazny et al. (2.1%) [35], Sahu et al. (9 cases, 2.78%) [19], and lower than Oliveira et al. (13%) [33].

In this study intra uterine adhesion seen in 2 cases (2.5%) which less than M Koskas et al. [28] 22 cases (3.9%). Also S Parveen et al. [40] 2 cases (3.2%) diagnosed as intra uterine adhesion.

In contrast to this study Sahu et al., [19] reported that hysteroscopy revealed a normal uterine cavity in 211 (65.12%) women. As regard cervico-Isthmic abnormalities: Cervical stenosis seen in 21/324 (6.48%), Cervical polyp 5/324(1.54%). Uterine cavity abnormalities: Intra uterine synechia 16/324 (4.93%), Septate uterus 10/324(3.08%), Submucus myoma 2/324 (0.62%), Deformed cavity (Intra mural myoma, Mullerian anomalies) 15/324 (3.71%), Endometrial polyp 2/324 (0.62%). Ostial abnormalities: Cornual fibrosis 29/324 (8.95%), Inflammation 18/324 (5.55%). Endometrial abnormalities: Inflammation 9/324 (2.78%), Fibrosis 17/324 (5.25%), Hyperplastic 1/324 (0.31%) Atrophic 3/324 (0.93%).

According to Ahmed et al., [41] all patients were subjected to diagnostic hysteroscopy, 22 of them (18.3%) were finally diagnosed to have polyps(Agree with this study), But against this study patients had cervical stenosis (5%), 1 patient have myomas (8%), 8 patients had intrauterine synechia (7%) and 19 patients had congenital uterine anomalies (16%). Cervicitis was found in 12 cases (10%), while 3 cases had Aendocervical cysts (2.5%), con not accessible in 4 cases (3.3%), while ostia not seen in 8 cases (6.6%), 3cases had tight isthmus (2.5%) and 3cases had polypidal thickness at isthmus (2.5%) while hysteroscopy results were found to have no abnormality in 49 patients (40.8%).

In contrast to this study ,in the study of Farag et al., [36] among the 2725 hysteroscopy reports

that were reviewed, complete reports were 2652 (97.3%), only 803 cases were normal, with a prevalence of 30.3%, while 1849 cases had abnormal hysteroscopic findings, with a prevalence of 69.7%. The reported abnormalities were either vaginal (8 cases representing 0.3%), cervical (581 cases representing 21.9%), uterine (819 cases representing 30.9%), endometrial (1251 cases, representing 47.2%) and tubal ostia abnormalities in 428 cases representing 16%.

In contrast to this study Yadav et al., [16] revealed that conventional hysteroscopy revealed normal endometrium in 83 cases while diffuse endometrial disease was suspected in 17 cases (hyperplastic in 13 cases and polypoidal in 4 cases; intracavitary lesions were detected in 26 cases (submucous öbroids in 14, endometrial polyps in 11, and growth with areas of necrosis in one case), synechiae in 2 cases.

In contrast to this study, Parveen et al., [40] revealed that myomas were seen in 4 (6.45%) cases three at laparoscopy and one on hysteroscopy. Endometrial polyps were revealed in 6 (9.6%) and Asherman syndrome found in 2(3.2%) patients on diagnostic hysteroscopy. Uterine anomalies were revealed in 8 (12.9%) patients including arcuate uterus in 4 (6.45%), septate uterus in 2(3.2%), bicornuate uterus in one and uterine didelphys in one. Five women had endometriosis, 12 (19.35%) had PCOD, and 3 (4.8%) had functional cyst of ovary. Pelvic adhesions were found in 7 (11.2%) patients. As a whole pelvic pathology were confirmed in 52 (83.8%) patients and intrauterine pathology in 17 (27.4%) by this approach.

There was 10% of cases normal with ultrasound but hysteroscopy found pathology in these cases.

Agree with this study Kandeel et al., [42] reported that the abnormal uterine cavity is detected in about 25% of cases evaluated by TVS versus 45% of cases evaluated by hysteroscopy, with hysteroscopic examination. The most common uterine pathology was endometrial polyp which constituted 18.3% of all cases.

5. CONCLUSIONS

Our data are an additional argument to suggest hysteroscopy as part of investigation in infertile woman. Routine diagnostic hysteroscopy and ultrasound should be part of an infertility workup secondary infertility. Obesity is associated with

hormonal derangement which are responsible for infertility weight loss should be considered as a first line treatment. Unsafe practices and abortion with its complications must be taken with consideration as predisposing factor secondary infertility. We are now facing with the increased rate of cesarean section which is universal trend in obstetrics in our country and in the world with it is all complications such as cesarean scar dehiscence and infertility so we should follow the indications for C.S. Chronic endometritis is a hidden cause for secondary infertility must be taken in consideration, excluded, or diagnosed using hysteroscopy. Age of female presented with secondary infertility plays important role in predicting the cause of infertility.

DISCLAIMER

The products used for this research are commonly and predominantly use products in our area of research and country. There is absolutely no conflict of interest between the authors and producers of the products because we do not intend to use these products as an avenue for any litigation but for the advancement of knowledge. Also, the research was not funded by the producing company rather it was funded by personal efforts of the authors.

CONSENT

An Informed written consent was taken from all patients participating in this study.

ETHICAL APPROVAL

As per international standard or university standard written ethical approval has been collected and preserved by the author(s).

COMPETING INTERESTS

Authors have declared that no competing interests exist.

REFERENCES

1. Bloom TL, Mosher W, Alhusen J, Lantos H, Hughes RB. Fertility Desires and Intentions Among U.S. Women by Disability Status: Findings from the 2011-2013 National Survey of Family Growth. *Matern Child Health J.* 2017;21:1606-15.
2. Vlahos NF, Theodoridis TD, Partsinevelos GA. Myomas and adenomyosis: Impact on reproductive outcome. *Biomed Res Int.* 2017;2017:5926470.

3. Singh V, Mishra B, Sinha S, Agrawal S, Thakur P. Role of saline infusion sonohysterography in infertility evaluation. *J Hum Reprod Sci.* 2018;11:236-41.
4. Mishra VV, Goyal PA, Gondhali RP, Aggrawal RS, Choudhary SD, Nanda S. Uterine cavity assessment prior to in vitro fertilization: Comparison of 3D transvaginal ultrasonography accuracy versus office hysteroscopy. *IJOG.* 2016;3:270-3.
5. Kuohung W, Hornstein MD, Barbieri R, Barss V. Evaluation of female infertility. *USA: UpToDate.* 2016;55:22-4.
6. Salazar CA, Isaacson KB. Office operative hysteroscopy: An update. *J Minim Invasive Gynecol.* 2018;25:199-208.
7. Capmas P, Pourcelot AG, Giral E, Fedida D, Fernandez H. Office hysteroscopy: A report of 2402 cases. *J Gynecol Obstet Biol Reprod (Paris).* 2016;45:445-50.
8. Bosteels J, Van Herendael B, Weyers S, D'Hooghe T. The position of diagnostic laparoscopy in current fertility practice. *Hum Reprod Update.* 2007;13:477-85.
9. Naqi S, Shafqat-Ul-Islam S, Raza S, Haroon H. Pattern of pathologies on hysterosalpingography in primary infertility and review of Literature. *PJR.* 2016;18.
10. Kodaman PH. Hysteroscopic polypectomy for women undergoing IVF treatment: when is it necessary? *Curr Opin Obstet Gynecol.* 2016;28:184-90.
11. Cenksoy P, Ficioglu C, Yıldırım G, Yesiladali M. Hysteroscopic findings in women with recurrent IVF failures and the effect of correction of hysteroscopic findings on subsequent pregnancy rates. *Arch Gynecol Obstet.* 2013;287:357-60.
12. Vahidi S, Ardalan A, Mohammad K. Prevalence of primary infertility in the Islamic Republic of Iran in 2004-2005. *Asia Pac J Public Health.* 2009;21:287-93.
13. Roupa Z, Polikandrioti M, Sotiropoulou P, Faros E, Koulouri A, Wozniak G, et al. Causes of Infertility in Women at Reproductive Age. *Health science journal.* 2009;3.
14. Lorusso F, Ceci O, Bettocchi S, Lamanna G, Costantino A, Serrati G, et al. Office hysteroscopy in an in vitro fertilization program. *Gynecol Endocrinol.* 2008;24:465-9.
15. Meng Q, Ren A, Zhang L, Liu J, Li Z, Yang Y, et al. Incidence of infertility and risk factors of impaired fecundity among newly married couples in a Chinese population. *Reprod Biomed Online.* 2015;30:92-100.
16. Sahu L, Tempe A, Gupta S. Hysteroscopic evaluation in infertile patients: A prospective study. *Methods.* 2010; 2012.
17. Sami N, Ali TS, Wasim S, Saleem S. Risk factors for secondary infertility among women in Karachi, Pakistan. *PLoS One.* 2012;7:e35828.
18. Yadav S, Nanda S, Malhotra V. Role of Chromohysteroscopy in Patients of Abnormal Uterine Bleeding. *Indian J Gynecol.* 2021;19:1-6.
19. Lorusso F, Ceci O, Bettocchi S, Lamanna G, Costantino A, Serrati G, et al. Office hysteroscopy in an in vitro fertilization program. *Gynecological Endocrinology.* 2008;24:465-9.
20. Ali TS, Sami N, Khuwaja AK. Are unhygienic practices during the menstrual, partum and postpartum periods risk factors for secondary infertility? *J Health Popul Nutr.* 2007;25:189.
21. Ali TS, Fikree FF, Rahbar MH, Mahmud S. Frequency and determinants of vaginal infection in postpartum period: A cross sectional survey from low socioeconomic settlements, Karachi, Pakistan. *J Pak Med Assoc.* 2006;56:99.
22. Dhont N, Luchters S, Muvunyi C, Vyankandondera J, De Naeyer L, Temmerman M, et al. The risk factor profile of women with secondary infertility: an unmatched case-control study in Kigali, Rwanda. *BMC women's health.* 2011;11:1-7.
23. Farooq SMY, Murrium SKTS, Robot GC, Gilani A, ul Abidin SZ, Ahmed H. Sonographic Co-relation Between Adnexal Masses And Endometrial Thickness In Infertile Females. *AJAHS.* 2021.
24. Hussain NB, Das RR. Transvaginal Ultrasound Findings Among the Women Presenting with Infertility. *Chattagram Maa-O-Shishu Hosp Med College J.* 2017; 16:31-4.
25. Kolade-Yunusa H, Abdullahi H, Salaam A. Evaluation of infertile women using transvaginal ultrasound in a tertiary health facility. *Jos Journal of Medicine.* 2019;13:12-20.
26. Mohammed A, Maysa SE, Keriakos N. Ultrasound role in management of female infertility. *Med J Cairo Univ.* 2020; 88:1523-30.
27. Brown SE, Coddington CC, Schnorr J, Toner JP, Gibbons W, Oehninger S. Evaluation of outpatient hysteroscopy, saline infusion hysterosonography, and

- hysterosalpingography in infertile women: A prospective, randomized study. *Fertility and sterility*. 2000;74:1029-34.
28. Apirakviriya C, Rungruxsivorn T, Phupong V, Wisawasukmongchol W. Diagnostic accuracy of 3D-transvaginal ultrasound in detecting uterine cavity abnormalities in infertile patients as compared with hysteroscopy. *Eur J Obstet Gynecol Reprod Biol*. 2016;200:24-8.
 29. Emmanuel MO, Olamijulo JA, Ekanem EE. Risk factors associated with secondary infertility in women of childbearing age: A matched case–control study. *Trop J Obstet Gynaecol*. 2018;35:249-55.
 30. Shawki HE, Elmorsy M, Eissa MK. Routine office hysteroscopy prior to ICSI and its impact on assisted reproduction program outcome: a randomized controlled trial. *Middle East Fertil Soc J*. 2012;17:14-21.
 31. El Huseiny AM, Soliman BS. Hysteroscopic findings in infertile women: a retrospective study. *Middle East Fertil Soc J*. 2013;18:154-8.
 32. Raju GR, Kumari GS, Krishna K, Prakash G, Madan K. Assessment of uterine cavity by hysteroscopy in assisted reproduction programme and its influence on pregnancy outcome. *Archives of gynecology and obstetrics*. 2006;274:160-4.
 33. Oliveira FG, Abdelmassih VG, Diamond MP, Dozortsev D, Nagy ZP, Abdelmassih R. Uterine cavity findings and hysteroscopic interventions in patients undergoing in vitro fertilization–embryo transfer who repeatedly cannot conceive. *Fertility and sterility*. 2003;80:1371-5.
 34. Doldi N, Persico P, Di Sebastiano F, Marsiglio E, De Santis L, Rabellotti E, et al. Pathologic findings in hysteroscopy before in vitro fertilization-embryo transfer (IVF-ET). *Gynecological endocrinology*. 2005; 21:235-7.
 35. El-Mazny A, Abou-Salem N, El-Sherbiny W, Saber W. Outpatient hysteroscopy: a routine investigation before assisted reproductive techniques? *Fertility and Sterility*. 2011;95:272-6.
 36. Farag AH, Salama MH, Badrous ES. Assessment of the prevalence of abnormal hysteroscopic findings in infertile women undergoing ART. *The Egyptian Journal of Hospital Medicine*. 2019;75:2433-40.
 37. Haimovich S, Raz N. *Hysteroscopy in Chronic Endometritis. Hysteroscopy Simplified by Masters*: Springer. 2021;147-54.
 38. Mardanian F, Rouholamin S, Nazemi M. Evaluation of Efficacy of transvaginal sonography with hysteroscopy for assessment of tubal patency in infertile women regarding diagnostic laparoscopy. *Advanced Biomedical Research*. 2018; 7.
 39. Parveen S, Khanam M. Role of combined diagnostic laparoscopy and simultaneous diagnostic hysteroscopy for evaluation of female subfertility factors. *J Surg Pak (International)*. 2010;15:44-7.
 40. Ahmed F, Khalifa E, Ahmed A, Rashad E. Hysteroscopic detection of intrauterine pathology in women with unexplained infertility. *Med J Cairo Univ*. 2018;86:1287-94.
 41. Kandeel MA, Sayyed TM, Tharwat AM, Hamed AS. Hysteroscopy versus transvaginal ultrasound in infertile women prior to intracytoplasmic sperm injection. *Menoufia Med J*. 2020;33:400.
 42. Lasmar RB, Barrozo PRM, Dias R, de Oliveira MAP. Submucous myomas: a new presurgical classification to evaluate the viability of hysteroscopic surgical treatment—preliminary report. *J Minim Invasive Gynecol*. 2005;12:308-11.

© 2022 Kabeil et al.; This is an Open Access article distributed under the terms of the Creative Commons Attribution License (<http://creativecommons.org/licenses/by/4.0>), which permits unrestricted use, distribution, and reproduction in any medium, provided the original work is properly cited.

Peer-review history:

The peer review history for this paper can be accessed here:

<https://www.sdiarticle5.com/review-history/84715>