



Alopecia and Dermatitis Caused by *Lepoarcarus gibbus* in a New Zealand White Rabbit (*Oryctolagus cuniculus*) – Clinical and Parasitological Diagnosis and Treatment

**M. Sandhya Bhavani^{a*}, G. R. Baranidharan^a, B. Rubinibala^b
and L. Nagarajan^a**

^a Department of Clinics, Madras Veterinary College, Tamil Nadu Veterinary and Animal Sciences University, Chennai-600 007, Tamil Nadu, India.

^b Department of Veterinary Parasitology, Madras Veterinary College, Tamil Nadu Veterinary and Animal Sciences University, Chennai- 600 007, Tamil Nadu, India.

Authors' contributions

This work was carried out in collaboration among all authors. Author MSB Conceptualization and writing original draft. Authors GRB and LN Review and editing the study, Author BR Parasitological studies. All authors read and approved the final manuscript.

Article Information

DOI: 10.9734/JSRR/2021/v27i1230472

Open Peer Review History:

This journal follows the Advanced Open Peer Review policy. Identity of the Reviewers, Editor(s) and additional Reviewers, peer review comments, different versions of the manuscript, comments of the editors, etc are available here: <https://www.sdiarticle5.com/review-history/80037>

Case Report

**Received 08 October 2021
Accepted 17 December 2021
Published 18 December 2021**

ABSTRACT

Aim: Ectoparasites associated dermatological disorders are frequently encountered in laboratory and pet rabbit medicine practice, however, *L. gibbus* is the only ectoparasite rarely reported in either pet and laboratory rabbits or hares as *L. gibbus* are usually asymptomatic. The aim of the present report is to describe a case of alopecia and dermatitis associated with *Lepoarcarus gibbus* in a rabbit from India. Presentation of Case: A 1.5 year old female New Zealand White rabbit was presented to the Dermatology Unit with erythema and poorly demarcated alopecia on the dorsal neck and face. A skin scraping and coat brushings were performed. On microscopic evaluation of hair samples, *L. gibbus* infestation was confirmed. Treatment with ivermectin (0.3 mg/kg) biweekly once for 3 doses proved effective.

[≡] Assistant Professor;

[°] Professor and Head;

*Corresponding author: E-mail: sanjuri02@gmail.com;

Discussion and Conclusion: *L.gibbus* may be presented with severe hairfall in the absence of other mites and treatment with ivermectin is effective.

Based on the literature research this may be the first case report on alopecia and dermatitis due to *L.gibbus* in rabbit from India. Further studies should be planned on the prevalence of the mite as it is reported to have zoonotic potential.

Keywords: *L. gibbus*; pet rabbit; alopecia; dermatitis; coat brushings; ivermectin therapy.

1. INTRODUCTION

The rabbit (*Oryctolagus cuniculus*) is a common companion animal belonging to the family Leporidae of the order Lagomorpha. Its skin disorders are well studied and documented. The diseases of the rabbit's skin can be classified as infectious, parasitic, behavioural, traumatic and neoplastic [1]. Ectoparasites associated dermatological disorders are frequently encountered in laboratory and pet rabbit medicine practice. *Ctenocephalides felis*, *Cuterebra* spp., *Haemaphysalis leporispalustris*, *Haemodipsus ventricosus*, *Sarcoptes* spp., *Psoroptes cuniculi*, *Cheyletiella parasitivorax* and *L. gibbus* were recorded as the main ectoparasites affecting rabbits globally. Among these, *L. gibbus* is the only ectoparasite rarely reported in either pet and laboratory rabbits or hares. Case reports and epidemiological studies of the mite in many countries remain inadequate. Infestations in rabbits had been recorded in the USA, Brazil, Costa Rica, South Korea, Australia, Israel and in few European countries [2]. In India, several reports describe *Sarcoptes scabiei*, *Psoroptes*

cuniculi and *Notoderes cati* causing severe dermatological lesions [3,4,5,6] but report on occurrence and affections of *L. gibbus* is lacking. This may be due to the fact that *L. gibbus* is usually asymptomatic, therefore the infestation go under diagnosed [7]. The purpose of the present report is to describe a case of alopecia and dermatitis associated with *Lepoarcarus gibbis* in a rabbit from India.

2. PRESENTATION OF CASE

A 1.5 year old, female New Zealand white rabbit was presented to the Dermatology Unit with the history of alopecia on the face and dorsal neck for the past two weeks. The rabbit was housed in an indoor cage and fed with commercial food. The rabbit had no previous history of illness or itching. On physical examination, the rabbit appeared active and alert and was in good body condition. On dermatological examination, the rabbits had erythema and poorly demarcated alopecia on the dorsal neck and face region (Fig. 1). No other abnormalities of skin and hair coat were detected.

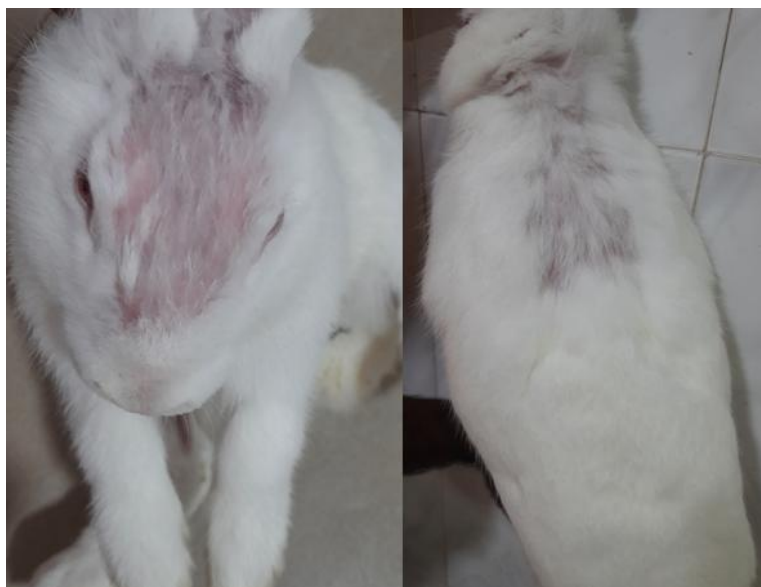

Fig. 1. Erythema and poorly demarcated alopecia on the dorsal neck and face

Skin scraping, coat brushings, Skin cytology and fungal culture were done. Blood sample was collected from ear vein. Sterile scalpel blade was used to do deep skin scraping from the hairless area on the face and neck. Coat brushing were done with a toothbrush and samples were collected from the neck, lumbar region and tail region. The slides were examined with x10 and x40 magnification under a light microscope.

Microscopic examination of the collected material by deep skin scraping was negative while coat brushings revealed adult *L. gibbus* males and females, and eggs of the parasite (Fig. 2). No other mite species were visualized. Skin cytology and fungal culture were both negative for bacteria and fungi. Haematology and serum biochemistry values were within normal limits (Table 1).



**Fig. 2. a. Male *L.gibbus* mite with two elongated adanal processes (40x)
 b. Female *L.gibbus* mite with highly sclerotised gnathosoma (40x)
 c. Egg of *L.gibbus* (10x)**

Table 1. Values of Haematology and Biochemistry parameters in the affected rabbit

Parameters	Haematology and Biochemistry parameters	Normal range (Melillo, 2007[8] and Marshall, 2008[9])
Haemoglobin (g/dl)	14.31	10-15.5
PCV (per cent)	37.7	36-48
Total erythrocyte ($\times 10^6$ /cumm)	5.4	4-7.2
Total leukocyte ($\times 10^3$ /cumm)	7.7	7.5- 13.5
Neutrophils ($\times 10^3$ /cumm)	4.4	1-9.4
Lymphocytes ($\times 10^3$ /cumm)	2.7	1.6-10.6
Monocytes ($\times 10^3$ /cumm)	0.2	0.05-0.8
Eosinophils ($\times 10^3$ /cumm)	0.3	0.05-0.5
Platelets ($\times 10^3$)	630	250-650
Serum Alkaline Phosphatase (IU/L)	95	12-96
Alanine aminotransferase (IU/L)	56	45-80
Total protein (g/dl)	6.3	5.4-7.5
Albumin (g/dl)	2.9	2.7-5.0
Calcium (mg/dl)	13.19	11-14
Phosphorus (mg/dl)	5.78	4.0-6.5
Glucose (mg/dl)	96	75-155
Cholesterol (mg/dl)	37	10-80

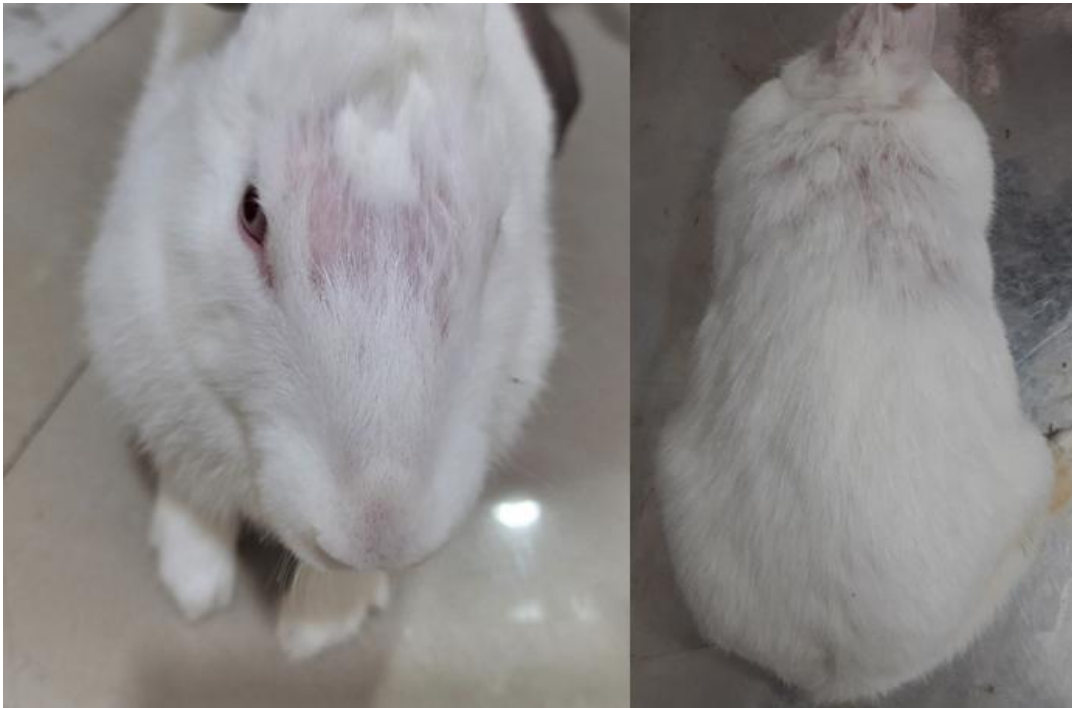


Fig.3. Regrowth of hair after Ivermectin therapy

300 micrograms per kg body weight of ivermectin (Neomec[®], 1%, Intas Pharmaceuticals) was administered subcutaneously. The treatment was prescribed for three injections every 14 days, over a period of 6 weeks. The rabbit's cage and litter box was advised to be washed with hot water and its litter to be changed every day. Four weeks after treatment microscopic examination of coat brushings did not reveal any parasites. Regrowth of hair on the affected was observed after 8 weeks (Fig. 3).

3. DISCUSSION

Leporacarus gibbus (formerly *Listrophorus gibbus*) is a highly specific, parasitic surface mite of laboratory and pet rabbits and hares. It belongs to the order Astigmata, division Psoroptida, family Listrophoridae [10]. The mites attach to the hair of the host where all the stages of life cycle occur and feed on sebaceous secretions, hair debris and epithelial scales [11]. Although the mite is considered cosmopolitan, there are only a few reports on the occurrence of the mite. The mites are located on the distal third of the hair shaft, visualization is difficult. Infestation causes no clinical signs or subclinical dermatitis. Therefore, knowledge of the diagnostic methods and optimal sampling sites in subclinical infections is essential [10]. In general, there is no sex, breed and sex predilection,

however, one study reported that long-haired rabbits may be more susceptible to infestation than short-haired animals [12].

L. gibbus infestation is documented to be associated with clinical signs such as poorly demarcated alopecia, moist dermatitis, pruritis, erythema and scaling on the dorsum and hindlimbs [13,14]. Studies suggest that hypersensitivity reaction due to presence of mite may occur leading to self-trauma, pruritus, alopecia, seborrhea and scaling. However, infestation with no clinical signs has also been reported [15]. Mites were found mainly on the dorsal back and lateral sides. In case of severe infestation, distribution in the abdominal region, face, neck and base of the tail are described as well [1]. Diagnostic tests include Tape impression, trichogram and coat brushings.

The occurrence of *L. gibbus* is usually associated with the presence of the *C. parasitovorax* mite [16]. Therefore, the morphological characteristic of the *L. gibbus* under light microscope is crucial for the identification and differentiate from other mites. These obligate parasites of lagomorphs have laterally compressed body with prescapular shield with a straight anterior margin, which extends over the gnathosoma. The legs are short without clasping adaptations. Anterior coxal fields which are the characteristic feature of this mites

that are expanded and flattened with grooved surfaces which arise from each of the first pair of coxae and they serve as organ of attachment, along with the anterior legs.

As in other Astigmata, sexual dimorphism is present. Females are larger, oval and its cuticle is finely striated giving thumb print pattern appearance. Female gnathosoma is highly sclerotised, giving dark hooded appearance to the anterior part of the mite. Male mites are comparatively smaller than females and have two elongated adanal processes and distinct anal suckers (Fig 2) proposed for the disease. Single subcutaneous dose of ivermectin (300 mg/kg) [14,16], topical treatment combined with moxidectin 1.0% and imidacloprid 10.0% associated with the application of a miticide-based disinfectant to the animal's housing [7], selamectin, imidacloprid ± permethrin combination [10] and doramectin [17] are proved to be effective against *L. gibbus* by various studies worldwide.

The *L.gibbus* mite is considered to be zoonotic and few reports of Papular urticaria in humans related to these mites were recorded [7,18]. Recently a case of dermatitis in cat due *L.gibbus* mite has also recorded [19]. It is therefore essential to combine drug therapy along with ample disinfection of cages and separation of rabbits to prevent infestations to rabbits, humans and other animal species.

4. CONCLUSION

In conclusion,our work reports, the occurrence of *L.gibbus* in India. The therapeutic protocol administered with ivermectin at a dose of 0.3 mg/kg every 14 days for six weeks proved effective. Based on the literature research on Scopus and similar search tools this may be the first case report on alopecia and dermatitis due to *L.gibbus* in rabbit from India. Further studies should be planned on the prevalence of the mite as it is reported to have zoonotic potential.

DISCLAIMER

The products used for this research are commonly and predominantly use products in our area of research and country. There is absolutely no conflict of interest between the authors and producers of the products because we do not intend to use these products as an avenue for any litigation but for the advancement of knowledge. Also, the research was not funded by

the producing company rather it was funded by personal efforts of the authors.

ACKNOWLEDGEMENTS

The authors thank Tamil Nadu Veterinary and Animal Sciences University for the facilities provided.

COMPETING INTERESTS

Authors have declared that no competing interests exist.

REFERENCES

1. Jenkins JR. Skin Disorders of the Rabbit. Vet Clin North Am Exot Anim Pract, 2001; 4: 543-563. Available:https://doi.org/10.1016/S1094-9194(17)30042-7
2. Zygnier W Gójska-Zygnier O. The first case of *Leporacarus gibbus* infestation in a rabbit from Poland. Acta Parasitol. 2018; 63: 210- 213. DOI: 10.1515/ap-2018-0024
3. Soundarajan C, Iyue M. Incidence of mange infestation in rabbits. J Vet Parasit. 2005;19:161-162.
4. Kumar A, Shekhar P. Therapeutic management of notoedric mange in rabbits. J Vet Parasitol, 2010; 24(1):103–104.
5. Panigrahi PN, Mohanty BN, Gupta AR. Concurrent infestation of Notoedres, Sarcoptic and Psoroptic acariosis in rabbit and its management. J Parasit Dis. 2016; 40:1091–1093. DOI: 10.1007/s12639-014-0631-3 .
6. Prakash MA, Soundararajan C, Kumaresan N. Sarcoptic mange infestation in rabbits in an organized farm at Tamil Nadu. J Parasit Dis. 2016;41(2):429-432. DOI: 10.1007/s12639-016-0821-2
7. D'Ovidio D, Santoro D. *Leporacarus gibbus* infestation in client-owned rabbits and their owner. Vet Dermatol. 2014; 25:46-e17. DOI: 10.1111/vde.12089.
8. Melillo A. Rabbit Clinical Pathology, J Exot Pet Med. 2007;16 (3):135-145
9. Marshall KL. Rabbit hematology Vet. Clin. North. Am. Exot. Anim. Pract. 2008,11(3):551-67.
10. Birke LL, Molina PE, Baker DG. Comparison of Selamectin and Imidacloprid plus Permethrin in Eliminating

- Leporacarus gibbus* Infestation in Laboratory Rabbits (*Oryctolagus cuniculus*). J Am Assoc Lab Anim Sci. 2009; 48(6):757–62.
Available: <https://www.ncbi.nlm.nih.gov/pubmed/19930824>.
11. Pritt S, Cohen K, Sedlacek H. Parasitic Diseases. In: M. Suckow, K. Stevens, R. Wilson (Eds). The Laboratory Rabbit, Guinea Pig, Hamster and Other Rodents. Elsevier, London; 2012. p.415-443.
 12. Kirwan AP, Middleton B, Mcgarry JW. Diagnosis and prevalence of *Leporacarus gibbus* in the fur of domestic rabbits in the UK. Vet Rec. 1998;142:20-21.
Available: <http://dx.doi.org/10.1136/vr.142.1.20>.
 13. Patel A, Robinson KE. Case Report: Dermatitis associated with *Listrophorus gibbus* in the rabbit. J Small Anim Pract. 1993; 34: 409-411.
Available: <https://doi.org/10.1111/j.1748-5827.1993.tb02737.x>
 14. Serra-Freire NM, Benigno RM, Falcão K. Casos clínicos de dermatite por *Leporacarus gibbus* (Acari:Listrophoridae) em criações zootécnicas de coelhos domésticos (*Oryctolagus cuniculus*) nos estados do Pará e São Paulo. Revista Brasileira de Medicina Veterinária. 2010; 32:111-114.
Available: <http://rbmv.org/index.php/BJVM/article/view/837>.
 15. Deak G, Turcu C. A case of infestation with *Leporacarus gibbus* in a pet rabbit. Sci Parasitol. 2020;21(3):138-141.
 16. Silva AS, Tochetto C, Mahl DL. Infestação por *Leporacarus gibbus* em coelhos domésticos no Brasil. Estudos de Biologia. 2006;28(65): 127-129.
Available: <http://dx.doi.org/10.7213/reb.v28i65.22747>
 17. Santos RR, Coelho CN, Nunes TP. Efficacy of oral Doramectin as treatment for *Psoroptes ovis* and *Leporacarus gibbus* in naturally infested rabbits. Pesquisa Veterinária Brasileira. 2017;37: 47 -51.
Available: <http://dx.doi.org/10.1590/s0100-736x2017000100008>
 18. Burns DA. Papular urticaria produced by the mite *Listrophorus gibbus*. Clin Exp Dermatol. 1987; 12:200–1.
Available: <https://doi.org/10.1111/j.1365-2230.1987.tb01895.x>
 19. Dumitrache MO, Györke A, D’Amico G. First case report of dermatitis associated with *Leporacarus gibbus* in cat. BMC Vet Res. 2021; 17: 4.
Available: <https://doi.org/10.1186/s12917-020-02681-0>

© 2021 Bhavani et al.; This is an Open Access article distributed under the terms of the Creative Commons Attribution License (<http://creativecommons.org/licenses/by/4.0>), which permits unrestricted use, distribution, and reproduction in any medium, provided the original work is properly cited.

Peer-review history:

The peer review history for this paper can be accessed here:
<https://www.sdiarticle5.com/review-history/80037>