



Chronic and Stubborn Leucomelanoderma in a Child: A Case Study

C. Ait Khabba ^{a*}, M. Asermouh ^a, K. Znati ^b,
K. Senouci ^a and L. Benzekri ^a

^a Department of Dermatology and Venereology, Ibn Sina Hospital, Mohammed V University, Rabat, Morocco.

^b Department of Anatomic-Pathology, Ibn Sina Hospital, Mohammed V University, Rabat, Morocco.

Authors' contributions

This work was carried out in collaboration among all authors. All authors read and approved the final manuscript.

Article Information

DOI: 10.9734/AJPR/2023/v11i4226

Open Peer Review History:

This journal follows the Advanced Open Peer Review policy. Identity of the Reviewers, Editor(s) and additional Reviewers, peer review comments, different versions of the manuscript, comments of the editors, etc are available here: <https://www.sdiarticle5.com/review-history/97115>

Case Report

Received: 01/01/2023

Accepted: 02/03/2023

Published: 06/03/2023

ABSTRACT

Aims: Pityriasis lichenoides chronic is a rare inflammatory dermatosis, unusually hypochromic in dark phototypes. The evolution of the disease is usually benign, but a malignant transformation in mycosis fungoides is reported. You have to know how to think about it when faced with a generalized hypochromic macular eruption in children.

Case Report: We report a case of a 13-years-old child, photo type 4. He presented for 8 months hypochromic macular lesions, located initially at the face. The evolution was marked by the extension at the trunk and the limbs. He was treated for pityriasis versicolor but without improvement. A skin biopsy was then performed, in favor of Pityriasis Lichenoides Chronica (PLC) with a lymphoid infiltrate made up mainly of CD4 T lymphocytes. The child was put on cyclin associated with heliotherapy with a moderate improvement after 3 months of treatment. The patient was followed for 2 years during which he did not present any malignant transformation.

Discussion: Pityriasis Lichenoides is less frequent in the pediatric population. Its etiopathogenesis is still incompletely elucidated. The basic lesion is an erythematous-squamous papule in the trunk.

*Corresponding author: Email: cha.aitkhabba@gmail.com;

Hypochromic macules can also be observed, either at the cicatricial stage of the disease, or they occur immediately, especially in subjects with dark skin. The histology of PLC reveals perivascular lymphocytic infiltrate in the superficial dermis. The adopted therapeutic is based on heliotherapy or an antibiotic from the macrolide or cyclin family. Evolution towards Mycosis Fungoides has been rarely described.

Conclusion: PLC is exceptionally hypopigmented from the outset. We report a case of chronic leucomelanodermic pityriasis lichenoides in a child posing a problem of differential diagnosis.

Keywords: Hypopigmented; pityriasis lichenoides; chronic; child; histology.

1. INTRODUCTION

Pityriasis Lichenoides constitutes a spectrum of rare inflammatory dermatoses, its etiopathogenesis is not completely elucidated.

There are 2 clinical forms: acute varioliform lichenoid pityriasis characterized by a papular rash progressing to necrosis, and chronic lichenoid pityriasis characterized by an erythematous papulosquamous rash, which is exceptionally hypopigmented from the outset. We report a case of chronic leucomelanodermic pityriasis lichenoides in a child posing a problem of differential diagnosis with other hypochromic dermatoses.

2. PRESENTATION OF THE CASE

We report a case of a 13-years-old child, phototype 4, with no notable pathological history and not vaccinated against SARS COV 2. He presented for 8 months hypochromic macular lesions, very finely scaly, and non-pruritic, located initially at the face (Fig. 1) for which he was initially treated as atopic dermatitis by dermocorticoids. The evolution was marked by the extension at the trunk and the limbs (Fig. 2) with evolution by relapses interspersed with remission. The dermoscopy showed hypopigmented areas poorly limited without any particular pattern (Fig. 3). There is also no palmoplantar, phanerial or mucosal involvement. He was treated for pityriasis versicolor without improvement. Faced with the persistence of the lesions, a skin biopsy was then performed.

Skin biopsy was in favor of Pityriasis Lichenoides Chronica (PLC) with a lymphoid infiltrate (Fig. 4) made up mainly of CD4 T lymphocytes and CD30 were negative. A complete blood count, liver function studies, and LDH were unremarkable and there were no stigmata of infection. The child was put on cyclin associated with heliotherapy with regular monitoring given the risk of progression to mycosis fungoides. Mild

repigmentation of some lesions was noted after 3 months of therapy. The patient was followed for 2 years during which he did not present any malignant transformation.

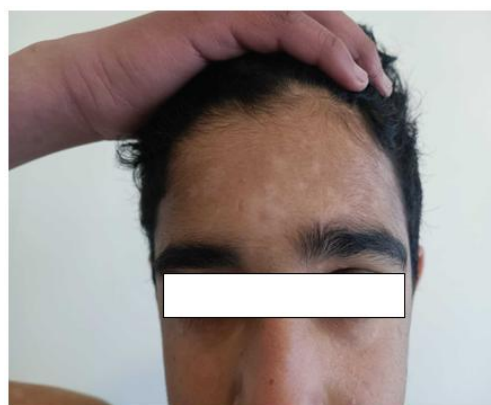

Fig. 1. Hypochromic macular lesions, very finely scaly, and non-pruritic, located essentially at the face

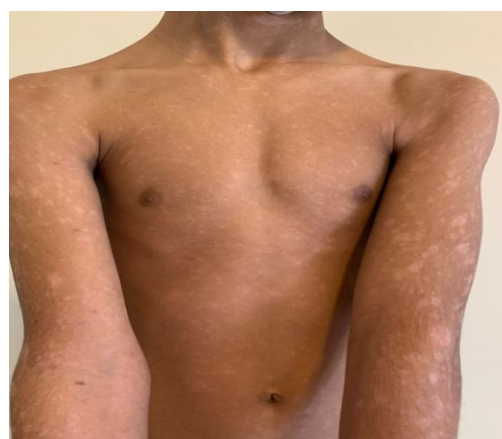

Fig. 2. Extension of the macular lesions at the trunk and the limbs

3. DISCUSSION

Pityriasis Lichenoides occurs in the 2nd and 3rd decades of life. It is less frequent in the pediatric population, with a peak around the age of 5 to 10

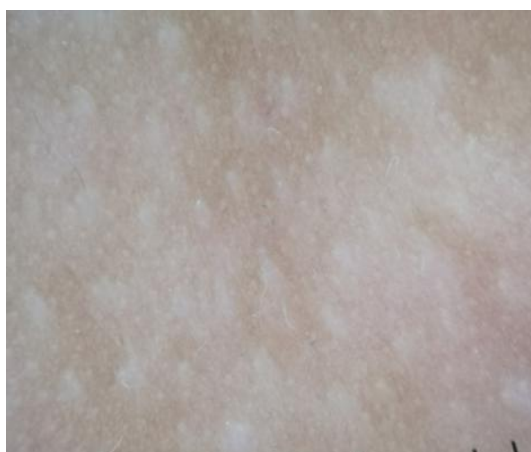

Fig. 3. Dermoscopy showed hypopigmented areas poorly limited without any particular pattern

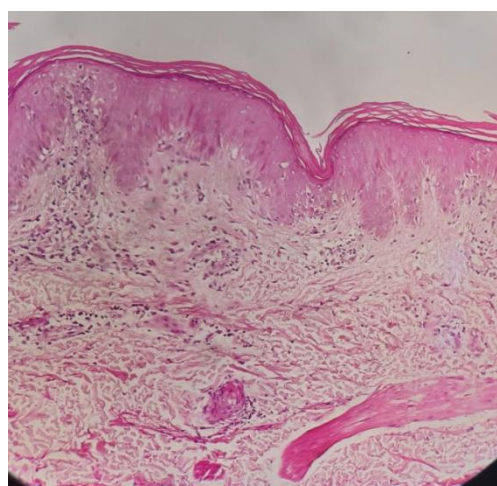


Fig. 4. Lymphoid infiltrate made up mainly of CD 4 and CD 30 negative t lymphocytes

years [1], and a male predominance. Its etiology is not yet fully understood, but several theories have been proposed, in particular the role of infectious agents such as *Toxoplasma Gondii*, HIV, EBV and SARS COV 2, [2] as well as the involvement of drugs such as antibiotics or paracetamol; or even vaccines [3]. Classically in PLC, the basic lesion is an erythematous-squamous papule. It usually appears on the trunk and the proximal part of the limbs. The face, scalp and mucous membranes are exceptionally affected [4]. Hypochromic macules can be observed, either at the cicatricial stage of the disease, following the erythematous rash and in this case, it is a post-inflammatory hypopigmentation (seen frequently). They also can occur immediately, especially in subjects with dark skin, as in the case of our patient [5].

Dermoscopy of the leucomelanodermic form has not been described in the literature and in the case of our patient was not of diagnostic help. According to the study conducted by Elbendary et al. in 2022, the average duration of depigmentation in the absence of primary lesions is 35 to 20 months for patients with PLC [6]; this duration is longer in patients with a dark phototype [7] confirming the data of the study carried out on PLC in black patients in 2010. This suggests that long-lasting pigmentary change in the absence of apparent primary lesions may represent ongoing disease activity rather than a scarring reaction [8]. In the leuco-melanodermic forms of PLC, the initial clinical diagnosis is very often directed towards more frequent dermatoses [9], such as: atopic dermatitis, achromic pityriasis versicolor with yellow-greenish fluorescence in Wood's light, generalized vitiligo but in this case the lesions are symmetrical, never scaly, associated with poliosis and Koebner. In the presence of an atypical evolution it is absolutely necessary to evoke *Mycosis Fungoides*, which manifests during childhood frequently in its hypopigmented variant [10]. Clinically there is asymptomatic or slightly pruritic infiltrated hypochromic lesions on the trunk and extremities [11]. The histology of PLC reveals: compact parakeratosis with focal spongiosis, slight mononuclear intraepidermal exocytosis without lymphocytic atypia, and perivascular lymphocytic infiltrate in the superficial dermis. Lymphocyte immunophenotyping found a predominance of CD4+ and CD30 negative T lymphocytes, distinguishing it from lymphomatoid papulosis [11]. There is no consensual treatment for PLC, but the most adopted therapeutic strategy in children is based on heliotherapy or an antibiotic from the macrolide or cyclin family, even in the absence of foci of infection. We can possibly treat locally with topical corticosteroids or Tacrolimus when the lesions are small [12]. And in second intention will be prescribed phototherapy based on UVB [13]. PLC is a most often benign dermatitis, which can regress spontaneously. Evolution towards *Mycosis Fungoides* has been rarely described [14]. It can also be paraneoplastic and accompany kidney or lung cancer, Hodgkin's disease or non-Hodgkin's lymphoma, hence the need for regular follow-up [5].

4. CONCLUSION

In summary, PLC is a rare inflammatory dermatosis, of unknown etiopathogenesis; manifested by an erythematous and scaly

maculopapular rash that may be unusually hypochromic in dark phototypes. The evolution of the disease is chronic, and usually benign, but a malignant transformation in particular in Mycosis Fungoides in the child is reported. You have to know how to think about it when faced with a generalized hypochromic macular eruption in children.

CONSENT

All authors declare that 'written informed consent was obtained from the patient (for publication of this case report and accompanying images.

ETHICAL APPROVAL

All authors hereby declare that all experiments have been examined and approved by the appropriate ethics committee and have therefore been performed in accordance with the ethical standards laid down in the 1964 Declaration of Helsinki

COMPETING INTERESTS

Authors have declared that no competing interests exist.

REFERENCES

1. Sibel Ersoy-Evans, M Fernanda Greco, Anthony J Mancini, Nuket Subaşı, Amy S Paller Pityriasis lichenoides in childhood: A retrospective review of 124 patients J Am Acad Dermatol. 2007;56(2):205-10. Available: <http://dx.doi.org/10.1016/j.jaad.2006.08.023>. Epub 2006 Oct 13.
2. Zegpi MS, Ruiz F, Porrás N. Pityriasis liquenoide: presentación de un caso clínico y revisión de la literatura. Revista Chilena de Pediatría. 2015;86(2):121–125. Available: <http://dx.doi.org/10.1016/j.rchipe.2015.04.024> 0370-4106
3. Aileen M Feschuk, Maxwell Green, Nadia Kashetsky, Howard I Maibach. Pityriasis Lichenoides Following SARS-CoV-2 Infection/Vaccination. Curr Dermatol Rep. 2023;12(1):27-32. DOI: 10.1007/s13671-023-00380-1 Epub 2023 Jan 17
4. Bellinato F, Maurelli M, Gisondi P, Girolomoni G. A systematic review of treatments for pityriasis lichenoides. Journal of the European Academy of Dermatology and Venereology; 2019. Available: <https://doi.org/10.1111/jdv.15813>
5. Moy A, Sun J, Ma S, Seminario-Vidal L. Lymphomatoid Papulosis and Other Lymphoma-Like Diseases. Dermatologic Clinics; 2019. Available: <https://doi.org/10.1016/j.det.2019.05.005>
6. Amira Elbendary, Mona R E Abdel-Halim, Randa Youssef , et al. Hypopigmented lesions in pityriasis lichenoides chronica patients: Are they only post-inflammatory hypopigmentation?. Australas J Dermatol. 2022;63(1):68-73. Available: <https://doi.org/10.1111/ajd.13746>
7. Tanda N Lane, Sareeta S Parker. Pityriasis lichenoides chronica in black patients Cutis. 2010;85(3):125-9. PMID: 20408509
8. Clayton R, Warin A. Pityriasis lichenoides chronica presenting as hypopigmentation Br J Dermatol. 1979;100(3):297-302. DOI: 10.1111/j.1365-2133.1979.tb06202.x.
9. Zang JB, Coates SJ, Huang J, Vonderheid EC, Cohen BA. Pityriasis lichenoides: Long-term follow-up study. Pediatric Dermatology. 2018;35(2):213–219. Available: <https://doi.org/10.1111/pde.13396>
10. Cynthia M. Magro, Joshua W. Hagen, Arthur N. Crowson, et al .Hypopigmented interface T-cell dyscrasia: A form of cutaneous T-cell dyscrasia distinct from hypopigmented mycosis fungoides. The journal of dermatology; 2014. Available: <https://doi.org/10.1111/1346-8138.12458>
11. Geller L, Antonov NK, Lauren MC, et al. Pityriasis Lichenoides in Childhood: Review of Clinical Presentation and Treatment Options. Pediatric Dermatology. 2015;32(5):579–592. Available: <https://doi.org/10.1111/pde.12581>
12. Maranda EL, Smith M, Nguyen AH, et al. Phototherapy for Pityriasis Lichenoides in the Pediatric Population: A Review of the Published Literature. American Journal of Clinical Dermatology. 2016;17(6):583–591. Available: <https://doi.org/10.1007/s40257-016-0216-2>
13. Eric Laurent Maranda, Megan Smith, Austin H. Nguyen, Vivek N. Patel, Lawrence A Schachner, Jimenez J Joaquin. Phototherapy for Pityriasis Lichenoides in the Pediatric Population: A Review of the Published Literature Am J Clin Dermatol. 2016;17(6):583-591. Available: <https://doi.org/10.1007/s40257-016-0216-2>.

14. Erin Lowe, Jeffrey R Jacobsen, Steve Taylor, Richard Miller, Harper N Price, Israel D Andrews. Mycosis Fungoides Preceding Pityriasis Lichenoides et Varioliformis Acuta by Twelve Years in a Pediatric Patient Am J Dermatopathol 2021;43(12):e259-e262.
Available:<https://doi.org/10.1097/DAD.0000000001949>.

© 2023 Khabba et al.; This is an Open Access article distributed under the terms of the Creative Commons Attribution License (<http://creativecommons.org/licenses/by/4.0>), which permits unrestricted use, distribution, and reproduction in any medium, provided the original work is properly cited.

Peer-review history:

*The peer review history for this paper can be accessed here:
<https://www.sdiarticle5.com/review-history/97115>*