



# Beware the Empty Sac. Case of Cryptorchid Testicular Torsion in the Inguinal Canal

Adam Bin Amir <sup>a\*</sup>

<sup>a</sup> Department of Surgery, Hospital Sultan Ismail, Johor Bahru, Malaysia.

## Author's contribution

The sole author designed, analysed, interpreted and prepared the manuscript.

## Article Information

### Open Peer Review History:

This journal follows the Advanced Open Peer Review policy. Identity of the Reviewers, Editor(s) and additional Reviewers, peer review comments, different versions of the manuscript, comments of the editors, etc are available here: <https://www.sdiarticle5.com/review-history/85332>

Received 26 January 2022  
Accepted 06 April 2022  
Published 09 April 2022

## Case Study

## ABSTRACT

Undescended testis is a common urogenital disorder whereas testicular torsion is a well-recognized urological emergency. However, torsion of an undescended testis remains a rare clinical entity. We present a case of torsion of an undescended testis located in the inguinal canal in an otherwise healthy 13-year-old boy who presented with a painful mass in the groin. He underwent pre-operative imaging studies and subsequently surgical exploration which revealed a twisted gangrenous testis. Due to the rarity of the condition, the case presented us with diagnostic challenges. This case highlights the importance of early diagnosis to improve salvage rate of the testis.

*Keywords: Undescended testis; testicular torsion; urological emergency; misdiagnosis; delayed diagnosis.*

## 1. INTRODUCTION

Undescended testis (UDT) is known to be the most common urogenital disorder diagnosed at birth. Its prevalence increases in prematurity. The management of UDT is well documented and guidelines exist as per the American Urological Association and European Association of Urology. Current recommendation is for surgical exploration and orchidopexy to be

performed beginning from 6 months of age to 12–18 months [1]. However, this condition could persist into adulthood especially in developing countries owing to the condition alluding diagnosis in childhood [2]. Long term complication of this condition is also well reported in literature, which are reduced fertility and possibility of malignant change in the undescended testis [2]. However more acute complication such as torsion in the undescended

\*Corresponding author: E-mail: [adambinamir@hotmail.com](mailto:adambinamir@hotmail.com);

testis is still a rare entity, posing diagnostic and subsequently management challenges, resulting in delayed diagnosis and unviable testis at exploration. We report a case of a torsion of an undescended testis in the inguinal canal in a 13-year-old boy in Hospital Sultan Ismail, Johor Bahru Malaysia.

## 2. CASE SUMMARY

Patient is a healthy 13-year-old boy, presented to our hospital with an enlarging painful swelling over his right groin for past three days. His symptoms were associated with lower abdominal discomfort and nausea. Upon further detailed history, it was found that patient had a right undescended testis since birth however no surgical consult was made throughout childhood. Clinical examination revealed a tender firm mass over the right mid-inguinal region measuring 4x3cm with slight erythema over the overlying skin. His right scrotum was empty and under-developed. Left testis was palpable. Secondary sexual characteristics was also seen.

Ultrasound Doppler study revealed a small testis to be in the right inguinal canal with no color doppler detected and congested cord structures. The left testis was in the scrotal sac with normal architecture and color flow. We came to a diagnosis of possible torsion of right undescended testis and scheduled him for an urgent inguinal exploration. Parents were informed on the possible risk of orchidectomy as well.

Right inguinal exploration was made which revealed a gangrenous right testis. Its cord was heavily congested and appeared dusky, twisted towards the midline a total of 5 times (1800 degrees). There was no associated hernia. Complete detorsion of the cord was done and warm pack was applied to the cord and testis for 5 minutes after which cord appeared pink however the testis was still clinically unviable. Hence, decision made for right orchidectomy and orchidopexy on the contralateral side. Patient made full recovery and was discharged home the next day.

## 3. DISCUSSION

UDT is common in full term male babies about 2-8% and can increase to about 65% in premature male infants [1]. Early treatment is advocated within 18 months of age for a better outcome [1]. Despite this, its diagnosis could still be missed especially in developing countries thus condition may persist into adulthood [2]. The possible

complications of UDT are well documented in available literature and testicular torsion is one of it. Studies have shown that UDT is associated with an increased risk of testicular torsion and the risk is higher with delayed diagnosis [3].

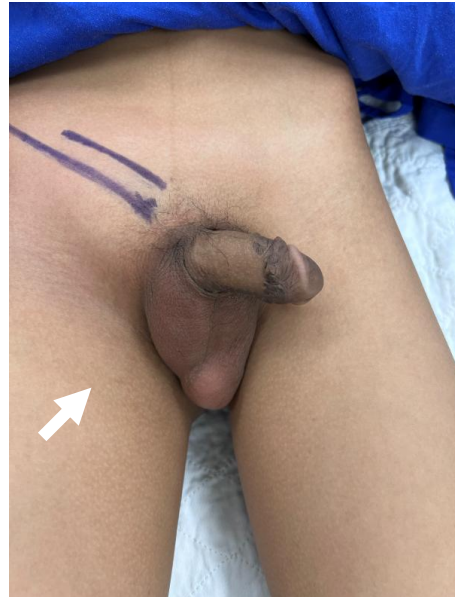

Fig. 1. Empty scrotal sac on the right. Vague tender mass on the right inguinal region

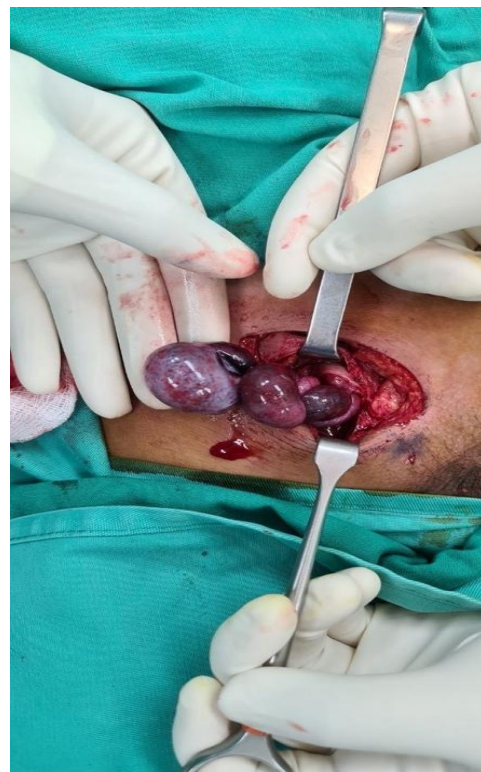
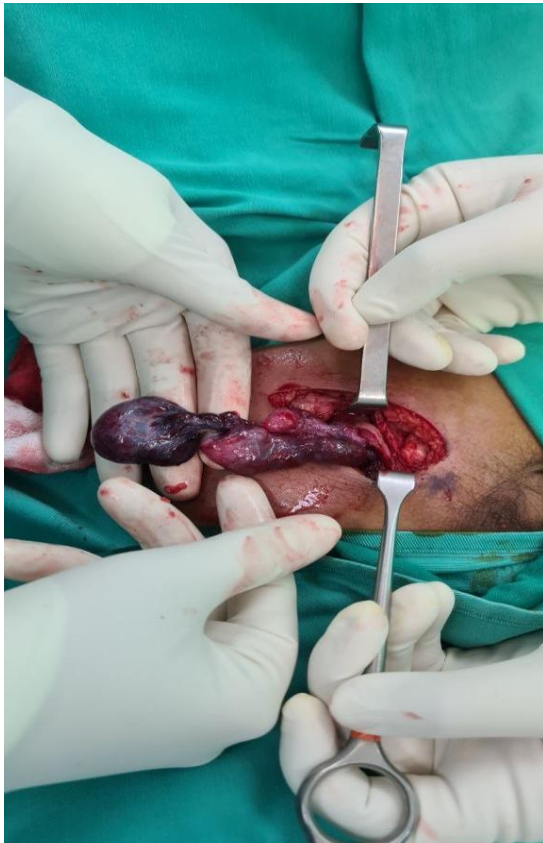

Fig. 2. Upon entering inguinal canal, gangrenous right testis, twisted and congested cord



**Fig. 3. After detorsion of the cord done, right testes non-viable hence done right orchidectomy**

Testicular torsion is a surgical emergency and its incidence peaks about 12-16 years of age which corresponds to our patients age group [3]. Torsion of UDT remains a rare clinical entity thus poses difficulty for the treating physician [3]. The problem is further compounded by atypical presentation and misdiagnosis. The lack of awareness for this condition amongst patients, parents and medical practitioners may further contribute to late presentation to hospital and poor salvage rate [4,5]. As in the case discussed above, patient presented after 3 days of pain, which is far from golden time of 12 hours which translates to a poorer outcome.

The reason behind the torsion of UDT has been thought to be because of the cremasteric muscle spasms that causes the spermatic cord torsion [6]. Another theory proposed is that the torsion of the UDT happens when there is an association with testicular tumor given the enlarged size of the testis [6].

Torsion of UDT can often mimic certain diagnosis like strangulated inguinal hernia, inguinal

abscess, lymphadenitis and even epididymitis. In rarer cases of torsion of testis within the abdominal cavity, patients may even present with signs of an acute abdomen [4,5]. These differentials act as red herrings to the true underlying pathology. Therefore, a good history and physical examination will raise the suspicion of this diagnosis.

Treating physicians who encounter male patients with suggestive symptoms and a concurrent empty scrotal sac should be highly suspicious of this condition as it is a surgical emergency. An ultrasound color Doppler should be done to further strengthen the diagnosis of torsion and ruled out the other possible causes as well. In our patient, the right UDT was in the inguinal canal with no color Doppler seen which complement the clinical diagnosis of torsion and also possibility of a non-viable testis.

Based on the literatures, salvation rate for torsion of a descended testis is about 56 to 90% and these numbers drop significantly with UDT to 10% [7]. This is mainly due to the delay in surgical treatment. Ischemic damage to the testis sets in after 4 hours, and gangrenous testis is associated with more than 360-degree torsion or 24 hours delayed presentation [7]. This was clearly illustrated in our patient. Surgical treatment is still inguinal exploration and either orchidectomy or orchidopexy depending on the testis viability. In addition, the prophylactic contralateral testis fixation is recommended by majority of the studies [4].

Tao Deng reported in a case series involving 6 patients in the pediatrics age group with ages ranging from 12 days to 11 years, with mean ischemic time of 20.5 hours, whereby 3 of the patients managed to successfully undergo orchidopexy, salvaging the testis [8]. This further points to the importance of early presentation and diagnosis with prompt surgical management. In another case series, Zhong reported that the salvage rates of testis were higher in post pubertal group of patients compared to prepubertal group [9]. This was mainly due to atypical presentation and misdiagnosis in the prepubertal group masking the true diagnosis leading to delayed surgical treatment.

Similarly, Nevzat reported in another case series the approach to torsion of UDT and the subsequent management involving 13 patients with ages ranging from 8-70 months. His approach was similar whereby patients

underwent thorough physical examination and a confirmatory ultrasound doppler. Due to the shorter mean ischemic time in their group of patients, nine patients (69.2%) were able to undergo single stage orchidopexy [10]. Thus, earlier diagnosis is no doubt associated with higher testis salvage rates

#### 4. CONCLUSION

Torsion of an undescended testis remains a rare entity however clinicians should have high level of suspicion as these patients require urgent surgical intervention. Delay in diagnosis can potentially lead to low testis salvation rate.

#### CONSENT

As per international standard or university standard, patients' written consent has been collected and preserved by the author(s).

#### ETHICAL APPROVAL

As per international standard or university standard written ethical approval has been collected and preserved by the author(s).

#### COMPETING INTERESTS

Author has declared that no competing interests exist.

#### REFERENCES

1. Niedzielski JK, Oszukowska et al. Undescended testis - current trends and guidelines: A review of the literature. Archives of medical science: AMS. 2016; 12(3):667–77
2. Viljoen JT, Zarrabi et al. A. Management of cryptorchidism in adolescent and adult males. Afr J Urol. 2020;26:40.
3. Ali RAH, Ferry S. Testicular torsion in unilateral undescended testis: A case report and literature review. Urology Case Reports. 2021;39.
4. Naouar S, Braiek S, El K et al. Testicular torsion in undescended testis: A persistent challenge. Asian Journal of Urology. 2017; 4(2):111–5.
5. Kargl S, Haid B. Torsion of an undescended testis - A surgical pediatric emergency. J Pediatr Surg. 2020;55(4): 660-4.
6. Jiun HG, Chun NH. Torsion of undescended testis: Clinical, imaging, and surgical findings. Urological Science. 2014; 25(1):31-4.
7. Ossama J, et al. Cryptorchid testicular torsion: A case report. PAMJ- Clinical Medicine. 2021;6:41.
8. Deng T, Zhang X, Wang G, Duan S, Fu M, Zhong J, Li J, Jiang X. Children with Cryptorchidism Complicated by Testicular Torsion: A Case Series. Urol Int. 2019; 102(1):113-117.
9. Zhong HJ, Tang LF, Bi YL. Cryptorchid testicular torsion in children: characteristics and treatment outcomes. Asian J Androl. 2021;23(5):468-471.
10. Nevzat Can Şener, Okan Bas, Nihat Karakoyunlu, Hakan Ercil, Suleyman Yesil, Kursad Zengin, Abdurrahim Imamoglu. A Rare Emergency: Testicular Torsion in the Inguinal Canal. BioMed Research International. 2015;3. Article ID 320780

© 2022 Amir; This is an Open Access article distributed under the terms of the Creative Commons Attribution License (<http://creativecommons.org/licenses/by/4.0>), which permits unrestricted use, distribution, and reproduction in any medium, provided the original work is properly cited.

Peer-review history:

The peer review history for this paper can be accessed here:  
<https://www.sdiarticle5.com/review-history/85332>