



Novel Technique in Late Stage Avascular Necrosis of Lunate: Tendon Interposition and Ligament Reconstruction with ECRL Tendon– A Case Report

Sarvang Desai ^a, Apurva Patel ^{a*} and Malkesh Shah ^{a†}

^a Department of Orthopaedic, SBKS MI&RC, India.

Authors' contributions

This work was carried out in collaboration among all authors. All authors read and approved the final manuscript.

Article Information

DOI: 10.9734/JPRI/2022/v34i39B36241

Open Peer Review History:

This journal follows the Advanced Open Peer Review policy. Identity of the Reviewers, Editor(s) and additional Reviewers, peer review comments, different versions of the manuscript, comments of the editors, etc are available here: <https://www.sdiarticle5.com/review-history/87407>

Case Report

Received 15 March 2022

Accepted 25 May 2022

Published 31 May 2022

ABSTRACT

Aim: To evaluate clinical and functional results of extensor carpi radialis longus tendon ball interposition for treatment of late stage avascular necrosis of lunate (kienbock's disease).

Materials and Methods: Patient with stage 4 kienbock's disease was treated with excision of lunate and ecrl tendon interposition to fill the cavity of the excised lunate bone. Tendon was split. One half was left in situ and the other was used to fill the cavity by passing it to the scaphoid and triquetrum. This also helps to maintain intercarpal stability. Functions were assessed using grip strength, range of movement of wrist, quick dash and visual analogue score. Radiological examination was performed to assess carpal height ratio and progression of arthritis.

Results: Long and bulky ecrl tendon acts as a spacer to fill the excised lunate. it also provides scapho lunate and lunate triquetral ligament reconstruction for inter carpal stability.

Conclusion: ECRL tendon used for interposition with reconstruction seems to be an effective treatment modality for late stage of kienbock's disease.

Keywords: ECRL tendon; arthritis; visual analogue score; kienbock's disease.

^a Professor and Head of Department,

[#] Junior Resident,

[†] Associate Professor,

*Corresponding author: E-mail: drapurvapatel110@gmail.com;

1. INTRODUCTION

Keinbock's disease is a painful idiopathic disorder of the wrist resulting from vascular compromise to carpal lunate bone. The disease usually results in avascular necrosis and later on fragmentation of the lunate, collapse with shortening of the carpus and arthritic changes in proximal carpal area.

“Keinbock's disease is commonly seen between 20-40 years age group with female predominance (F:M::2:1). The diagnosis is made from characteristic change seen in lunate on radiograms of the wrist and the severity of the disease can be categorised by staging the degree of involvement (Stahl staging)” [1-4]. In early stage of Keinbock's disease treatment is conservative and includes immobilization, analgesics, and/or anti-inflammatory medication. If symptoms are not relieved then based on degree of involvement, several surgical options exist like, revascularisation, radial shortening, ulnar lengthening, intercarpal arthrodesis, autogenous tendon replacement arthroplasty and silicone replacement arthroplasty [5-7].

Here we describe novel technique of lunate excision with autogenous ECRL tendon ball interposition with stabilization with same mimicking ligament.

2. PRESENTATION OF CASE

A 28 year old female patient who presented with pain in her left wrist joint (dominant hand) since 8 months which was constant in nature, dull aching, non radiating and aggravated with movements like holding a bowl, combing hair and swiping floor. Patient had no history of trauma, fever, weight loss and loss of appetite. On examination – tenderness was present on watershed line of wrist joint.

On further examination, Range of movements in degree were as follow-

Palmar flexion was 0-50 degree, Dorsiflexion was 0-40 degree, Ulnar deviation was 0-35 degree and Radial deviation was 0-10 degree.

Terminal palmar and dorsiflexion were painful. On admission VAS score was 9.

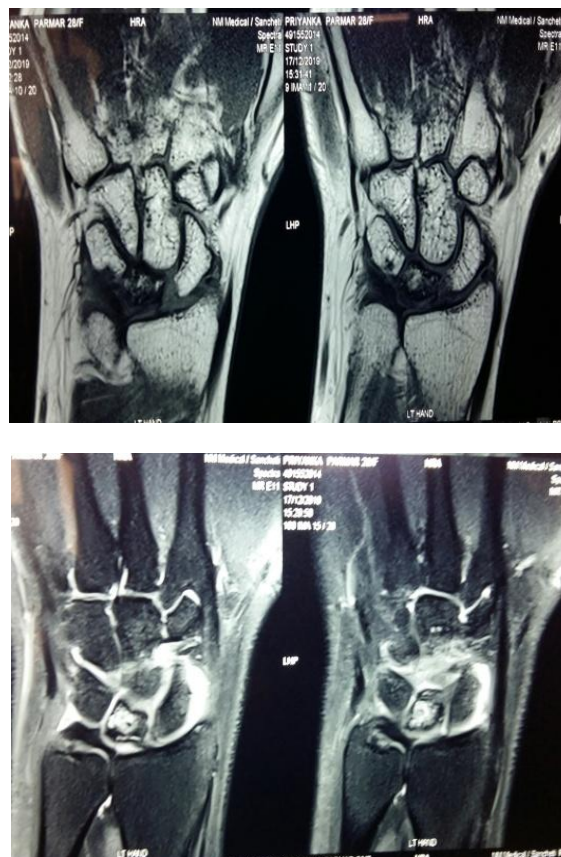

Image 1. X-ray image

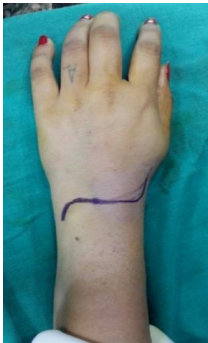3. TECHNIQUE

After taking consent from patient, patient was taken to Operation theatre. Regional anaesthesia was given for left upper limb. Left upper limb was put on side arm support. Sterile painting and draping was done. Transverse incision made over dorsal aspect of wrist joint.

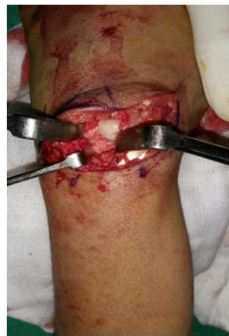- After superficial and deep dissection, wrist joint capsule opened in U-shaped and lunate was excised in piece meal.
- Extensor Carpi Radialis Longus tendon was identified in middle 1/3rd of forearm

which was cut at musculotendinous junction and the tendon was harvested.

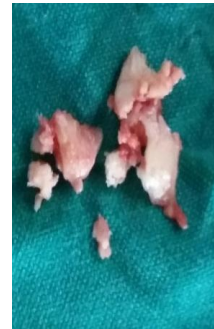
- After that tendon was split into two parts and the tendon strip was obtained.
- Then two holes of 2.7mm were drilled to the triquetrum and to the proximal scaphoid and the tendon strip obtained from ECRL tendon was passed through these holes.
- The coiled tendon was inserted into the cavity of excised lunate, and the tendon strip was sutured onto itself over the coiled tendon with prolene material.
- The remaining half of tendon was reinserted back to its original position.



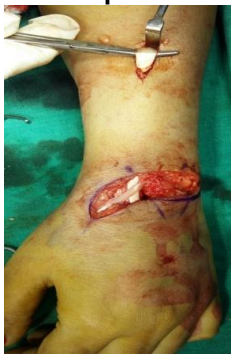Picture 1. Incision over dorsal aspect



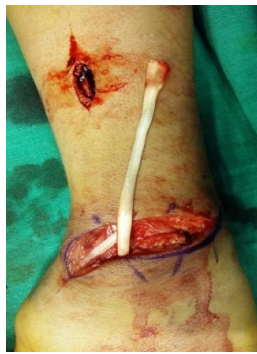Picture 2. Superficial and deep dissection



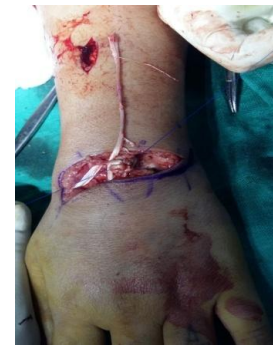Picture 3. Excised Lunate



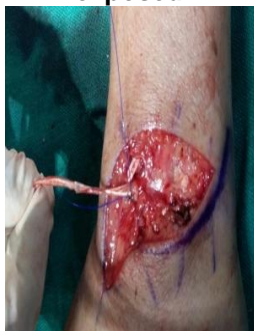Picture 4. ECRL Tendon exposed



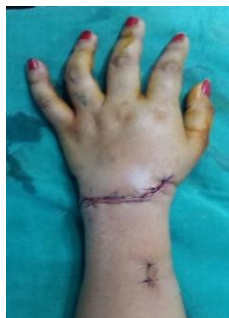Picture 5. Harvested ECRL Tendon



Picture 6. Tendon ball interposition



Picture 7. Tendon fixation



Picture 8. Closure

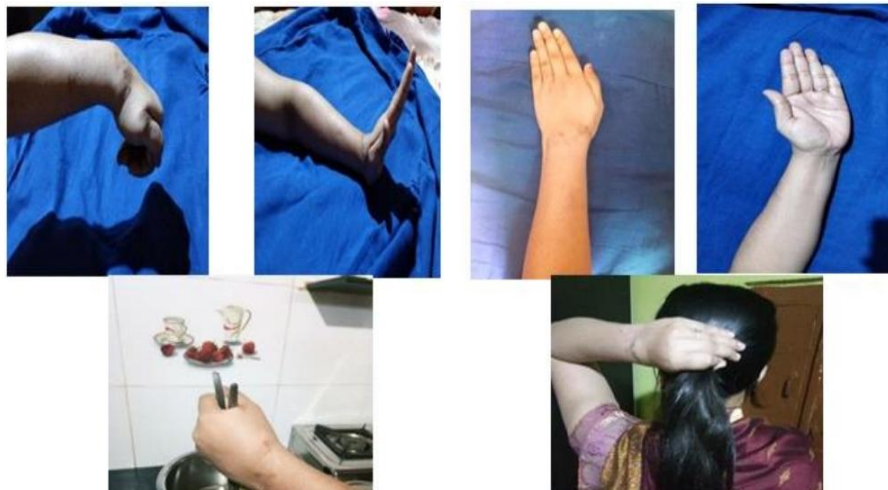

Fig. 1. Range of movements recovery

4. FOLLOW-UP

Immediate post-op X-ray:

Immediate post operatively below elbow cast was given and suture removal was done after 1.5 months. Patients clinical function was assessed using grip strength, ROM of wrist and VAS score (visual analogue scale). On 12 months follow up - range of movements with functional activities pain free and VAS score improved from 9 to 1.

5. DISCUSSION

Kienbock's disease stages 3B and 4 can be definitively treated with a surgical approach that relieves pain while preserving as much normal wrist function as possible. The ideal approach for treating Kienbock's disease would keep as much of the wrist's biomechanics as possible. The area created following lunate excision has been filled with tendon, fascia, and other materials such as steel, ivory, silicon, and pyrocarbon to retain grip strength, enhanced range of motions, and prevent carpal collapse. In this work, lunate was removed to relieve pain and autogenous material – ECRL tendon – was used to fill the area for treatment in the late stages of the disease. To restrict scaphoid rotation and preserve proximal row integrity, a strip of the same tendon was inserted through the scaphoid and the triquetrum to operate as a ligament. The ECRL tendon is favored because it is longer and thicker than the Palmaris longus tendon, preventing additional carpal collapse. Because of its centralizing impact on the wrist, the Extensor Carpi Radialis Tendon, which is located in the same anatomic

region and has similar morphological qualities, was not used. After sacrificing the ECRL tendon, thumb function increased, while wrist motion and strength were unaffected. Furthermore, the use of autogenous material minimizes the chronic discomfort that might occur with silicon implant reconstruction.

6. CONCLUSION

Use of ECRL tendon interposition for the excised space has minimum chances of carpal bone collapse and provides better wrist stability as compared to silicon prosthesis which has more chance of collapse and scaphoid rotation. This technique is cost effective as compared to other techniques.

7. LIMITATION

In order to study the complications of arthritic changes, proximal row carpal bone collapse, recurrence in symptoms found in Kienbock's disease, we need a larger sample number with frequent follow up visits.

ETHICAL APPROVAL

All experiments have been examined and approved by the appropriate ethics committee and have therefore been performed in accordance with the ethical standards laid down in the 1964 Declaration of Helsinki.

CONSENT

It is not applicable.

COMPETING INTERESTS

Authors have declared that no competing interests exist.

REFERENCES

1. Karalezli N, et al. Tendon Interposition and Ligament Reconstruction with ECRL Tendon in the Late Stages of Kienböck's Disease: A Cadaver Study. Hindawi Publishing Corporation the Scientific World Journal Volume. 2013; Article ID 416246, 5 Available:<http://dx.doi.org/10.1155/2013/416246>.
2. Minami A, Kimura T, Suzuki K. Long-term results of Kienbock's disease treated by triscaphe arthrodesis and excisional arthroplasty with a coiled palmaris longus tendon. Journal of Hand Surgery. 1994;19(2):219–228.
3. Carroll RE. Long term review of fascial replacement after excision of the carpal
4. Kato H, Usui M, Minami A. Long-term results of Kienbock's disease treated by excisional arthroplasty with a silicone implant or coiled palmaris longus tendon. Journal of Hand Surgery. 1986;11(5):645–653.
5. Watson KH, Ryu J, Dibella A. An approach to kienbock's disease: Triscaphe arthrodesis. Journal of hand surgery. 1985;10(2):179-187.
6. King PJ, Eglseider Jr WA, House HO. Extensor Carpi Radialis Longus tendinoplasty for thumb basal joint arthritis. American Journal of Orthopaedics. 2001; 30(3):213-219.
7. Alexander AH, Turner AM, Alexander CE, Lichtman DM. Lunate silicone replacement arthroplasty in Kienbock's disease: a long term follow up. The Journal of Hand Surgery. 1990;15:401-407.

© 2022 Desai et al.; This is an Open Access article distributed under the terms of the Creative Commons Attribution License (<http://creativecommons.org/licenses/by/4.0>), which permits unrestricted use, distribution, and reproduction in any medium, provided the original work is properly cited.

Peer-review history:

The peer review history for this paper can be accessed here:
<https://www.sdiarticle5.com/review-history/87407>